

DOI: 10.4274/tpa.1193

Lightning-related death

Celal Bütün, Fatma Yücel Beyaztaş, Rıza Yılmaz*

*Cumhuriyet University Medical Faculty, Department of Forensic Medicine, Sivas, Turkey***Zonguldak Karaelmas University Medical Faculty, Department of Forensic Medicine, Zonguldak, Turkey*

Summary

Lightning is one of the reasons for death due to environmental disasters. Lightning-related deaths occur rarely in Sivas. This study aimed to make the medico-legal evaluation of rare specific findings which can be observed on clothings and during autopsy in a small part of the subjects who have died due to stroke of lightning. A five year-old boy who resided in his father's farm was exposed to lightning on an open field. Resuscitation failed and he was reported to be dead when he arrived at the hospital. Postmortem investigation revealed extensive burnt areas on his clothes and body. In suspicious deaths occurring on open fields, lightning should be taken into consideration as a possible cause of death. Detailed external and internal examination should be carried out along with careful crime scene investigation. It is important to determine and evaluate the characteristic findings of lightning. Carcasses of animals and damages in the trunks of trees found in the surrounding area should not be overlooked, since they may give some clues to establish a link between lightning and death. (*Turk Arch Ped 2012; 47: 63-6*)

Key words: Autopsy, crime scene investigation, forensic medicine, lightning, death,

Introduction

Lightning is discharge of electrical potential formed in the atmosphere between the clouds and the earth. It follows a zig-zag way and goes downward in branches (1,2). Streak of lightning is static electricity on a very large scale (3). The human being is a good conductor just like wires, metals, humid soil and tree roots. Lightning has electrodynamic, barometric, auditory, electrochemical, optical ve thermic effects (4). Lightning strikes especially occur during heavy rain in the afternoon in the autumn and summer (5,6).

20-30% of individuals who are struck by lightning die and various sequelae including peripheral neuropathy and cognitive dysfunction occur in survivors (4-6). In cases of death as a result of lightning, no finding on clothes and bodies may be observed or burns and breakup in the clothes may be observed and entry and exit lesions and a sign of fern which is specific for strike of lightning may be observed on the body. In autopsies of cases of death which occur as a result of lightning, findings in the internal organs are not diagnostic alone. Hyperemia, edema, fluid accumulation and bleedings are reported in internal organs (4-8). Therefore, examination of the clothes and crime scene

investigation are very valuable in the diagnosis in cases of deaths which occur as a result of strike of lightning (4).

In this study, it was aimed to evaluate the rare specific findings which can be observed on clothings and during autopsy in a small part of the subjects who have died due to lightning strikes. This case was presented to help to make a diagnosis earlier and start therapeutical procedures as early as possible in cases who are referred as casualties after lightning strike to clinics where pediatricians work.

Case

A five-year-old boy who lived in a farm in Sivas was exposed to lightning while walking with his father on the cropland which was an open field. The father resuscitated his son, but it was found that the boy was dead, when he was brought to the hospital. It was decided to perform an autopsy to find out the reason of death.

On crime scene investigation, a pair of naylor shoes with torn soles were found (Picture 1). In addition, the crime scene was observed to be wet because of heavy rain. When the clothes of the boy were examined, it was observed that his grey sweatshirt,

Address for Correspondence: Rıza Yılmaz MD, Zonguldak Karaelmas University Medical Faculty, Department of Forensic Medicine, Zonguldak, Turkey

E-mail: dr_riza_yilmaz@yahoo.com **Received:** 03.08.2010 **Accepted:** 01.20.2011

Turkish Archives of Pediatrics, published by Galenos Publishing

dark blue t-shirt, dark blue short-sleeved vest and cream-colored pants were ripped.

The external examination during the autopsy revealed the following findings: Lacerated areas of 0.3-0.5 cm on the dorsum of the right hand and on the base of the thumb were observed on a 5-6 year-old uncircumcised male cadaver with a height of 100 cm and weight of 22-25 kg. A hairy part of 10x5 cm was found to be burnt till the skin in the frontoparietal region and the whole hairy region around this (Picture 2) and both eyebrows were found to be burnt-fumigated. The region extending from the anterior part of the left ear to the left side of the neck and the left part of the chest, a region of 7x2 cm extending from the posterior part of the neck to the interscapular area, a region of 6x3 cm under the right scapula with lacerations on the skin, a region of 36 x 12 cm which covers the left half of the chest and the abdomen nearly fully, two regions of 6 x 6 cm in the left and 9x4 cm in the right in both inferior quadrants of the abdomen with lacerations on the skin, a region of 2x1.5 cm on the internal malleolus of the left leg, a region of 0.75 x 1 cm in the internal side of the left heel and a region with a diameter of 1 cm with raised edges in the right heel were observed to be burnt. In addition, a picture of fern (tree branches) was observed in the abdominal region (Picture 3-5).

The internal examination: When the cranium was opened, purpuric bleedings under the scalp, a haemorrhagic region of 3 cm in the vertex, areas compatible with diffuse subdural hematoma and subarachnoid bleeding in the left parietal region (Picture 6) and subarachnoid bleedings in the anterior parts of both temporal lobes were found. Haemorrhagic areas in the thalamus and a haemorrhagic region with a diameter of 0.5 cm in the brain stem were observed on sections of the brain. When the chest and abdomen were opened, diffuse hemorrhagic areas were observed in both lungs. On sections of the lung, hemorrhagic areas were found in the medial half of the lower lobe of the left lung (Picture 7) and in the middle and lower lobe of the right lung. No other pathological finding was found in the other organs except for appearance of fluid accumulation.

No toxic, sedative or narcotic substance was found in the tissue samples obtained during the autopsy and in the chemical examination of the blood. On histopathological examination, cutaneous changes compatible with electrical flow and heat affect (lengthening in the basal layer in spinal cells in the epidermis, fusiform shape, focal subepidermal separation, diffuse homogenization in the collagenous fibers in the dermis) and hyperemia in the lung and brain were found.

The reason of death was reported to be respiratory and cardiac arrest as a result of burn related to lightning strike and injury of internal organs.

Discussion

Lightning strikes are usually observed especially in the autumn and in the summer during the rain in the afternoon

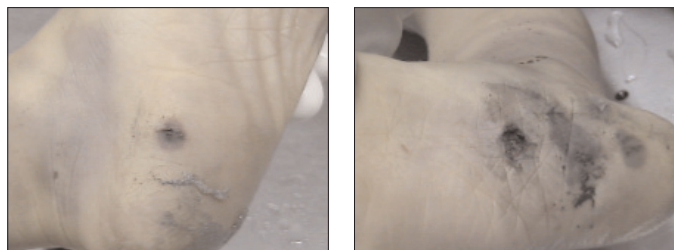
(7,8). To declare that a person has died as a result of lightning strike a detailed crime scene investigation should be made in addition to external and internal examination of the cadaver. The weather conditions in the place and the time of the event and clues about the effects of lightning in the surroundings (parts of clothes scattered around the place, damage in houses and trees, mass animal deaths in sheep and lamb herds)



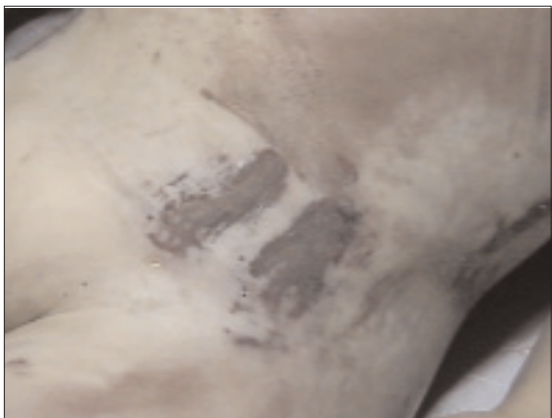Picture 1. Appearance of tears in the soles of the shoes



Picture 2. Burns in the scalp hair and burnt areas in the scalp



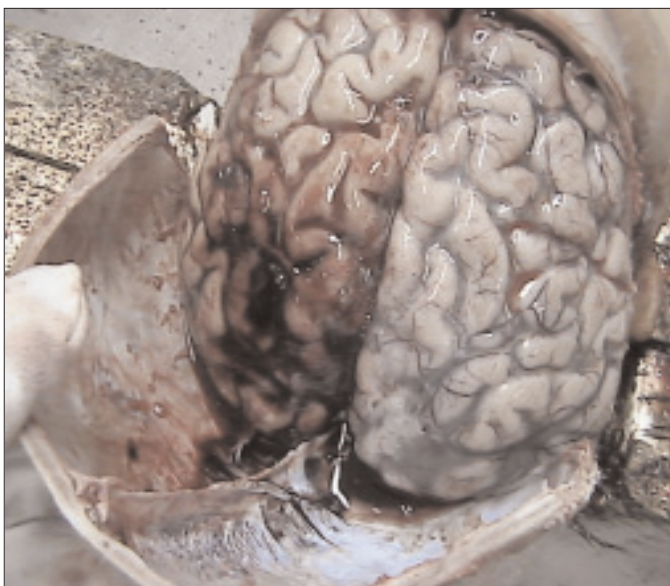Picture 3. Exit injuries related to lightning strike in both soles



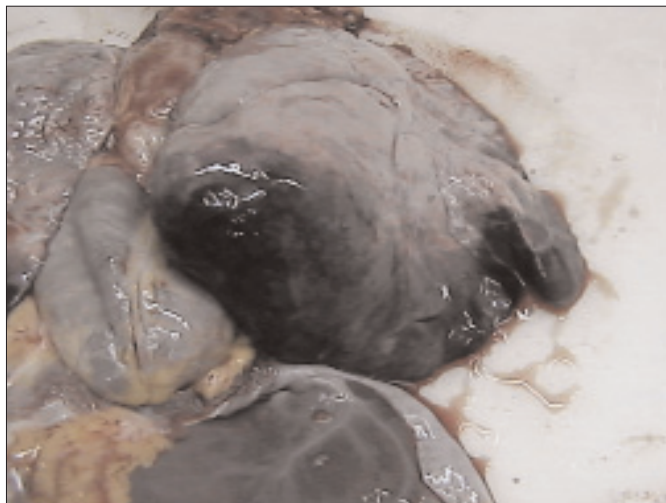Picture 4. Skin burns in the left lower quadrant of the abdomen compatible with the metal-containing part of clothes.



Picture 5. Fern-like appearance on the abdomen



Picture 6. Subarachnoid hemorrhage areas in the brain which were visualized macroscopically during the autopsy.



Picture 7. Hemorrhage areas in the lung which were visualized macroscopically during the autopsy.

should be investigated (2). Clothes may be ripped, torn or unstitched (9,10). The fact that all clothes and the shoes of this subject were ripped and lightning was observed in October on a rainy and closed weather was found to be compatible with the information in the literature.

While no finding may occur as a result of lightning strike, large burns, fumigation in the hair and multiple organ injuries related to passing of electrical flow through the body may be observed (9). In deaths due to lightning strikes, the scars on the skin left by lightning are valuable in diagnosing the reason of death. These are branched, fern-like lesions which are also called "Lichtenberg figures". They may be observed as burns and roasted appearance in places where lightning had passed, in the hair and in the body hair (2,4).

In our case, burns in the scalp hair, roasted chest and pubic hair (Picture 2), fern-like appearance in the face, neck, chest and abdomen (Picture 5), burns in the interscapular region, burns in the lower extremities and electrical current exit points in the heels (Picture 3) suggest the possibility of lightning strike.

There may be burns in the body which occur in different ways. Burns in the scalp and in the body hair occur as roasting, flaring up or ironing. There may also be thermal burns as a result of extremely heated metals on the body or blazing of the clothes on the body (2,4). In our case, burn was observed in the left inguinal region which was in contact with the part of the clothes containing extremely heated metal (Picture 4).

In the central nervous system, brain edema, intracranial hemorrhage and thermal lesions in the brain and spinal cord may occur. Scattered regional petechial hemorrhages, tears in the large vessels, edema, softening, liquifying, chromatolysis in pyramidal cells, shrinkage in damaged cells and uniformly stained eccentric nuclei may be observed in the brain (1,2). Rupture and tears may be found in the vessels and internal organs. Fluid accumulation and petechial hemorrhages may be observed in internal organs (11). In our case, diffuse intracranial

hemorrhages and diffuse hemorrhage areas and fluid accumulation in the lung were observed.

In addition, perforation of tympanic membrane, corneal edema and tears, retinal detachment and fetal loss due to uterine rupture may be observed (1,5,6,12-14).

Although national education programs are performed to prevent lightning strike, the most efficient way of preventing lightning strikes is the applications performed directly in regions where lightning stike cases are seen (15).

Conclusively, in suspicious deaths occuring in open fiels, crime scene investigation should be performed carefully in order to declare that a subject had died as a result of lightning strike. It should be learned if there was thunder and storm in the place of the event. In addition, proofs related to the effects of lightning including scattered parts of clothes in the surroundings, damage in houses and trees and mass animal deaths should be investigated. Afterwards, a detailed external examination of the cadaver, systematic autopsy and toxicology tests and histopathologic studies of the samples obtained from the person would be a suitable approach to determine the reason of death (1,4,16,17).

References

- Gök Ş, Soysal Z. El akımlarının canlı organizmada meydana getirdiği lezyonlar ve bu lezyonların adli tıp açısından değerlendirilmesi. İstanbul: İ.Ü. Tıp Fakültesi Yayınları, 1983: 139-47.
- Demirel B, Yağan M, Balseven A, ve ark. Yıldırım çarpması ile ölüm: bir olgu sunumu. Gazi Tıp Dergisi 2007; 18(2): 92-4.
- Doğan KH, Demirci Ş, Günaydın G. Yıldırım çarpmasına bağlı ölümler: üç olgu sunumu. Genel Tıp Derg 2007; 17(4): 217-2.
- Yılmaz R, Bulut E, Özer E, ve ark. Yıldırım çarpmasına bağlı ölümlerin değerlendirilmesi. Adli Tıp Bülteni 2007; 12(3): 112-7.
- Lewis AM. Understanding the principles of lightning injuries. J Emerg Nurs 1997; 23: 535-41.
- Whitcomb D, Martinez JA, Daberkow D. Lightning injuries. South Med J 2002; 95: 1331-4.
- Duclos PJ, Sanderson LM, Klontz KC. Lightning related mortality and morbidity in Florida. Public Health Rep 1990; 105(3): 276-82.
- Meel BL. Lightning fatalities in the Transkei sub-region of South Africa. Med Sci Law 2007; 47(2): 161-4.
- Knight B. Forensic Pathology. Second edition. London: Edward Arnold, 1996: 330-1.
- Aslar AK, Soran A, Yıldız Y, Isik Y. Epidemiology, morbidity, mortality and treatment of lightning injuries in a Turkish burns units. Int J Clin Pract 2001; 55: 502-4.
- Gül M, Girişgin AS, Koçak S, ve ark. Yıldırım çarpması yaralanmaları. Genel Tıp Derg 2004; 14(1): 35-8.
- Blumenthal R. Lightning fatalities on the South African highveld: A retrospective descriptive study for the period 1997 to 2000. Am J Forensic Med Pathol 2005; 26(1): 66-9.
- Cankaya H, Egel E, Evliyaoglu Z. Hearing loss caused by lightning strike: case report and review of the literature. J Otolaryngol 2002; 31(3): 181-3.
- Sommer LK, Lund-Andersen H. Skin burn, bilateral iridocyclitis and amnesia following a lightning injury. Acta Ophthalmol Scand 2004; 82(5): 596-8.
- Adekoya N, Nolte KB. Struck-by-lightning deaths in the United States. J Environ Health 2005; 67(9): 45-50, 58.
- Okudan M, Kirangil B, Fincancı ŞK, Soysal Z. Yıldırım çarpması ile ölüm: bir olgu bildirisi. 7.Ulusal Adli Tıp Günleri, 1-5 Kasım 1993, Antalya. Poster Sunuları Kitabı, 1993: 391-8.
- Demirel B, Yağan M, Balseven A, ve ark. Yıldırım çarpması ile ölüm: bir olgu sunumu. 12. Ulusal Adli Tıp Günleri. 28 Eylül-2 Ekim 2005, Antalya. Paneller ve Poster Sunuları Kitabı, 2005: 227-30.