

DOI: 10.4274/tpa.83

A rare form of tuberculosis: isolated psoas abscess

Mustafa Özçetin, Resul Yılmaz, Erhan Karaaslan, Ülkü Bekar*, Yasemin Yerli, Doğan Köseoğlu**

Gaziosmanpaşa University Medical Faculty Department of Pediatrics, Tokat, Turkey

**Gaziosmanpaşa University Medical Faculty Department of Radiology, Tokat Turkey*

***Gaziosmanpaşa University Medical Faculty Department of Pathology, Tokat, Turkey*

Summary

Tuberculosis as an important health problem of our age causing death of 2 million people each year. The incidence of tuberculosis in the pediatric age group is 1.3 millions/year and it is estimated that 450,000 cases result in death. WHO reports that %15-25 of cases are extrapulmonary tuberculosis patients. Here we present a rare case of abdominal tuberculosis who had no immunosuppression with isolated bilateral psoas abscesses and inguinal lymph node involvement. (*Turk Arch Ped 2011; 46: 331-3*)

Key words: Child, psoas abscess, tuberculosis

Introduction

Tuberculosis still continues to be a significant public health problem at the present time. The World Health Organization reports that 8 million new active tuberculosis cases occur each year in the world and 2 million people die because of this disease each year (1). After the years during which a decrease in the prevalence of tuberculosis was observed in the mids of 1980s and in the early 1990s, the percentage of reported cases have increased by 15%. Children have been affected with a higher rate from this tendency to increased prevalence. Almost 40% of the reported cases have been composed of children between the ages of 5 and 14 years (2). The World Health Organization reports that 15-25% of the cases are extrapulmonary tuberculosis patients. Although involvement intensifies in lymph nodes, pleura, bone and joints, any organ may be involved. 10% of extrapulmonary tuberculosis is constituted of musculoskeletal involvement (3).

Here we present a rare case of tuberculosis with inguinal lymph node involvement and bilateral psoas abscesses without lung and peritoneal involvement. The patient had no immunosuppression.

Case presentation

A 13 year old girl with complaints of loss of appetite, weight loss and inguinal pain while walking for the last two months

presented with swelling of the right inguinal lymph nodes and a discharging wound in the inguinal region. The patient had no fever and it was informed that she did not improve with the antibiotic treatments given. On physical examination, a lymph node with dimensions of 3x2 cm and a fistulized discharging abscess in the right inguinal region was found in the patient who was measured to be 38.5 kg (3-10p) and 144 cm (<3p). Laboratory findings were as follows: hemoglobin 13 g/dL, white blood cells 5680/mm³, platelets 268000/mm³, CRP 17,3 mg/L, erythrocyte sedimentation rate 24 mm/h. Immunological investigations were as follows: IgG 11.8 g/l, IgM 1.03 g/l, IgA 2.11 g/l. The patient had two scars of BCG and a PPD of 18 mm. Acid-resistant bacillus was found to be negative in fasting gastric fluid obtained three times. Chest graphy was found to be normal. Ultrasonographical examination revealed a formation with a dense content with dimensions of 31x20 mm anterior to the iliac muscle and a fistula extending to deep tissues in the right inguinal region. On lower abdominal magnetic resonance (MR) examination, a fusiform mass lesion with dimensions of 19x12x130 mm extending from the anterior part of the right psoas muscle and ending in the pectineus muscle at the level of the inguinal canal was observed. In the left side, a fusiform mass with dimensions of 49x44x141 mm indwelling in the anterior part of the psoas muscle and ending in the iliopsoas muscle in the left inguinal region was observed (Figure 1,2). Although caseous lesion was not observed in the sample obtained from the right inguinal lymph node by needle biopsy, granuloma structures

Address for Correspondence: Mustafa Özçetin MD, Gaziosmanpaşa University Medical Faculty Department of Pediatrics, Tokat, Turkey

E-mail: mozcetin@gmail.com **Received:** 01.13.2010 **Accepted:** 06.28.2010

Turkish Archives of Pediatrics, published by Galenos Publishing

composed of epithelioid histiocytes which included Langerhans type giant cells and acid-resistant bacillus were found in the sample obtained from the wound region. Thereupon, a diagnosis of tuberculosis was made with radiologic and clinical evaluation and antituberculosis treatment was started. On the follow-up MR performed after three months, it was observed that the abscess formation observed in the left was regressed markedly and the abscess defined in the right psoas muscle and at the level of the inguinal canal was disappeared.

Discussion

Extrapulmonary tuberculosis cases have increased in the last ten years with the increase of individuals with

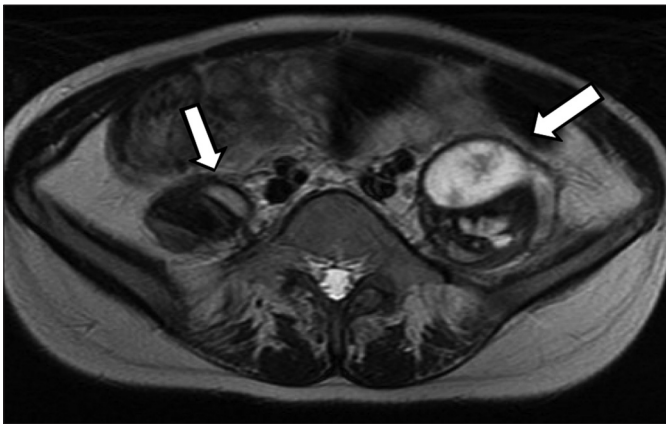
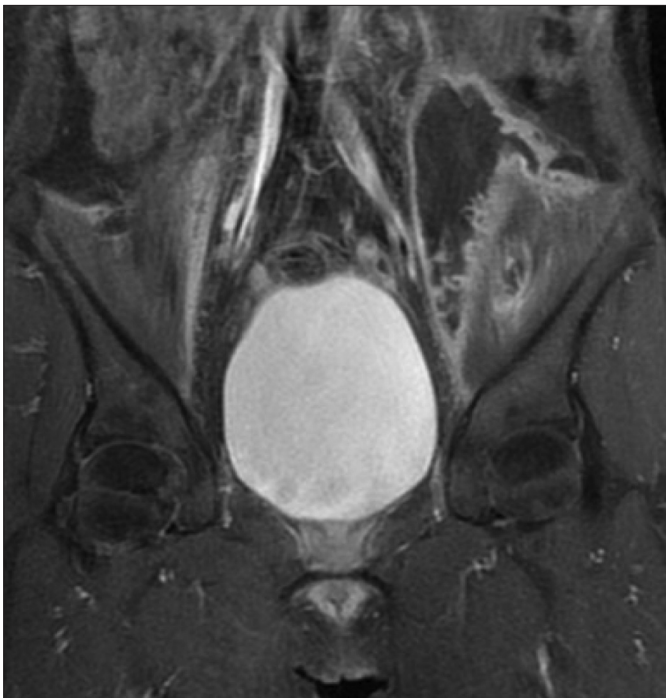
Figure 1. T2A hyperdense lesions localized in the psoas muscles bilaterally (larger in the left).



Picture 2. Fusiform mass lesions localized in the psoas muscles bilaterally extending along the iliac and iliopsoas muscles with peripheral contrast uptake

immunosuppression and emergence of drug-resistant bacteria (4,5). Our patient had no individual or familial history of tuberculosis or immunosuppression.

Rich vascular supply of the psoas muscle which functions as hip flexor leads to hematogenous spread even from closed regions. However, psoas abscess occurs rarely and is diagnosed at a late stage and its diagnosis is difficult. Psoas abscess occurs more commonly in children and young people compared to the elderly (6). Classical signs of psoas abscess include abdominal or lumbar pain, limping and fever (7). Because of close adjacency of the psoas muscle with retroperitoneal organs, digestive system and skeletal system it can be secondarily affected from infectious diseases of these systems (8). In previous years Pott disease was one of the important causes, but it is observed very rarely currently (6,9). In our patient, adjacent organ involvement (especially spinal involvement) was not found. The patient had no

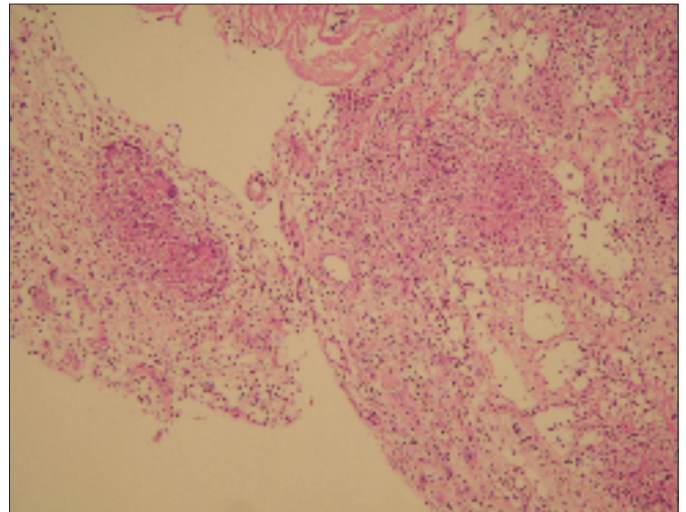


Figure 3. Granuloma structures composed of epithelioid histiocytes (H-E, x200)

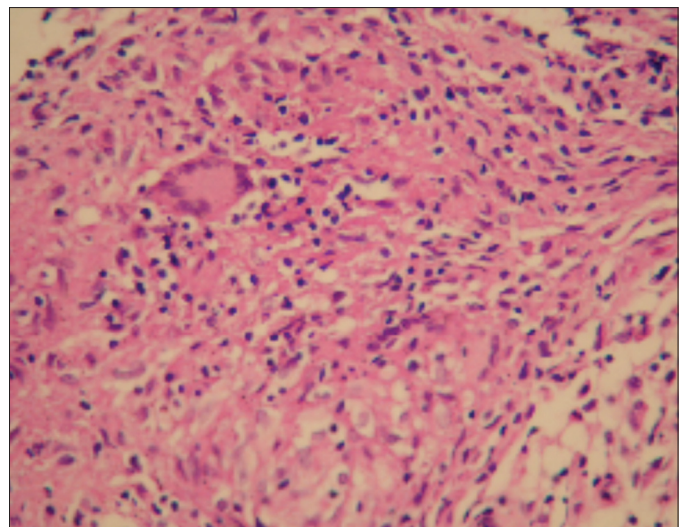


Figure 4. Langerhans type giant cells inside the granuloma structures (H-E, x400)

complaints except for inguinal pain while walking which did not limit her movement.

As in psoas abscess, soft tissue infections may be caused by multiple pathogens. Sepsis may develop in these patients and other organ involvements may accompany to the infection as a complication. No pathogen could be shown in our patient except for acid-resistant bacillus. Although ultrasonography is enough for the diagnosis, computerized tomography is much more sensitive in the diagnosis of abscess (7). In children with low adipose mass, contrast uptake is decreased in soft tissues and this affects accuracy (10,11). Magnetic resonance imaging is the best method, since it defines both anatomical structures and pathological abnormalities well (11,12). MRI performed in our patient revealed more comprehensive information.

In the treatment of psoas abscess related to mycobacterium tuberculosis, drug treatment is essential for the success of the treatment (13). Isoniazid, rifampicin, pyrazinamide and ethambutol were started initially in our patient. In follow-up, radiological findings improved and the treatment was continued with isoniazid and rifampicin.

Consequently, even though tuberculosis is observed rarely in cases with psoas abscess, it should be considered as a causative agent and necessary diagnostic workup should be performed in these cases.

References

1. WHO. Global tuberculosis control: surveillance, planning, financing. Geneva: World Health Organization, 2006: 242.
2. Janner D. A clinical guide to pediatric infectious disease. Pediatric tuberculosis; Philadelphia: Lippincott Williams & Wilkins, 2005: 123-36.
3. Lee SH, Abramson SB. Infections of the musculoskeletal system by M. tuberculosis. In: Rom WN, Garay SM, (eds). Tuberculosis. New York: Little, Brown and Company, 1996; 635-44.
4. Watts HG, Lifso RM. Current concepts review: tuberculosis of bones and joints. J Bone Joint Surg Am 1996; 78: 288-98.
5. Kılıçaslan Z. Dünyada ve Türkiye'de tüberküloz. Ankem Dergisi 2007; 21(Ek 2): 76-80.
6. Gruenwald I, Abrahamson J, Cohen O. Psoas abscess: case report and review of the literature. J Urol 1992; 147: 1624-6.
7. Thomas A, Albert AS, Bhat S, Sunil K. Primary psoas abscess: diagnostic and therapeutic considerations. Br J Urol 1996; 78: 358-60.
8. Ataus S, Alan C, Önder AU, et al. Psoas abscess. Cerrahpaşa J Med 2000; 31: 89-93.
9. Ricci MA, Rose FB, Meyer KK. Pyogenic psoas abscess: worldwide variation in etiology. World J Surg 1986; 10: 834-6.
10. Ralls PW, Boswell W, Henderson R, Rogers W, Boger D, Halls J. CT of inflammatory disease of the psoas muscle. Am J Roentgenol 1980; 131: 767-70.
11. Utkan A, Gülbahçe K, Cılız A, Tümöz MA. Sakroileit bulgularıyla seyreden miliyer tüberküloz: Olgu sunumu. Eklem Hastalık Cerrahisi 2009; 20: 161-4.
12. Lee JK, Gleezer HS. Psoas muscle disorders: MR imaging. Radiology 1986; 160: 683-7.
13. Harrigan R, Kauffman F, Love M. Tuberculous psoas abscess. J Emerg Med 1995; 13: 493-8.