

Lafora disease: a progressive myoclonic epilepsy

Olcay Ünver, Cüyan Demirkesen*, Serap Uysal

İstanbul University Cerrahpaşa Medical Faculty, Division of Pediatric Neurology, İstanbul, Turkey

**İstanbul University Cerrahpaşa Medical Faculty, Division of Pathology, İstanbul, Turkey*

Summary

Lafora disease is a rare progressive myoclonus epilepsy with an autosomal recessive inheritance characterized by seizures, myoclonus and progressive cognitive decline. At the beginning of the symptoms the disease may be misdiagnosed as benign epileptic syndromes. Herein we present a 17-year-old girl followed up with juvenile myoclonic epilepsy who presented to our clinic with refractory seizures and dementia. A skin biopsy showed Lafora bodies and the diagnosis of Lafora disease was made. (*Turk Arch Ped* 2011; 46: 161-3)

Key words: Lafora disease, myoclonus, progressive myoclonic epilepsy

Introduction

Progressive myoclonic epilepsies (PME) are a rare, symptomatic group of epilepsy with genetic origin. They progress clinically with progressive neurological deterioration including mainly stimulus-sensitive myoclonic seizures, tonic clonic seizures, cerebellar findings and mental failure (1,2). The onset usually occurs in childhood or adolescence. They compose less than 1% of all epilepsies (3). Lafora disease which is one of these epilepsies in this group was described by Lafora and Glueck (1) in 1911. It is a rare, autosomal recessive disease characterized by epilepsy, myoclonus, dementia and the presence of Lafora bodies in various tissues (1,4). It can be observed worldwide, but it is most commonly seen in Mediterranean countries and Canada (1). In this paper, a case who presented with treatment-resistant seizures and mental failure and was diagnosed as Lafora disease was presented.

Case report

A 17-years old girl presented to our clinic with complaints of seizure, falling while walking and amnesia. Medical history revealed that she had a febrile generalized

tonic clonic seizure at the age of 10 for the first time, febrile seizure repeated one year later and later afebrile seizures occurred 3-4 times a year. A diagnosis of juvenile myoclonic epilepsy was made when multiple spike-wave complexes were found on electroencephalogram at the age of 14 and valproic acid was started. Later various antiepileptic drugs were added because of continuing seizures and she was still using valproic acid+levetiracetam at presentation to our clinic. The family informed that the seizures did not decrease in frequency in spite of drug therapy, seizures involving jerks in the arms and legs occurred and she had to leave the school because of academic failure in school. The patient was hospitalized for further investigations because of resistant seizures and failure in cognitive functions. The parents were third degree relatives and the patient was the third child in the family. One sibling was lost at the age of 6 months because of an unknown cause and the other two siblings were alive and healthy. The 4-year old brother had a history of febrile convulsion. There was no other pathology in familial history.

On physical examination the height and weight were within normal percentiles. She was conscious and cooperated. Cognitive dysfunction was present. Emotional variability was noted. Muscle tonus, examination of the

cranial nerves and reflexes were found to be normal. A mild dysarthria and tremor was present. She had no sensory defect.

Laboratory tests revealed that complete blood count, hepatic and renal function tests, electrolytes, blood lactate, ammonia, vitamin B12 levels were normal. Blood and urinary amino acids and urinary organic acids were found to be normal. Blood valproic acid level was found to be 122.3 mc/ml (50-100). Fundoscopic examination was found to be normal. On electroencephalogram, patchy diffuse and rapid spike-wave discharges on slow wave activity displaying paroxysmal characteristic were observed in the temporoparietooccipital region (Figure 1). IQ was found to be 50 according to Cattell test which is one of the neuropsychologic tests. No pathology was found on cranial magnetic resonance imaging and positron emission tomography. Lafora disease which is one of the progressive myoclonic epilepsies was considered in the patient and deep cutaneous biopsy was performed in the axillary apocrine sweat glands. Cutaneous biopsy revealed the presence of Lafora bodies displaying PAS positivity and resistance to diastasis in the apocrine glands and a diagnosis of Lafora disease was made (Figure 2). Valproic acid dose was adjusted. Cutaneous biopsy was planned for the sibling who had a febrile convulsion at the age of four and who had a normal EEG. On follow up, the patient had no seizures and was discharged followig appointment for follow up.

Discussion

Lafora disease which was firstly described in 1911 (Online Mendelian Inheritance in Man [OMIM®] 254780) is an autosomal recessive progressive myoclonic epilepsy characterized by seizures, myoclonus and dementia (1,5,6). Age of onset is between 10 and 19 years (4). It usually starts with diffuse tonic clonic convulsions and partial seizures (visual hallucination and scotoma) and then asymmetric myoclonus, dementia and ataxia develop (3). At the beginning, it is difficult to differentiate this disease

from the other benign myoclonic epilepsies. Because of the similarity of age of onset and the presence of myoclonus and light-sensitive seizures, it can be confused with benign juvenile myoclonic epilepsy which is more common (2,5,7). However, slow background activity on EEG, resistance to antiepileptic drugs, presence of other types of seizures (visual, complex partial or absence), cognitive dysfunction and rapid progression of the findings arouse suspicion of progressive myoclonic epilepsy (1,3,5). In adolescents, these findings suggest Lafora disease. The findings progress to myoclonus triggered by movement and external stimuli (light, sound, touch), resistant seizures, psychosis, ataxia, dysarthria and dementia in the following years. The prognosis is poor. These patients are usually lost in 10 years (5).

Lafora disease is thought to be caused by a defect in carbohydrate metabolism. Pathognomonic Lafora bodies are intracellular bodies formed of abnormal glycogen named polyglucosan. These bodies are deposited in neurons and other tissues including the heart, liver, muscle and skin (5). Lafora disease is inherited in an autosomal recessive manner. Mutations in EPM2A gene located in the region of 6q23-25 and EPM2B gene located in the region of 6p22-32 are responsible for the disease (3,8). EPM2A gene encodes tyrosine phosphatase (Laforin protein) and EPM2B gene encodes malin protein; both proteins remove polysaccharides from the cell by tyrosine phosphatase activity (3,5). Demonstration of Lafora bodies by biopsy is diagnostic (9). Since Lafora bodies are observed in the eccrine and apocrine ducti, the axilla is the most appropriate region for biopsy (10). Cutaneous biopsy should involve eccrine and apocrine sweat glands. False negative results are frequently found because of sampling errors (2,11,12). Genetic diagnosis is possible. In all cases, both genes have been found to be mutated (3).

No curative treatment is available for Lafora disease. Valporate, phenobarbital, benzodiazepines, levetiracetam and zonisamine in combination may be beneficial in the

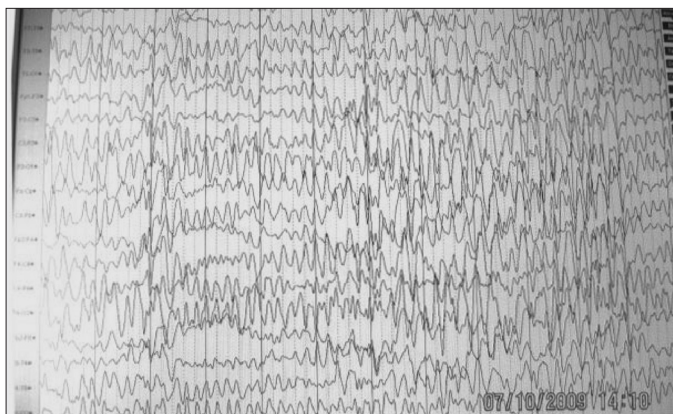


Figure 1: Patchy diffuse and rapid spike-wave discharges on slow wave activity with a paroxysmal characteristic in the temporoparietooccipital regions

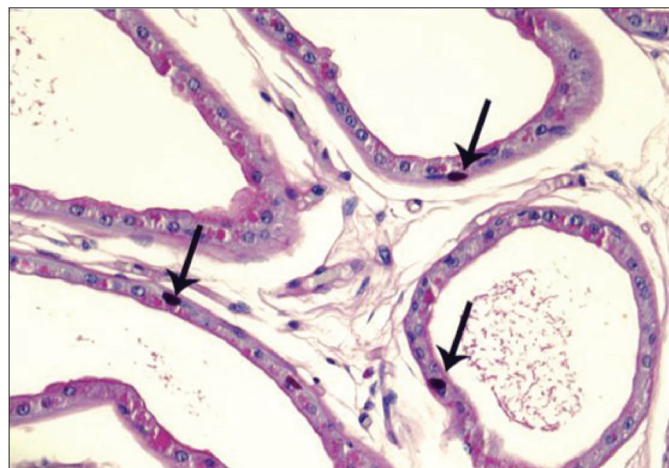


Figure 2: Lafora bodies in the apocrine glands displaying PAS positivity and resistance to diastasis

early period for myoclonus. To prevent worsening of myoclonus carbamazepine, phenytoin, gabapentin, pregabalin and lamotrigine should be avoided. In the future, gene therapy will be an option (2,5). Currently, studies related to EPM2A gene have shown progression (3).

In our country, mostly studies for pre-genetic clinical and laboratory diagnosis can be conducted in current conditions. Considering the variability of disease genes between populations, determining the profile of epilepsy genetics is important in terms of guiding feasible treatment methods in the future (3).

Consequently, cases diagnosed as juvenile myoclonic epilepsy accompanied by cognitive deterioration and slowing of background rhythm on EEG should be reevaluated in terms of myoclonic epilepsies and Lafora disease.

Conflict of interest: None declared

References

1. Baykal BB, Özemir ZA. Progresif miyoklonik epilepsiler. İçinde: İbrahim Bora, Naz Yeni, Candan Gürses, (yazarlar). Epilepsi. İstanbul: Nobel tıp kitabevleri, 2008: 271-90.
2. Panayiotopoulos CP. A clinical guide to epileptic syndromes and their treatment. Second edition. Springer, Oxfordshire, 2007: 475-82.
3. Baykal B. Progresif miyoklonik hastalıklar- Lafora hastalığı. Epilepsi 2008; 14: 17-51.
4. Kaplan KJ, Nelson BL. Pathologic quiz case myoclonic epilepsy and cognitive decline in a 19-year old man. Arch Pathol Lab Med 2003; 127: 231-2.
5. Striano P, Zara F, Turnbull J, et al. Typical progression of myoclonic epilepsy of the Lafora type. Nature clinical practice neurology 2008 ;4: 106-11.
6. Lafora GR, Glueck B. Contribution to the histopathology of the myoclonic epilepsies (German). Z Gesamte Neurol Psychiatr 1911; 6 :1-14.
7. Güler A, Gökçay A, Kandiloğlu G, ÖE Özbay, H Karasoy. Juvenil miyoklonik epilepsi kliniği ile prezente olan lafora hastalığı. Ege Tıp Dergisi 2009; 48: 131-4.
8. Jansen AC, Andermann E. Progressive myoclonus epilepsy, Lafora type. Gene reviews NCBI Bookshelf 13.05.2009.
9. Carpenter S, Karpati G. Sweat gland duct cells in Lafora disease diagnosis by skin biopsy. Neurology 1981; 31: 1564-8.
10. Karimipour D, Lowe L, Blaivas M, Sachs D, Johnson TM. Lafora disease: diagnosis by skin biopsy. J Am Acad Dermatol 1999; 41: 709-12.
11. Franceschetti S, Gambardella A, Canafoglia L, et al. Clinical and genetic findings in 26 Italian patients with Lafora Disease. Epilepsia 2006 ;47: 640-3.
12. Turnbull J, Kumar S, Muralitharan S, et al. Lafora progressive myoclonus epilepsy: Disease course homogeneity in a genetic isolate. J Child Neurol 2008; 23: 240-2.