

Case report: Congenital self-healing reticulohistiocytosis (Hashimoto-Pritzker disease)

Zeynel Gökmen, Servet Özkiraz, Halil Kıyıcı*, Ayşe Ecevit, Aylin Tarcan

Başkent University Medical Faculty, Department of Pediatrics, Ankara, Turkey

Başkent University Medical Faculty, Department of Pathology, Ankara, Turkey

Summary

Langerhans cell histiocytosis is characterized by a clonal proliferation of activated Langerhans cells. LCH may be localized in the skin (congenital self-healing reticulohistiocytosis) or may be associated with dissemination and organ dysfunction. Absence of extracutaneous involvement as well as spontaneous resolution are essential for a definitive diagnosis of CSHR. Spontaneous resolution of the lesions does not preclude the possibility of relapse, either in the skin or at extracutaneous sites. Relapses involving the skin, mucosa, bone, and pituitary gland have been reported. Herein we present a CSHR case who developed a tachycardia attack due to atrioventricular disassociation on follow-up visits. (*Turk Arch Ped* 2011; 46: 84-6)

Key words: Newborn, histiocytosis, tachycardia

Introduction

Langerhans cell histiocytosis (LCH) is a group of disease arising from histiocytes characterized by clonal proliferation of activated Langerhans cells and its pathogenesis is not clear. The disease is primarily seen in the childhood and clinical findings are related to the involved organ system (1).

Langerhans cell histiocytosis occurs most commonly with skin involvement (in 50% of cases and as the first sign) under the age of two. The disease involving the skin may be limited to the skin only (congenital self-healing reticulohistiocytosis) or may be associated with dissemination and involvement of other organs (2). Congenital self-healing reticulohistiocytosis was first described by Hashimoto and Pritzker in 1973 as a rare clinical form of LCH.

The characteristics of the disease are as follows:

- 1- Congenital skin lesions or skin lesions occurring during the newborn period.
- 2- Healthy appearing baby with no signs of systemic involvement

- 3- Langerhans cell infiltration on histopathology
- 4- Self-healing in 1-3 months and absence of systemic involvement in long-term follow-up.

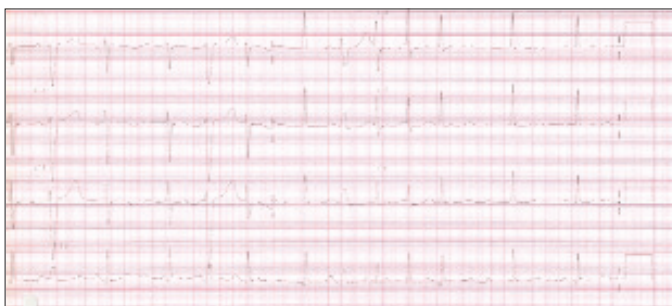
Other three clinical forms of LCH (solitary/multifocal eosinophilic granuloma, Hand Schüller Christian disease; multifocal Langerhans cell histiocytosis and Letterer Siwe; acute disseminated Langerhans cell histiocytosis) may be fatal, but congenital self-healing reticulohistiocytosis constitutes the clinical form with favorable course (3). We present our patient because she is a case of congenital self-healing reticulohistiocytosis who developed tachycardia due to atrioventricular dissociation during follow-up.

Case report

A female baby who was born at 32 weeks as a twin sister with Cesarean section because of early labor to a mother of 35 years old (G3P3Y3) with a birth weight of 1700 g was referred to our hospital because of increase in respiratory distress on the second day after birth. Co-

twin of the patient whose parents were first-degree cousins died because of respiratory distress syndrome at the 6th hour after birth. Physical examination revealed the following: body weight: 1650 g (>10%), height: 43 cm (>10%), head circumference 28 cm (>10%), general status moderate, marked groaning, subcostal retraction and decrease in the lung sounds, a few pinpoint-size lesions with crusts. Other systemic examination findings were normal. Laboratory investigation revealed the following: Hb: 18.2 g/dL, Hct: 52.4%, white blood cells: 10200/mm³, platelets: 421000/mm³, CRP: 1.65 mg/L. Peripheral blood smear, hepatic and renal function tests and electrolytes were normal. Reticular appearance and air bronchograms were seen on chest graphy. Surfactant therapy was given to the patient on the second day after birth because of RDS. On the third day she was extubated, on the sixth day oxygen supply was stopped and full enteral feeding was started.

On the 10th day of hospitalization disseminated vesiculopustular lesions developed on the whole body. Topical antifungal and antibacterial treatment was started considering infectious vesiculopustular dermatosis (Picture 1). Despite treatment lesions persisted. Gram and Wright investigation in the smear of the lesion, fungal screening, lesion culture and blood culture, cytomegalovirus (CMV) and herpes type 1-2 IgM were found to be normal. On cutaneous biopsy, cell group with



Picture 1. Atrio-ventricular dissociation

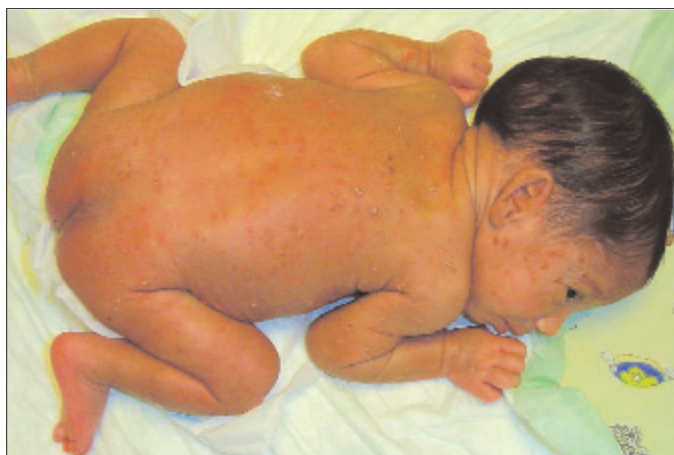

Figure 1. Skin findings of the patient on the 10th day of life

eosinophilic cytoplasm some including notched nuclei or nuclei in the form of a kidney and extending to the epidermis was observed in the superficial dermis and in the pustule. Immunohistochemical examination revealed S100 positivity and nonspecific background staining and findings were found to be compatible with LCH. For screening systemic diseases complete blood count, complete urinalysis, biochemical tests, coagulation tests, abdominal ultrasonography and bone screening was performed and was evaluated to be normal. On follow-up, skin lesions improved spontaneously leaving hypopigmented scar in the 3rd month. On the 4th month follow-up, tachycardia and arrhythmia was found and other systems were found to be normal. Electrocardiographic examination revealed ventricular premature beats and atrioventricular dissociation (Figure 1). Bone marrow examination, echocardiography, bone screening, cranial magnetic resonance imaging (MRI) and biochemical tests repeated for screening systemic diseases were found to be normal. Arrhythmia was improved spontaneously without treatment. Our patient is 5 years old now and no other problem developed in the follow-up (Picture 2).

Discussion

Congenital self-healing reticulohistiocytosis is a rare form of LCH limited to the skin and regressing spontaneously. After the first case described by Hashimoto and Pritsker in 1973 about 100 cases have been reported in the literature. Since skin lesions improve spontaneously, the actual incidence is not known (4). In a study performed by Kapur et al. (2) only 11 cases of congenital self-healing reticulohistiocytosis were defined in centers in 10 years and 9 of them were diagnosed in the last 5 years after the centers started to work with pediatric dermatologists. The actual incidence may be higher than the one reported in the literature because of undefined cases and the self-healing nature of the disease.

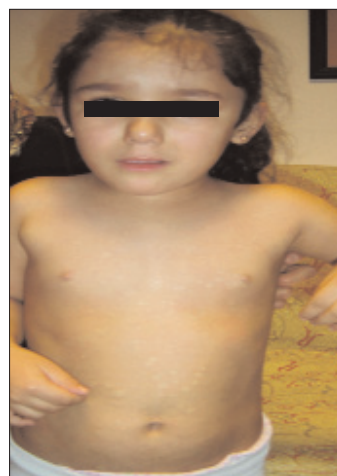

Figure 2. Patient at five years of age

Etiology and pathogenesis of Langerhans cell histiocytosis and various types of this disease is not clear. Viral, immunologic and neoplastic mechanisms have been proposed, but not proven (5,6). Currently, viral infection assumption is still controversial despite viral genom studies and epidemiological data also support viral etiology (6). While Ariko et al. (6) have reported high rate of association (86%) in monozygotic twins, Ersoy-Evans et al. (5) have found congenital self-healing reticulohistiocytosis in their monozygotic twin patients. Genetic studies performed in cell cultures of patients with a diagnosis of Langerhans cell histiocytosis have showed increase in translocations and chromosomal fractures. Cases with multiple family members with a diagnosis of LCH have been reported. All these data support the role of genetics in pathogenesis (5).

Clinical findings of congenital self-healing reticulohistiocytosis may be seen at birth or in the first two months of life (7). Generally, red-brown papulonodular or veziculopustular rash is seen diffusely on the face, trunk and scalp. Cases with single lesion or hemorrhagic, bulleous, urticarial and "blueberry muffin" lesions have also been reported. For the diagnosis of congenital self-healing reticulohistiocytosis extra-cutaneous involvement should be absent and lesions should regress spontaneously (3). The diagnosis is made by showing mononuclear and multinuclear infiltration containing Birbeck's granules histologically and staining with S100 and/or CD1 immunohistochemically (3,5).

The prognosis is favorable in LCH cases with skin lesions occurring in the early newborn period and no extra-cutaneous involvement and lesions generally heal spontaneously without need for any treatment in three months leaving hypopigmented or hyperpigmented spots. Self-healing of lesions does not exclude the possibility of involvement of other organs in follow-up; in long-term follow-up involvement of skin, mucosa, bone and

pituitary gland has been reported (3). Estery et al.(8) have reported diabetes insipidus as late involvement in a case with no problem arising until 4 years. Dysrhythmia which was found in our patient has not been reported in the literature before; echocardiography and screening for systemic involvement was normal. Dysrhythmia was not considered to be related to organ involvement and improved spontaneously in follow-up.

Consequently, the incidence of the disease may actually be higher than the one reported and the patients should be followed-up for long-term, since it proceeds with involvement of various systems.

Conflict of interest: None declared

References

1. Willman CL, Busque L, Griffith BB, et al. Langerhans cell histiocytosis (histiocytosis X): a clonal proliferative disease. *N Engl J Med* 1994; 331: 154-60. ([Abstract](#)) / ([Full Text](#)) / ([PDF](#))
2. Kapur P, Erickson C, Rakheja D, Carder KR, Hoang MP. Congenital self-healing reticulohistiocytosis (Hashimoto-Pritzker disease): Ten-year experience at Dallas Children's Medical Center. *J Am Acad Dermatol* 2007; 56: 290-4. ([Abstract](#)) / ([Full Text](#)) / ([PDF](#))
3. Walia M, Paul P, Mishra S, Mehta R. Congenital Langerhans cell histiocytosis: The self-healing variety. *J Pediatr Hematol Oncol* 2004; 6: 398-402. ([Abstract](#))
4. Minkov M, Prosch H, Steiner M, et al. Langerhans cell histiocytosis in neonates. *Pediatr Blood Cancer* 2005; 45: 802-7. ([Abstract](#)) / ([PDF](#))
5. Ersoy-Evans S, Gursoy T, Yigit S, Akcoren Z, Sahin S. Solitary congenital self-healing reticulohistiocytosis in monozygotic twins. *Pediatr Dermatol* 2006; 23: 273-5. ([Abstract](#)) / ([PDF](#))
6. Arico M, Danesino C. Langerhans' cell histiocytosis : is there a role for genetics ? *Haematologica* 2001; 86: 1009-14. ([Abstract](#)) / ([PDF](#))
7. Ersoy-Evans S, Sahin S, Ozkaya O. Solitary congenital self-healing reticulohistiocytosis. *Turkiye Klinikleri J Dermatol* 2006; 16: 194-6. ([Abstract](#)) / ([PDF](#))
8. Estery NB, Maurer HS, Gonzalez-Crussi F. Histiocytosis X: a seven-year experience at a children's hospital. *J Am Acad Dermatol* 1985; 13: 481-95. ([Abstract](#))