

Late Acute Spontaneous Giant Epidural Hematoma After Ventriculoperitoneal Shunt Surgery: A Case Report

Engin YÜCEL¹, Nilüfer TAŞ²

¹Alanya Eğitim Araştırma Hastanesi

²Sağlık Bilimleri Üniversitesi, İstanbul Gaziosmanpaşa Taksim Sağlık Uygulama Ve Araştırma Merkezi

Abstract

Introduction: Subdural hematoma is the most common type of hemorrhage as a shunt complication following ventriculoperitoneal shunt procedures. This hemorrhage is caused by rupture of the bridging veins between the dura mater and brain due to a suddenly developing decrease in intracranial pressure. On the other hand, the mechanism of late epidural hemorrhage, a complication of ventriculoperitoneal shunt, could not be clarified very clearly.

Case Presentation: A 7-year old female patient had been operated for meningocele after birth. One month later, ventriculoperitoneal shunt had been placed. She presented to the emergency department with nausea, vomiting, blurred consciousness and loss of strength (2/5) in the left upper extremity 4 years after the revision. She had a Glasgow Coma Scale score of 10. Brain computed tomography revealed a giant epidural hematoma in the right hemisphere.

Conclusion: Brain computed tomography should be obtained in the postoperative period and anti-siphon device should be used when placing ventriculoperitoneal shunt. In addition, we argue that use of moderate-high pressure shunt is not definitely effective in preventing development of epidural hemorrhage.

Keywords: Hydrocephaly – Epidural hematoma – VP shunt complication

Introduction

Subdural hematoma, which is currently one of the common complications following ventriculoperitoneal (VP) shunt, was discussed in detail for the first time by Dandy¹. It is generally observed in the first days following shunt placement or in the late period, but non-traumatic epidural hematoma always occurs in a few hours following shunt placement². Especially, the mechanism of epidural hemorrhage that develops in the burr hole site in pediatric patients and in a few hours following shunt placement is also known clearly. The mechanism of ossified epidural hematoma, which generally causes patients to present with chronic headache in the late period following VP shunt placement, has been partially explained. In fact, the time of onset of calcification of epidural hemorrhage has been found to be 10 days-50 years in cases of traumatic hemorrhage^{3,4}. Sengupta et al. stated that 2 factors were required for development of epidural hemorrhage. The first factor was reported to be origin of hemorrhage, and the second factor was reported to be separation of duramater from the osseous tissue⁵. The development of epidural hemorrhage in the burr hole site can be explained by vascular injury in the dura or inadequate bleeding control in the bone. However, the development of hemorrhage away from the burr hole site, especially in the frontal region, has been as-

sociated by Luys with the result that the dura mater is attached to the bone more loosely in the anterior part of the cranium compared to the posterior part⁶. Hemorrhages developing in different regions following changes in intracranial pressure have also been explained with this mechanism. Although this mechanism has been considered and cited many times in those periods, current modern medicine discredits this mechanism.

Case

A 7-year old female patient had been operated for meningocele after birth. One month later, VP shunt had been placed. The patient who had paraparesis, had undergone shunt revision for the third time at the age of 3 years. She presented to the emergency department with nausea, vomiting, blurred consciousness and loss of strength (2/5) in the left upper extremity 4 years after the revision. She had a Glasgow Coma Scale (GCS) score of 10. The patient did not have a history of trauma, and physical examination did not reveal any finding of trauma. The patient had 2 siblings, and these 2 siblings had no history of morbidity. All hematological parameters were found to be normal. Brain computed tomography (BCT) revealed a giant epidural hematoma

Corresponding Author: Engin YÜCEL **e-mail:** drengin2005@yahoo.com

Received: 06.12.2020 • **Accepted:** 23.02.2021

DOI: 10.33706/jemcr.836595

©Copyright 2020 by Emergency Physicians Association of Turkey - Available online at www.jemcr.com

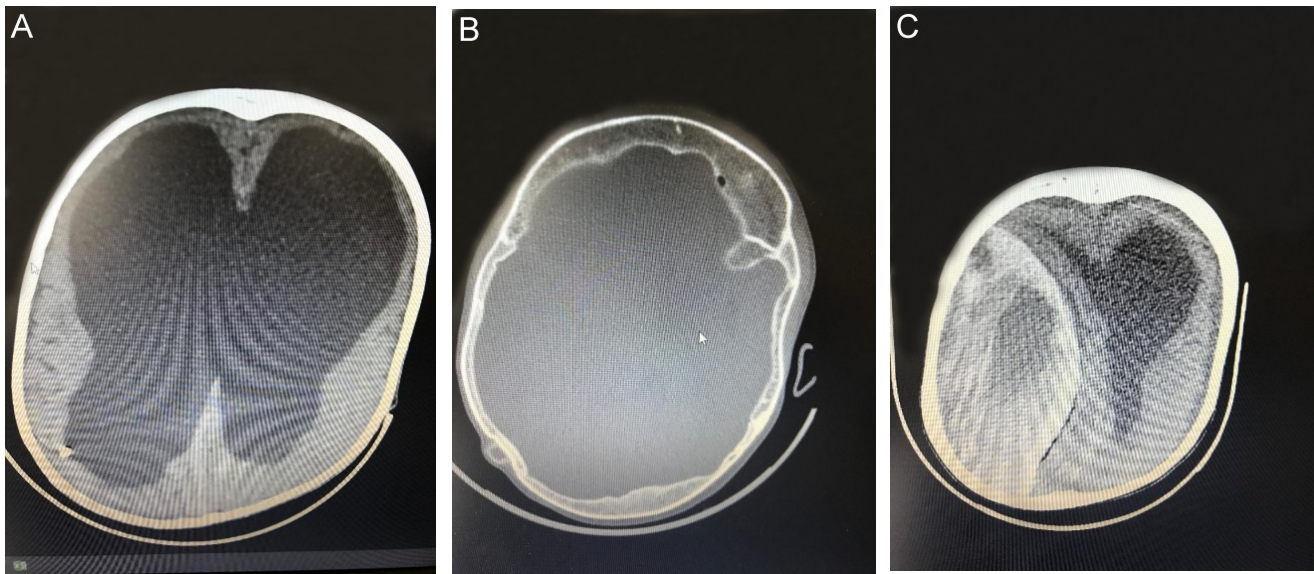


Figure 1: Preoperative BCT figures: A. Axial BCT demonstrating 4 years ago. **B.** Axial BCT demonstrating bone Picture. **C.** Axial BCT demonstrating right-sided epidural hematoma

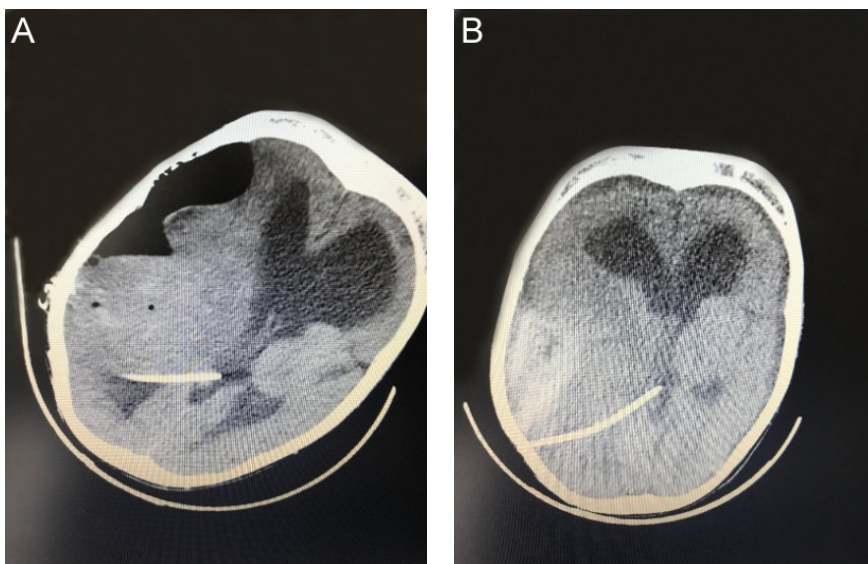


Figure 2: Postoperative BCT figures.
A. Immediately after surgery.
B. 1 week after surgery

in the right hemisphere (Figure 1). The patient underwent emergency surgery (Figure 3). Most of the hematoma was drained and no fracture was observed in the bone (Figure 2). However, she intraoperatively developed respiratory arrest. The dura was suspended, and the bone was replaced rapidly, and the operation was terminated. The patient remained connected to mechanical ventilator for 2 days, and she was extubated on the 3rd day. The GCS score of the patient who gained consciousness was 15. The paresis in the left upper extremity persisted when the patient was discharged.

Discussion

We reviewed the entire literature to explain the mechanism of epidural hemorrhage, which is among the hemorrhages

that develop following VP shunt procedure. Maurice et al. Presented 104 pediatric patients with traumatic epidural hemorrhage in detail. They injected warm gel into the epidural space of operated patients and observed that there was tight connection only between the dura and bone in the coronal suture region ⁷. This study supports Luys's (in 1901) argument that the dura-bone connection in the frontal region is loose. Moderate-high pressure shunts, anti-siphon devices and adjustable pressure or flow control devices have generally been recommended to prevent this complication. However, non-traumatic hemorrhage developed in a moderate-pressure, flow control shunt used in a case presented by Seyithanoglu et al. ⁸. A high pressure and flow control shunt was used in the case we presented. In the literature, we could not find any non-traumatic spontaneous epidural hemorrhage developing in the long period to such an extent as in the case we presented.

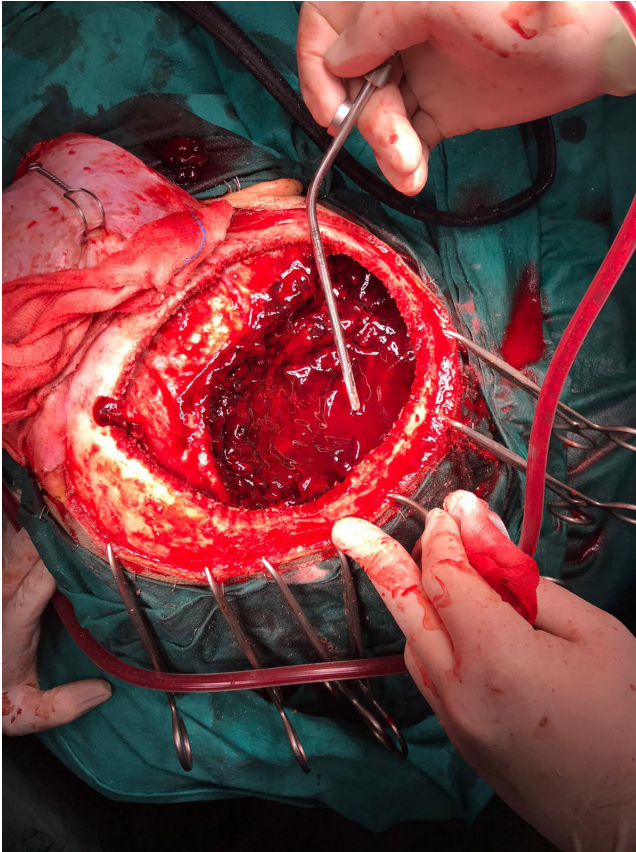


Figure 3: Peroperative view

Conclusion

We recommend that bleeding and cerebrospinal fluid (CSF) leak control should be performed accurately, patients should

be brought to the sitting position slowly and in a controlled manner, BCT should be obtained in the postoperative period and anti-siphon device should be used when placing VP shunt. In addition, we argue that use of moderate-high pressure shunt is not definitely effective in preventing development of epidural hemorrhage.

References

1. Payr, E. Drainage der Hirnventrikel mittels frei transplantiertes Blutgefasse; Bemerkungen über Hydrocephalus. *Arch. Klin. Chir.* 1908, 87: 801-885.
2. Rickham, P. P, and Roberts, J. R. Treatment of Hydrocephalus. *Brit. Med. J.*, 1960, 1:1887
3. Erdogan B, Sen O, Bal N, Cekinmez M, Altinors N: Rapidly calcifying and ossifying epidural hematoma. *Pediatr Neurosurg* 39:208-211, 2003. DOI: 10.1159/000072473
4. Nagane M, Oyama H, Shibui S, Nomura K, Nakanishi Y, Kamiya M: Ossified and calcified epidural hematoma incidentally found 40 years after head injury: Case report. *Surg Neurol* 42:65-69, 1994. DOI: 10.1016/0090-3019(94)90252-6
5. Luys, G. (1901). Les blessures des sinus de la dure-mere. *Presse Medicale*, 9, 278-281.
6. Iwakuma T, Brunngraber CV: Chronic extradural hematomas: a study of 21 cases. *J Neurosurg* 38:488-493, 1973. DOI: 10.3171/jns.1973.38.4.0488
7. Choux M, Grisoli F, Peragut JC: Extradural Hematomas in Children. 104 cases: 337-347, 1975. DOI: 10.1159/000119585
8. Seyithanoglu H, Guzey Karagoz F, Emel E, Ozkan N, Aycan A: Chronic Ossified Epidural Hematoma After Ventriculoperitoneal Shunt Insertion: A Case Report. *Turkish Neurosurgery* 2010, Vol:20, No:4, 519-523. DOI: 10.5137/1019-5149.JTN.2231-09.1