

Findings of Focal Adenomyosis in a Case of Inguinal Hysterocele Accompanied With Mammary Tumour in a Bitch

Yavuz NAK* Deniz MISIRLIOĞLU** Deniz NAK*
Bilginer TUNA* İsmail Hakkı KUMRU* Aylin ALASONYALILAR**

Geliş Tarihi: 20.08.2004

Kabul Tarihi: 07.10.2004

Abstract: In this report, inguinal hysterocele and focal adenomyosis is described in a six years old Terrier bitch, with the recognition of a mammary tumour. During the course of mammary tumour removal, a concurrent inguinal hysterocele was observed. In the uterine wall sphere-shaped, firm tissues and cystic formations were determined. Histopathologically, mammary tumour type was considered as schirrhous adenocarcinoma. Firm tissues and cystic formations in the uterine wall were considered as focal adenomyosis. Information about the history, clinical, laboratory and pathological findings were given.

Key Words: Bitch, Mammary tumours, Inguinal hysterocele, Focal adenomyosis.

Bir Köpekte Meme Tümörü ile Birlikte Karşılaşılan İnguinal Hysterocele Olgusunda Focal Adenomyosis Bulguları

Özet: Bu raporda meme tümörü şikayeti ile gelen 6 yaşlı Terrier ırkı dişi bir köpekte inguinal hysterocele ve focal adenomyosis olgusu tanımlandı. Meme tümörünün alınması esnasında meme tümörüyle birlikte inguinal hysterocele saptandı. Uterus duvarında yuvarlak biçimde sert doku kitleleri ve kistik oluşumlar belirlendi. Histo-patolojik olarak meme tümörüne adenokarsinom teşhisi kondu. Uterusun histopatolojik muayenesinde ise focal adenomyosis tanısı kondu. Olgunun tarihçesi, klinik, laboratuvar ve patolojik bulguları hakkında bilgi verildi.

Anahtar Kelimeler: Köpek, Meme tümörü, İnguinal hysterocele, Focal adenomyosis.

Introduction

Canalis inguinalis is open physiologically in carnivores. Young bitches have processus vaginalis in the canalis inguinalis. Bitch is the only animal that has processus vaginalis. There is a cord which goes posteriorly below the processus vaginalis. Provided that each processus vaginalis is incised, ligamentum teres uteri might be seen that adheres to the distal tip of processus. This ligament may direct uterus within the content through the processus vaginalis at pregnancy. For that reason, hernia uteri might be seen in the canalis inguinalis¹.

Mammary tumours are more seen in bitches than the skin tumours, and adenocarcinomas are the most common malignant tumour type. Neoplastic transformations of the mammary cells might be influenced by a starting factor and stimulated by anormal growth factor. Steroid hormones may influence as a starting or exaggerating factor. Progestins stimulate Insulin-like growth factors(IGFs) and IGF-binding proteins. Proliferative environment is formed to such an extent that malignant transformation might be increased. Oestrogen has a mitogenic effect for mammary epithelium².

* Department of Obstetric and Gynecology, Veterinary Faculty, Uludag University, Bursa.

** Department of Pathology, Veterinary Faculty, Uludag University, Bursa.

Cystic endometrial hyperplasia (CEH) which precedes pyometra as a clinical disease is characterized by collection of pus into the uterus in mature bitches. The disease is formed postoestrially and goes acute or chronic which has various degrees of clinical and pathologic symptoms. Primary pathologic lesion of pyometra is cystic endometrial hyperplasia followed by a secondary bacterial infection. Progesterone stimulates endometrial proliferation, secretory activity of endometrial glands and inhibits myometrial contractions. Progestogens also keep the cervix closed. Experimental exposure of the progestogens including megestrol acetate and medroxyprogesterone acetate, causes superficial epithelial proliferation and increased secretory activity of endometrial glands³.

Oestrogens increase the endometrial growth, vascularisation, edema and cervical relaxation. They stimulate the migration of polymorphonuclear leucocytes into the uterus lumen. Using oestrogen alone experimentally does not cause specific pathologic change. Oestrogens increase the number of specific progesterone receptors in the endometrium, thereby increase the progesterone effect upon endometrium. In an uncomplicated CEH case, endometrium is covered by irregular cystic structures 4-10 mm in diameter and also becomes thick. Along the endometrium the number of glandular structures are obviously increased. Settlement and size of glands are irregular. Semitransparent cysts are seen in the endometrium widespread. As the disease advanced bacterial contamination with infiltration of the defending cells, endometrial ulceration and hemorrhage, collection of inflammatory content in the uterus lumen varies from reddish-brown to yellow-green colour, deep infiltration of neutrophils in the endometrium, opening and drainage of uterus content through the cervix, increasing the diameter of cornu uteri, thickening of uterine wall and endometrial atrophy are observed³.

Myometriosis is defined as the observation of endometrial glands and stroma in the myometrium. In some cases malformation and excessive hyperplastic growth of endometrium are noticed⁴.

Round-formed formations 4-8 cm in diameter are stated in the case of adenomyosis in two dogs⁵. Gelberg and McEntee⁶, noticed adenomyosis in one cat and dog. Using oestrogen for six months postmenopausal in women causes adenocarcinoma and adenomyosis in the uterus⁷.

Determination of Case

A six years old, Terrier breed bitch was brought to the clinics of veterinary Faculty of Uludag University, with swelling at the caudal of left inguinal mammary gland which enlarged in a four months course and both mammary glands had masses.

Results

Clinical Examination: At clinical examination body temperature, respiration and pulsation values were found normal. At inspection and palpation a spherical swelling, 7x6 cm in dimensions, was determined at the caudal of the left inguinal mammary gland, and furthermore firm masses which had 3x2x2 cm dimensions were identified at the right inguinal mammary gland. Enlargement of the left popliteal, mandibular, axillary and inguinal lymph nodes were confirmed at palpation.

Haematologic and biochemistic values were in the normal levels. The haematologic results were as: Total WBC $6.4 (x10^3/\mu\text{l})$, RBC $6.27 (x10^6/\mu\text{l})$, HCT 41.8 (%), MCV $66.7 \mu^3$, PLT $224 (x10^6/\mu\text{l})$, neutrophil 81%, lymphocyte 19%. The biochemistic results were as: Creatinine 0.78 mg/dl, ALT 23.3 U/L, GGT 5.15 U/L, Urea 21 mg/dl.

Clinical Diagnosis: The swelling at the caudal part of the left inguinal mammary gland was diagnosed as hernia reponibilis because of its compressibility. Firm masses which localized in the both inguinal mammary glands were identified as mammary tumours.

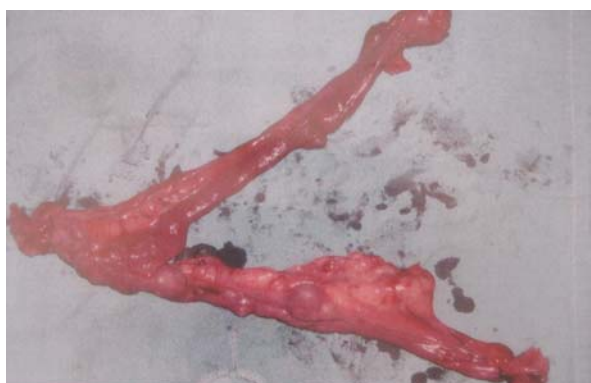Treatment: Dissociative anesthesia was applied with Xylazine (1.1 mg/kg) and Ketamine hydrochloride (10 mg/kg). The firm tumour in the left mammary gland was dissected from the dermal and subdermal tissues. Hernia reponibilis was observed at the caudal of the neoplastic mass and dorsal of the canalis inguinalis. The junctions between neoplastic mass and tissues above the canalis inguinalis were bluntly separated from each other. Interior hernial sac which had cornu uteri with firm node-shaped masses at the outer surface was opened. Inguinal ring was extended by an incision with blunt scissors and ovariohysterectomy was performed. After inner hernial

sac was ligatured at the abdominal level, remnants near the dorsal of the ligatur was removed. Canalis inguinalis and opened abdominal wall were sutured with sultan sutures. Neoplastic structures and both mammary glands were removed by mammectomie. Ovari, uteri, mammary glands were sent to Department of Pathology, for histopathological examination.

Histopathological Diagnosis: Tissue samples taken from cornu uteri and mammary gland were fixed in 10% phosphate buffered formaldehyde solution for 48 h and processed routinely: embedded in paraffin, sectioned at 5 µm and stained with hematoxylin-eosin (HE). Sections were examined histologically in light microscope.

Macroscopical Findings: The mammary tumours were observed as hard masses and were white in color.

Uterus specimen had 11 nodular formations with diameters of about 2 cm. On the outer surface of the corpus uteri wall, nodular masses were observed which contained cysts with 0.1-0.5 cm diameter in cross section (Fig.1).



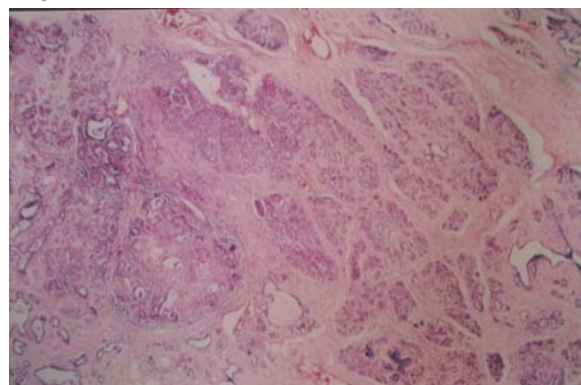
*Figure 1:
The appearance of uterus with nodular formations to diameters of about 2cm after ovari hysterectomie*

*Şekil 1:
Overiohysterectomi sonrası yaklaşık 2 cm çapındaki noduler yapılar ile birlikte uterusun görünüşü*

Microscopical Findings: In the tumour mass taken from the mammary gland, the glandular and connective tissue were excessively increased in amount. Glandular and solid infiltrations which originated from mammary gland epithelia were noticed in various parts (Fig.2).

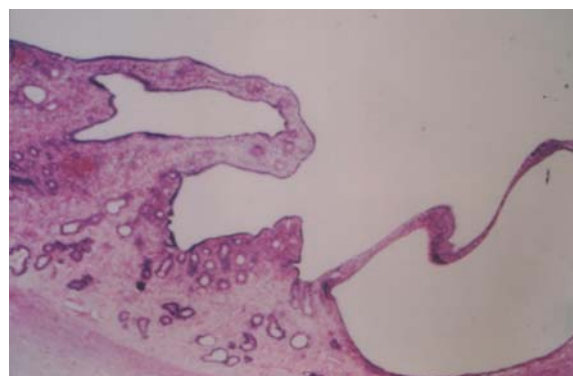
Anizonucleosis was observed in tumour cells, and hemosiderin-loaded macrophages were detected among the glandular epithelium. Cell infiltrations which comprised majority of plasma cells and lymphocytes invaded the tumor tissue.

In the lumen of the uterus an exudate which included few erythrocytes, several neutrophil leukocytes and plasma cells were seen. Uterus glands showed intense cystic alterations and in some glands the luminal epithelium was hyperplastic. In the lumen of the uterus glands, mild cell infiltration, mainly of neutrophil leukocyte, was also seen (Fig.3). Haemorrhagia existed in various parts of the propria mucosa. Uterine glands with cystic alterations were also observed at the lamina muscularis of the uterine wall (Fig.4).



*Figure 2:
Increased glandular and connective tissue in the mammary tumor.*

*Şekil 2:
Meme tümöründe glanduler ve connectiv dokuda artış.*



*Figure 3:
A view of cystic endometrial hyperplasia-pyometra complex.*

*Şekil 3:
Kistik endometrial hiperplazi – pyometra kompleksinin görünüşü.*

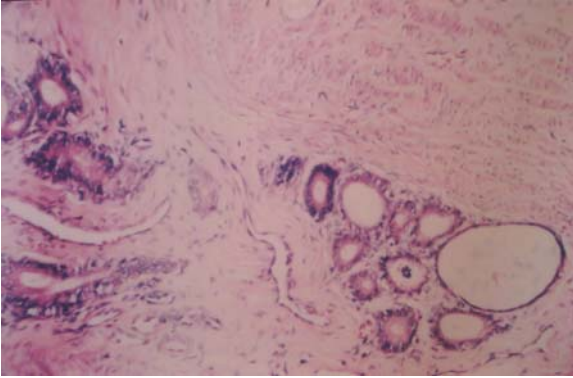


Figure 4:
Uterine glands with cystic alterations at the lamina muscularis of the uterine wall.

Şekil 4:
Uterus duvarının lamina muscularisinde kistik değişiklikler ile birlikte uterus bezleri.

Histopathological Diagnosis: Cystic endometrial hyperplasia-pyometra complex and focal adenomyosis (internal endometriosis) were detected in the endometrium.

Scirrhus mammary adenocarcinoma was noticed in the inguinal mammary glands.

Discussion and Conclusion

Uterus rarely herniates through canalis inguinalis. Adhered ligamentum teres uteri in the tip of the sac pulls a part of the pregnant uterus into the vaginal sac and therefore hernia occurs¹. In this case, it is thought that the foci of endometriosis on the cornu uteri and corpus uteri increased the weight and mass of uterus and this caused the hernia probably with the mechanism indicated above. It is supposed that the focal points grew up in time and that hinder the possibility of spontaneous reposition of the uteri. The diagnosis of the hernia was impossible to perform due to the same location of the malignant mammary neoplasm and herniated uterus.

As a result of histopathological examination of the herniated uterus, cystic endometrial hyperplasia-pyometra and focal adenomyosis were diagnosed. The term adenomyosis applies to the presence of endometrial glands and stroma between the muscle bundles of myometrium. In some cases, it is a malformation, and in others it arises by hyperplastic overgrowth of the endometrium. It is not a common lesion in any domestic species but is seen in the bitch with cystic endometrial hyperplasia⁴ as we are observed in this case. It is known that steroids play an impor-

tant role in the formation of cystic endometrial hyperplasia-pyometra complex³. It is stated that progestins stimulate Insulin-like Growth Factor (IGF) and IGF-binding protein at the neoplastic change of mammary cells. Thus, it is stated that environment which is highly proliferative increases the malignant changes and estrogens also have mitogen effect for mammary epithelium². Adenocarcinoma and adenomyosis develop in consequence of long-term estrogen usage in women menopausal period⁷. It's thought that assessing all these mechanism together with observing cystic endometrial hyperplasia-pyometra complex, adenomyosis and mammary adenocarcinoma, though sufficient data could not be obtained about whether using steroids with the aim of unwanted mating or suppressing the signs of estrus that effects the steroids because of the changing owner, using steroids may be an important factor in the forming of the case.

References

1. SEYREK-INTAS K, SEYREK-INTAS D. Köpekte hernia inguinalis uterogravido olgusu, Vet. Cer. Derg. 1997, 1(1):36 – 39.
2. JONSTON S.D, KUSTRIZ M.V.R. OLSON P.N.S. Disorders of the mammary glands of the bitch, in "Canine and feline theriogenology", Ed. Le Mello, 1 st ed., W.B. Saunders Company, Pennsylvania, 2001, 243 – 256.
3. JOHNSTON SD, KUSTRITZ MVR, OLSON PNS. Disorders of the canine uterus and uterine tubes(Oviducts), in "Canine and Feline Theriogenology", 1st ed., WB Saunders Company, Philadelphia, 2001, p206-224.
4. JUBB KVF, KENNEDY PC, MILLER RB. The Female Genital System In Pathology of Domestic Animals, Eds. K.V.F. JUBB PC, KENNEDY N.Palmer, 4th edn, p377, Academic Press, Inc. San Diego, California, 1993.
5. GAUTSCHI SNM, GUSCETTI F, REICHLER IM, GEISSBUHLER U, BRAUN SA, ARNOLD S. Identification of focal adenomyosis as a uterine lesion in two dogs, J Small Anim Pract 2001, 42(8):413.
6. GELBERG HB, Mc ENTEE K. Pathology of the canine and feline uterino tube, Vet Pathol 1986, 23(6):770.
7. KHUSH R, MITTAL MD, KENNET W, BARWICK, MD. Endometrial adenocarcinoma involving adenomyosis without true myometrial invasion is characterized by frequent preceding oestrogen therapy, low histologic grades, and excellent prognosis, Gyn Onc 1993, 49(2):197.