

A Case of Spontaneous Resolving Acute Appendicitis: A Surgical Dilemma

Spontan İyileşen Akut Apandisit

Berat ACU, Atilla ŞENAYLI, Ülkü BEKAR, Fevzi ATASEVEN

¹ Gaziosmanpaşa Üniversitesi Tıp Fakültesi, Radyoloji Anabilim Dalı,

² Gaziosmanpaşa Üniversitesi Tıp Fakültesi, Pediatrik Cerrahi Anabilim Dalı,

³ Gaziosmanpaşa Üniversitesi Tıp Fakültesi, Pediatrik Anabilim Dalı, TOKAT

SUMMARY

There were clinical and radiological reports declaring spontaneous resolving appendicitis. On the other hand, there have still been controversies in this subject. One of the major controversies is the way of treatment when acute appendicitis is detected reminding the clinical findings of spontaneous resolving. We reported a patient with a mild right lower quadrant abdominal pain. Our ultrasonographic findings were like appendicitis but as she did not have clinical correlation. We only follow up the patient but we experienced the surgical dilemma including the operation or conservative treatment. In this report, we emphasized the reality of spontaneous resolving appendicitis and we tried to strengthen the possible salvage mechanism like conservative treatment other than surgery, for a patient who may be admitted with spontaneous resolving appendicitis clinics in the future.

Key Words: Appendicitis, spontaneous, resolution, children.

ÖZET

Spontan iyileşen apandisiti tanımlayan klinik ve radyolojik yazılar vardır. Diğer taraftan, bu konu ile ilgili hala kararsızlıklar vardır. En önemli kararsızlıklardan biri ise spontan iyileşmenin klinik bulgularını gösteren akut apandisitte tedavi şeklinin ne olacağıdır. Orta şiddette sağ alt kadrın karın ağrısı olan bir hasta rapor edilmiştir. Ultrason bulgularımız apandisit ile uyumlu idi; ancak klinik korelasyonu yoktu. Hasta sadece takip edilmiştir, fakat bu süreç içinde ameliyat ve konservatif tedavi arasında kararsız kalmıştır. Bu yazıda, spontan iyileşen apandisit varlığı vurgulanmıştır ve gelecekte spontan iyileşen apandisit kiliniği ile gelen bir hastanın konservatif tedavi gibi ameliyat dışı koruyucu mekanizmaların kullanılabilirliğini vurgulanmıştır.

Anahtar Kelimeler: Apandisit, çocuk, spontan iyileşme.

INTRODUCTION

In 1886, Sir Reginald Fitz presented the classic description of appendicitis and, in the same report he described the clinical entity of recurrent acute appendicitis (1). Among these clinical and radiological aspects, supporting the presence of the spontaneous resolution of the acute appendicitis (SRA) was declared (1-4). Up to now, although there has been a lot of data documenting the SRA, controversy has still been present about the spontaneous resolving appendicitis among authors (5,6). The most conspic-

uous argument for SRA is the treatment which causes the main point of disagreement for the subject.

Herein, we delineated our first case of SRA diagnosed by coincidence during the diagnostic evaluation of a mild abdominal pain. We also surprisingly realized that our case was the first to be reported from our country. Although there was a treatment dilemma of this frequently operated disease, we were encouraged by the clinical and radiological status of the patient and chose not to operate the patient at the end. We aimed to demonstrate the concrete radiolog-

ical findings of the patient and, by this way, tried to strengthen the reality of SRA for the sake of non-operative therapy of this kind of patients.

CASE REPORT

Six-year-old girl patient was admitted to pediatric surgery clinics for a mild right lower quadrant abdominal pain. In history, she had no similar complaints or disease to cause chronic abdominal pain. The duration of pain was approximately 48 hours and parents emphasized that they did not observe an increase in the pain from the beginning of the problem. She did not suffer from nausea, vomiting, diarrhea, constipation, fever or any other complaints. There was no analgesic history. In the physical examination, minimal voluntary guarding was present and no rebound was found. In laboratory, white blood cell count was 18.000 cells per cubic millimeter. Patient was evaluated for appendicitis with ultrasound (US).

US Examinations

US examinations were performed with GE LOGIQ 7 (GE Medical systems, Milwaukee, Wisconsin (WI), USA) equipped with 10 Mhz linear transducer. Our criteria for diagnosis of appendicitis at US were the presence of a non-compressible, thickened (at least 7-mm maximal outer diameter) appendix with or without loss of layers, the presence of appendicolithiasis, and/or the presence of periappendiceal inflammatory changes.

At the first examination, appendix diameter was 16 mm and periappendiceal fat was shown to be thickened (Figure 1a). Doppler US was performed with GE LOGIQ 7 (GE Medical systems, Milwaukee, WI, USA)

equipped with 10 Mhz linear transducer and showed the increased vascularity in the appendiceal wall (Figure 1b). Patient was diagnosed as acute appendicitis but daily US follow-up was programmed without a definitive therapy because of her existing clinical signs.

In the second day of the follow-up, her complaints became less and appendix was measured 9mm in the US evaluation (Figure 1c).

At the third day, US revealed the appendix as 6 mm diameter and longitudinal evaluation showed the normal thickness of the fat and appendicular levels (Figure 2a,2b). Clinical findings correlated with the US examinations.

Patient has been under a control program for 9 months and has not had any suffering for this subject, till then.

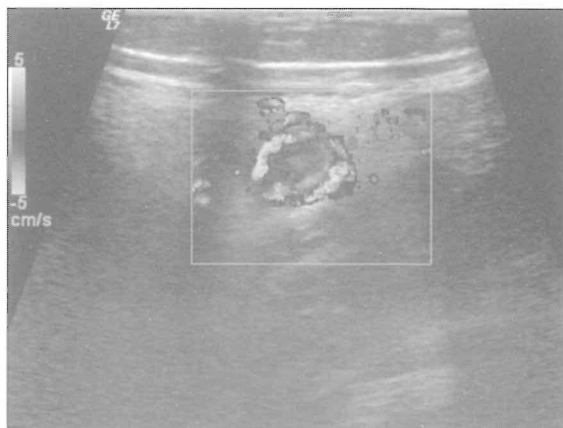

Figure 1b. Transverse Doppler US shows increased vascularity of the appendix.

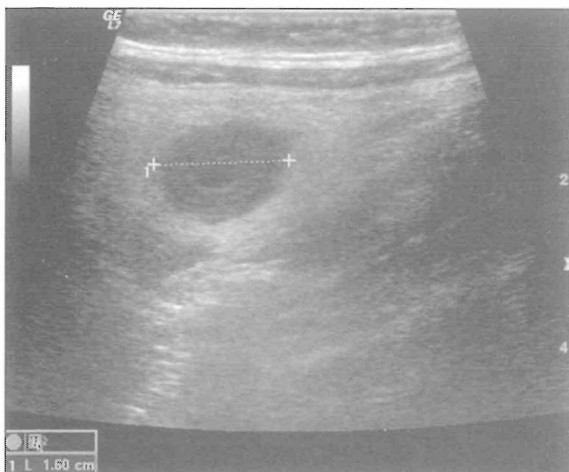

Figure 1a. Transverse US scan shows appendix that is 16 mm in thickness.

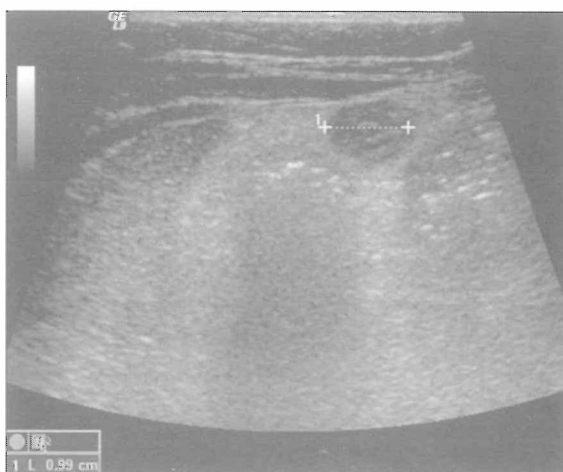

Figure 1c. Transverse US shows 9 mm appendix thickness in the second day.

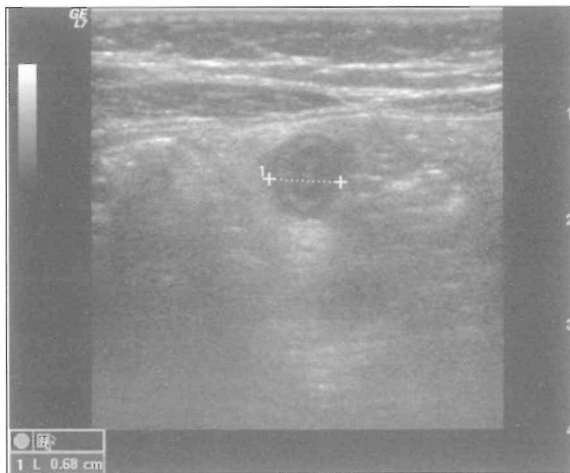


Figure 2a. Transverse US shows 6 mm of appendix in the third day.

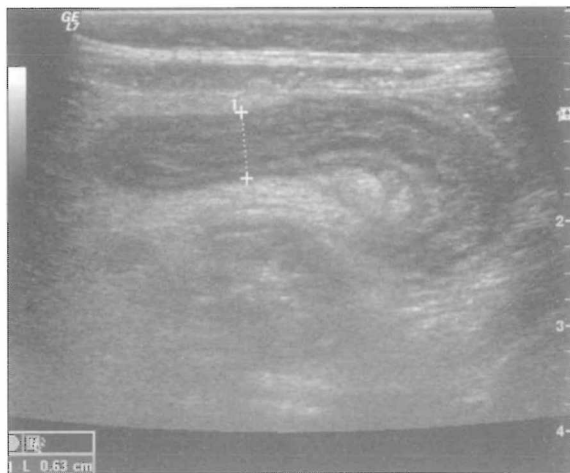

Figure 2b. Longitudinal US evaluation of the appendix in the third day.

DISCUSSION

SRA may simply be defined as acutely inflamed appendix which can be treated conservatively (1). In SRA, inflammation of the appendix may not always overlap with clinical symptoms (2). Cobben et al, reported that the onset of the symptoms was seen in a minority of patients (5). According to Puylaert et al, symptoms of the SRA start in a few hours and decreases within 48 hours (1). Thus, clinical symptoms may be present but the pain attacks may resolve (2). Therefore, the diagnostic evaluation of SRA has to include both with clinical and radiological examinations (2).

US is an effective tool for the diagnosis of acute appendicitis but there are some limitations of the method causing false-positive and false-negative

results (4). In our patient, we cautiously evaluated all the planes of the appendix during the follow-up and decided next step after these careful evaluations. Although physical examination, clinical and sonographic evaluations guided us for appropriate decisions, the most controversial point which originated from the literature was the management policy for SRA. Some authors decide to perform surgery while some others choice conservative treatment. Clinical status of the patient whose appendix appears abnormal at US may be the criterion to decide a surgery (2). An increasing amount of circumstantial evidence suggests that all patients with appendicitis will not progress to perforation and resolution may be a common event (3). Nonetheless, according to the traditional model, surgeons operate the patients with appendicitis as they believe that most of them will eventually progress to perforation if left untreated (3). There are some reasons for this final manipulation. First of all, SRA hasn't been an accepted entity in general, and for over 100 years surgical therapy has been the guiding star for the management of suspected appendicitis (2,3). Another reason for preferring the surgery is the variable symptoms that force surgeons, especially juniors, for a final decision of the patients' situation (8). As it is generally suggested that untreated appendicitis will eventually progress to perforation, junior surgeons decide operations for these patients (3). Another matter of fact is; some surgical textbooks still disregard or refuse the existence of recurrent appendicitis (8). This can also be an important factor to influence the decision of the surgeons for treatment policy.

In another point of view, there may be a clinical difference in morbidity and mortality between the patients who are treated conservatively and operated with the diagnosis of acutely inflamed appendix although their clinical findings improved (1). Operation may be more morbid and/or mortal than the conservative management. Therefore, with the help of the clinical and sonographic evidences, conservative treatment may be preferred at least until the more understanding of SRA was gained (1). Our patient had only a mild right lower abdominal pain that did not even cause a nausea or lack of appetite. We determined appendice inflammation and diagnosed as appendicitis but prefer to wait according to her circumstances and got alerted for a probable alteration in the condition. Patient has been well then and situation has not repeated again. This case encouraged us for conservative treatment for the

patients whose clinical attitude is equal to this patient.

In conclusion, we suggest that this is an important clinical experience that affects our decision algorithm for these patients in the future. By the help of this case, we realized the existence of SRA and get the message that only appendiceal inflammation is not important. Also, as a matter of fact, the patient is the first case of SRA reported from our clinics and from our country and we think that this case may be a sample for the availability of conservative treatment for this region surgeons. Finally, this clinical experience demonstrates that morbidity and mortality will be altered if patients are not operated in vain for a resolving appendicitis.

REFERENCES

1. Puylaert JB, Rijke AM. An inflamed appendix at sonography when symptoms are improving: To operate or not to operate? *Radiology* 1997;205:41-2.
2. Migraine S, Atri M, Bret PM, Lough JO, Hinchey JE. Spontaneously resolving acute appendicitis: Clinical and sonographic documentation. *Radiology* 1997;205:55-8.
3. Andersson RE. The natural history and traditional management of appendicitis revisited. Spontaneous resolution and predominance of prehospital perforations imply that a correct diagnosis is more important than an early diagnosis: *World J Surg* 2007;31:86-92.
4. Hahn HB, Hoepner FU, Kalle T, et al. Sonography of acute appendicitis in children: 7 years experience. *Pediatr Radiol* 1998;28:147-51.
5. Cobben LPJ, Otterloo A, Puylaert JB. Spontaneously resolving appendicitis: Frequency and natural history in 60 patients. *Radiology* 2000;215:349-52.
6. Savrin RA, Clausen K, Martin EW, Cooperman M. Chronic and recurrent appendicitis. *Am J Surg* 1979;137:355-7.
7. Kessler N, Cyteval C, Gallix B, et al. Appendicitis: Evaluation of Sensitivity, Specificity, and predictive values of US, Doppler US, and laboratory findings. *Radiology* 2004;230:472-8.
8. Barber MD, McLaren J, Rainey JB. Recurrent appendicitis. *Br J Surg* 1997;84:110-2.