



Association of Carcinoma of the Breast and Meningioma: Report of a Case and Review of the Literature

Meme Kanseri ve Menenjiom İlişkisi: Olgu Sunumu ve Literatürün Gözden Geçirilmesi

Yasemin BENDERLİ CİHAN¹, Figen ÖZTÜRK²

¹ SB Kayseri Eğitim ve Araştırma Hastanesi, Radyasyon Onkoloji Bölümü,

² Erciyes Üniversitesi Tıp Fakültesi, Patoloji Anabilim Dalı, KAYSERİ

SUMMARY

The incidence of meningioma shows a recent increase in patients with breast cancer. The increased risk of developing meningioma was reported to be 1.57-1.90 times after breast cancer. Carcinoma of the breast is the second most common cause of intracranial metastases (after carcinoma of the lung). It is therefore important to differentiate a solitary brain metastasis from a meningioma. A review of the literature was presented with emphasis on the association between breast cancer and meningioma, which indicates a possible hormonal relationship. In this paper we report a case of meningioma which subsequently developed in a patient with primary breast carcinoma.

Key Words: Breast cancer, menengioma, cranial metastases.

ÖZET

Meme kanserinde menenjiom görülme riski 1.57-1.90 kat daha fazladır. Meme kanseri akciğer kanserinden sonra ikinci sıklıkta beyine metastaz yapan tümördür. Bundan dolayı, menenjiomun metastaz ile ayırt edilmesi önemlidir. Bu iki hastalık hormona duyarlı olmasından dolayı birlikte görülebileceğinden takip yaparken diğeri ile karşılaşabileceği düşünülmelidir. Bu yazıda, meme kanseri tanısı ile takip edilen hastada gelişen menenjiomun meme kanseri ile olası ilişkisi incelendi.

Anahtar Kelimeler: Meme kanseri, menenjiom, beyin metastazı.

INTRODUCTION

The incidence of meningioma shows a recent increase in patients with breast cancer (1). The increased risk of developing meningioma is reported to be 1.57-1.90 times after breast cancer according to data from Swedish Cancer Registry and from the United States Surveillance, Epidemiology and End Results (SEER) program (2). It is important to differentiate a solitary brain metastasis from a meningioma. A hormonal re-

lationship between meningioma and brain cancer has also been suggested (3,4). The menstrual cycle and/or pregnancy may be related to the rapid increase of meningiomas (5). In this paper we report a case of meningioma which subsequently developed in a patient with primary breast carcinoma. Knowledge of this association is important in the differential diagnosis of patients with breast cancer who develop central nervous manifestations.

CASE REPORT

On January 2005, a 50-year-old woman presented complaining of a right sided (in the upper-external quadrant) breast lump. After radical mastectomy, pathological diagnosis confirmed an invasive duct carcinoma, histological Grade III, 7/19 lymph node metastases (Figure 1). Hormonal assessment of the tumor revealed it to be both ER and PR receptor strongly positive (Figure 2). Positive p53 nuclear immunoreactions and strongly positive Her-2 over expression by immunohistochemically staining were observed. Extension studies showed no evidence of metastatic disease.

Our patient received four cycles of adjuvant chemotherapy with cyclophosphamide 600 mg/m², methotrexate 40 mg/m², 5-Fluorouracil 600 mg/m² every 21 days. The patient received a five-week course of radiotherapy and continuously received treatment by tamoxifen of recent.

Three years later, in February 2008 the patient complained of recent headache, nausea and vomiting. She showed no symptoms or signs at that time. MRI demonstrated on intensely enhancing extra-axial dural based lesion. Post contrast axial (a) FS T1W1 showed an intensely enhancing extra-axial dural-based lesion in the left cerebellopontine angle, (b) in addition a second lesion was also seen at the posterior falx (Figure 3). No other metastatic lesion was detected by abdominal ultrasound examination or chest X-ray. Tumor markers (CEA, Ca15-3) were all within normal ranges.

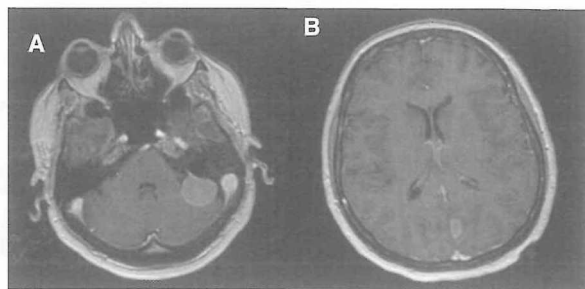


Figure 3. Postcontrast axial (A) FST1WI show an intensely enhancing extra-axial dural based lesion in the left cerebellopontine angle. A small lesion is also seen at the posterior falx (B).

The MRI findings suspected meningioma. However, there was a possibility of solitary brain metastases. MRI demonstrated a circumscribed lesion in left cerebella pontine and falx. The lesion was excised successfully in our case.

Histologically, the brain tumor was composed of spindle cell proliferation and increasing collagen bundles. It was a transitional type benign meningioma (Figure 4). ER was positive, PR was weakly positive also in this tumor (Figure 5). The patient made a good recovery after the initial surgery for breast cancer.

DISCUSSION

It has been reported that breast cancer is the second most common cause of intracranial metastasis (4). Therefore, patient who has symptoms and shows signs suggesting a space-occupying lesion of the

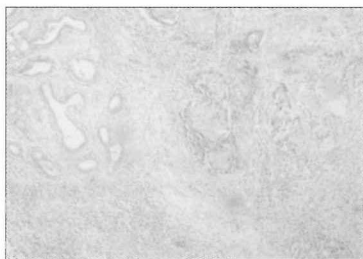


Figure 1. Histopathological examination of the right breast tumor.




Figure 4. Histopathological examination of the brain tumor.

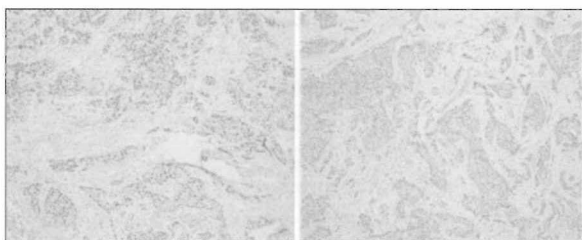


Figure 2. Immunohistochemical examination of the right breast cancer by PR and ER.

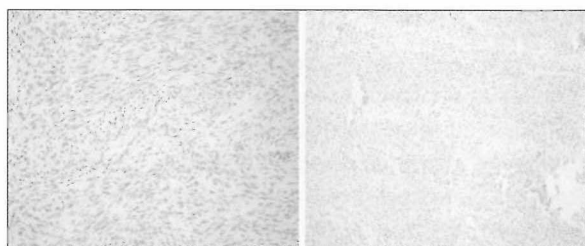


Figure 5. Immunohistochemical examination of the meningioma by PR and ER.

central nervous system after the diagnosis is usually presumed to have metastatic (3). Although, there are many exceptions such as a chronic subdural hematoma, cerebrovascular disease, carcinomatous meningitis and primary tumors of the brain including meningiomas may simulate metastases to the brain (4).

It is important to differentiate a CNS metastasis from a meningioma. Computed tomography (CT), MRI and angiography may be useful diagnostic imaging modalities for this type of tumor (3,4,6,7). A tumor is homogeneously enhanced in MRI image; whereas a metastatic tumor is not homogeneously enhanced. Meningiomas are dural based, well circumscribed, extra-axial mass displacing the brain. Intense homogeneous contrast enhancement is seen after intravenous contrast administration.

The unique association of carcinoma of the breast cancer with meningioma was first pointed in 1975 (1). As noted by Jacops and co-workers, there are some interesting similarities between meningioma and breast and genital cancer (8). They each occurred more frequently in women and occurred most commonly in the fifth and sixth decade. They pointed out that meningiomas are benign, curable and account for as many as 20% of all cerebral tumors. 10% of patients with stage IV breast cancer demonstrated brain metastases. Cerebral meningioma required craniotomy, while breast cancer metastases were probably best treated with surgery, radiation therapy and chemotherapy.

Many case reports will be required to clarify the hormonal association between breast cancers and meningiomas (1,4,8). The relationship between pregnancy and the menstrual cycle and rapid progression of symptoms in patients with meningiomas is well known. There is general agreement that these tumors enlarge during pregnancy (8).

Estrogen and progesterone receptor in meningiomas has been proved (9-11). Some of the meningiomas were reported to express more than estrogen. While Donnell et al. noted an increase in ER receptor protein in intracranial meningioma (10). Tilzer et al. reported large amounts of PR receptors for this nervous system tumor (11).

Rona et al. reported that 64% of 33 meningiomas examined some level of progesterone receptor messenger RNA expression with which the immunohistochemistry data correlated well (12). Blankenstein et al. reported estrogen receptor was independent expression of progesterone receptor in human meningioma (13).

The resected meningioma in this report expressed weakly positive PR in spite of just like the hormone receptor status of the primary breast cancer in the present patient. Patients with a history of breast cancer, intracranial masses with radiological features consist of meningioma should be evaluated surgically. The lesion in the brain may be a meningioma or a metastatic lesion. As we reported here, a patient who has symptoms and signs suggesting a space-occupying lesion of the cranial nervous system after treatment for breast cancer does have not always brain metastases.

REFERENCES

1. Schenberg BS, Christine BW, Whisnant JP. Nervous system neoplasms association and primary malignancies of other sites. The unique association between meningiomas and breast cancer. *Neurology* 1975; 25:705-21.
2. Ahsan H, Neugut AI, Bruce J. Association on malignant brain tumors and cancers of other sites. *J Clin Oncol* 1995; 13:2931-5.
3. Rubinstein AB, Schein M, Reichenthal E. The Association of carcinoma of the breast with meningioma. *Surgery Gynecology and Obstetrics* October 1989; 16:334-6.
4. Smith FP, Slavik M, Macdonald JS. Association of breast cancer with meningioma. *Cancer* 1978; 42:1992-4.
5. Bickerstaff E, Small R, Guest IA. The relapsing course of certain meningiomas in relation to pregnancy. *J Neurol Neurosurg Psychiatry* 1958; 21:89-91.
6. Markopoulos CH, Sampalis F, Givalos N, Gogas H. Association of breast cancer with meningioma. *Eur J Surg Oncol* 1998; 24:332-4.
7. Michelsen JJ, New PJ. Brain tumor and pregnancy. *J Neurol Neurosurg Psychiatry* 1969; 32:305-7.
8. Goffin J. Estrogen and progesterone receptors in meningiomas. Review article *Clin Neurol Neurosurg* 1986; 88:169-75.
9. Jacops D, McFarlane MJ, Holmes FF. Female patients with meningioma of the sphenoid ridge and additional primary neoplasms of the breast and genital tract. *Cancer* 1987; 60:3080-2.
10. Donnell MS, Meyer GA, Donegan WL. Estrogen-receptor protein in intracranial meningiomas. *J Neurosurgery* 1979; 50:499-502.
11. Tilzer LL, Plapp FV, Evans JP, Stone D, Alward K. Steroid receptor proteins in human meningiomas. *Cancer* 1982; 49:633-6.
12. Rona SC, Danuta G, Kathleen D, Peter MB. Progesterone receptor expression in meningiomas. *Cancer Res* 1993; 53:1312-6.
13. Blankenstein MA, Koehorst SG, van der Kallen CJ, Jacops HM, van Spiel AB, Donker GH, et al. Estrogen receptor independent expression of progestin. *Biol Chem Mol Biol* 1995; 53:361-5.