



Research Article

Pathomorphological Changes and Immunohistochemical Distribution of Border Disease Virus Antigen in Non-Nervous Tissues of Naturally Infected Fetal and Neonatal Small Ruminants

Nihat Toplu¹, Tuba Çiğdem Oğuzoğlu², Hamdi Avcı¹, Erkmen Tuğrul Epikmen¹

¹Department of Pathology, Faculty of Veterinary Medicine, University of Adnan Menderes, Aydın, Turkey.

²Department of Virology, Faculty of Veterinary Medicine, University of Ankara, Turkey.

ABSTRACT

The present study describes the pathological changes, immunohistochemical distribution of the viral antigen and RT-PCR diagnosis in Border disease. Abortions and births of lambs and kids with poor survival rate and abnormal fleece with long and straight birth coats (hairy shaker) have been observed. Histopathologic lesions in thymus, spleen and lymph nodes included marked depletion of lymphocytes of follicular areas as well as reticuloendothelial cell hyperplasia and sinusoids were dilated and filled with macrophages. The lungs had interalveolar interstitial pneumonia characterized by infiltration of mononuclear cells and proliferation of pneumocytes in the interalveolar tissue. In five cases, the heart exhibited characteristics of focal nonsuppurative interstitial myocarditis and epicarditis. Lesions in the small intestines were consisted of edema and infiltration of the lamina propria mucosa with mononuclear cells. Immunohistochemistry demonstrated Border disease viral antigen labeling in the lungs (9/23), myocardium (7/23), tongue (5/20), skin (3/15), intestines (10/23), kidneys (6/23), urinary bladder (2/15), spleen (5/23), thymus (8/20), lymph nodes (6/23), tonsils (5/20) and liver (6/23). A 288 bp gene product of Border disease virus was amplified by the reverse transcriptase-polymerase chain reaction (RT-PCR) in RNA samples isolated from the lymph nodes and spleen of lambs and kids.

Keywords: Pestivirus, Border Disease, Immunohistochemistry, Lamb, Kid.

Border Hastalığı Virusü ile Doğal Enfekte Fötal ve Neonatal Küçük Ruminantların Non-Nervöz Dokularında Patomorfolojik Değişiklikler ve Viral antijenin İmmunohistokimyasal Dağılımı

ÖZET

Sunulan çalışma Border hastalığında patolojik değişiklikler, viral antijenin immunohistokimyasal dağılımı ve ters transkriptaz-polimeraz zincir reaksiyonu (RT-PCR) ile moleküler tanısını kapsamaktadır. Toplam 23 olguda, klinik olarak abort, yaşama gücü zayıf yavru doğumları ile anormal yapağı örtüsü (hairy shaker) gözlenmiştir. Histopatolojik olarak timus, dalak ve lenf yumrularında lenfoid foliküllerde boşalma, retikuloendotelial hücre hiperplazisi ile sinüzoidlerin makrofajlar ile dolu olduğu belirlendi. Akciğerlerde interalveolar interstisyel pnömoni tanımlandı. Beş olgunun kalp dokusunda nonsuppuratif myokarditis ve epikarditis gözlemlendi. İnce bağırsaklarda ödem ve mononükleer hücre infiltrasyonları kaydedildi. İmmunohistokimyasal incelemede, viral antijen akciğerler (9/23), kalp kası (7/23), dil (5/20), deri (3/15), bağırsaklar (10/23), böbrekler (6/23), idrar kesesi (2/15), dalak (5/23), timus (8/20), lenf yumruları (6/23), tonsiller (5/20) ve karaciğer (6/23)'de saptandı. RT-PCR ile lenf yumrusu ve dalaklardan Border hastalığını işaret eden Border hastalığı virusunun 5' UTR'ye ait PCR ürünü (288 bp) amplifiye edildi.

Anahtar Kelimeler: Pestivirus, Border Hastalığı, İmmunohistokimya, Kuzu, Oğlak.

Correspondence to: N. Toplu, Adnan Menderes Üniversitesi, Veteriner Fakültesi, Patoloji Anabilim Dalı, 09016 ,Işıklı, Aydın, Türkiye. E-mail: ntoplu@adu.edu.tr

Received: June 14, 2012 / Accepted: December 2, 2012

Introduction

Border disease (BD) is a congenital infectious viral disease affecting sheep and goats and also wild small ruminants, including deer and chamois (Hughes et al., 1959; Löken, 1982; Carlsson, 1991; Garcia-Perez et al., 2009). BD virus (BDV) belongs to the genus *Pestivirus* of the family *Flaviviridae*, closely related to the viruses of Bovine Virus diarrhoea Viruses 1 and 2 (BVDV 1, 2) of cattle and Classical Swine Fever Virus (CSFV) of pigs (Heinz et al., 2000). Since first described in 1959 from the border region of England and Wales, BD has caused morbidity and mortality worldwide and lead to significant economic losses in small ruminant populations (Arnal et al., 2004; De Mia et al., 2005; Thabti et al., 2005; Valdazo-González et al., 2007). Few studies on *Pestivirus* infections in small ruminants in Turkey have been reported (Burgu et al., 2001; Ataseven et al., 2006; Oğuzoğlu et al., 2009; Toplu et al., 2010).

Since 2004, we have encountered clinical cases associated with BD characterized by abortion, stillbirth, and neonatal mortality with nervous signs such as ataxia, tremors, paresis, paralysis and arthrogryposis in small ruminant herds in the Aegean region, Turkey (Toplu et al., 2010). On the postmortal examination, the most striking fetal lesions were porencephalic cysts in the cortex of the cerebral hemispheres, cerebellar hypoplasia, hydranencephaly and hydrocephalus. Histologically, the most conspicuous findings were nonsuppurative meningoencephalomyelitis, often accompanied by hypomyelinogenesis especially in the periventricular areas and occasionally in the spinal cord. Virologic and immunohistochemical and in situ hybridisation analyse indicated that the disease was a pestivirus infection in the lambs and kids. The pestivirus isolated from a twin lambs in the Aegean region was characterized as BDV by sequencing of the gene products derived from a reverse transcriptase-polymerase chain reaction (RT-PCR) testing (Oguzoglu et al., 2009). Phylogenetic analysis using the fragments of the 5'-NTR and N^{pro} of the isolates revealed that the viruses formed a distinct cluster as BDV-7 (Oguzoglu et al., 2009), which is a characteristic of certain geographical regions and similar to the findings for classical swine fever virus. On the other hand, our most recent study showed that phylogenetic analysis of the isolate from the Blacksea region revealed that the virus was identified into subgroup of BDV-3 (Toplu et al., 2012).

In our previous study, BDV's association with apoptosis in the brain tissues were described (Toplu et al., 2010). The aim of the present study was to describe the pathologic changes and distribution of BDV antigen in non-nervous tissues of BDV infected fetal and neonatal small ruminants.

Materials and Methods

Animals

The tissues were collected from a total of 23 lambs and kids with Border disease from 5 different flocks in the

provinces of Aydın and Muğla of the Aegean region. The animals were subjected to necropsy. Following the gross examination, the non-nervous tissues were fixed in 10 % neutral buffered formalin, dehydrated in ethanol and embedded in paraffin wax, sectioned at a thickness of 5 µm and stained with haematoxylin and eosin (HE). Replicated sections were used for immunohistochemistry. Fresh tissue samples of the lymph nodes and spleen of the lambs and kids were examined with RT-PCR for pestiviruses.

RT-PCR

For the detection and differentiation of BDV, RT-PCR was used, essentially as described by Oguzoglu et al., (2009). Briefly, RNA extraction was performed lymph nodes and spleen homogenates from lambs and kids using a High Pure Viral RNA Kit (Roche Diagnostic, Germany) according to the manufacturer's recommendation. Synthesis of cDNA was carried out using random primers (Fermentas, Lithuania). The genomic region encoding the highly conserved 5'-NTR of the pestivirus genome was amplified using panpesti generic primers (324/326; Vilcek et al., 1994), Npro region primers (BD1/BD2; Vilcek and Belak, 1996), type-specific PBD1/PBD2 primers for Border disease virus and for the differential diagnosis of BVDV type 2, respectively (Vilcek et al., 1994). After amplification, DNA products were analyzed in 1% agarose-ethidium bromide gels in Tris-acetate buffer and visualized on a UV transilluminator. The cytopathogenic (cp) Moredun strain of BDV and the noncytopathogenic (ncp) BVDV strain 0712/Hannover were used as positive controls for RT-PCR.

Immunohistochemistry (IHC)

For immunohistochemical analysis, the avidin-biotin peroxidase complex method (ABC, DacoCytomation, Denmark) were used. Tissue sections (5 µm) were placed on poly-L-lysine-coated glass slides. After incubation for 2h at 40°C, the sections were dewaxed in xylene and hydrated through graded alcohols. The tissues were previously digested with 0.1 % protease K for 10 min. at 37°C and the slides were washed for 10-15 min. in phosphate buffered saline (PBS) pH 7.3. Endogenous peroxidase was quenched with H₂O₂ 3% in 70% methanol and the non specific staining was blocked by treatment with 2% normal goat serum for 10 min. Then, the blocking serum was replaced by primary antibodies (monoclonal antibodies against mouse anti-pestiviruses group specific antigen (WB103/105 nonstructural protein 2-3, CVL, PA0801) and mouse anti-BDV specific antigen (WS363 envelope rns, CVL, PA0825)) were used, followed by an overnight incubation at 4°C. After washing in PBS for 10 min., the sections were flooded with biotinylated goat anti-mouse immunoglobulin for 10 min. After a further PBS wash, the sections were covered with streptavidin-peroxidase and incubated for 10 min. Finally, they were treated for 10-15 min. with 3,3'-Diaminobenzidine (DAB) in H₂O₂ chromogen. The sections were then counterstained with Mayer's haematoxylin, washed in tap water, dehydrated in graded alcohols, and mounted. For control purposes, replicate sections of selected

infected tissues were processed, substituting normal mouse serum for mouse anti-pestivirus serum. Unless stated otherwise, all incubations were performed at room temperature in a humidified chamber.

Data Analysis of IHC Results

The scores of IHC were appointed on the basis of positively stained cells observed in 10 different areas under the 40X microscope objective. The scores were as follows: - (0+): absent; (1+): weak immunopositivity (1-3% positive cells); (2+): moderate immunopositivity (4-9% positive cells); (3+): strong immunopositivity (>10% positive cells).

Results

Necropsy Findings

The dominant gross lesions in the non-nervous tissues were thymic hypoplasia and abnormal fleece with long and straight birth coats called as "hairy shaker" (Figure 1). The tonsils and lymph nodes were edematous and enlarged, some of which were hemorrhagic. In two lambs (case nos. 2 and 3), there were petechial hemorrhages on the lateral and ventral surfaces of the tongue. The intestinal lesions consisted of a diffuse congestion, the contents of which were often fluid in newborn lambs and kids. Two lambs (case nos. 22 and 23) had erosive-ulcerative lesions with hemorrhages in the oral and intestinal mucosa. In three animals (case nos. 1, 22 and 23), the cranial lobes of the lung had small or extensive dark red areas of hepatisation and emphysema with leakage of yellowish fluid from the cut surface. In three lambs (case nos. 2, 3 and 15), there were petechial hemorrhages in the mucosa of the urinary bladder.

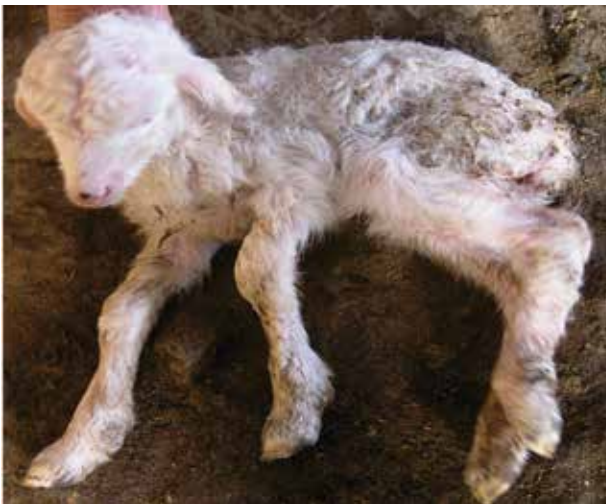

Figure 1. BDV infected lamb with paralysis and hairy shaker.
Şekil 1. BDV enfekte bir kuzuda paraliz ve düzensiz yapağı örtüsü.

RT-PCR

Tissue samples of the lymph nodes and spleen were positive for pestivirus by RT-PCR using panpesti generic primers flanking a 288 bp DNA fragment. Additionally,

the samples were tested using primers BD1/BD2 for N^{pro} region and PBD1/PBD2, which discriminate between BDV and BVDV-2, amplifying 738 bp, 225 bp and 106 bp fragments, respectively. The RT-PCR exhibited the expected sizes of 225 bp DNA products for BDV (Figure 2).

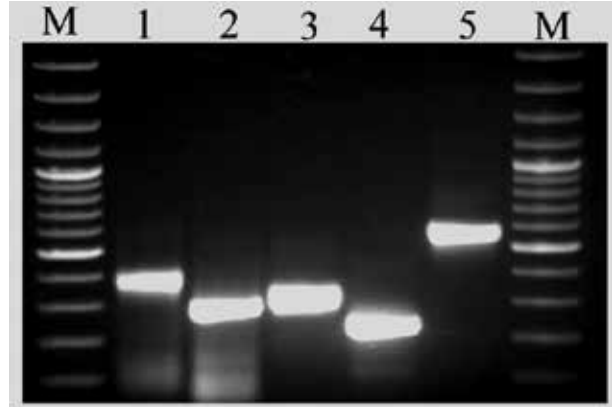


Figure 2. Electrophoresis of RT-PCR products. **1:** DIG labeled prob achieved from PCR Product of panpesti generic primer pairs, **2:** DIG unlabeled control prob achieved from PCR Product of panpesti generic primer pairs, **3:** DIG labeled prob achieved from PCR Product of Border Disease specific primer pairs, **4:** DIG unlabeled control prob achieved from PCR Product of Border Disease specific primer pairs, **5:** tPA control prob, **M:** Marker 100 bp (Fermentas).

Şekil 2. RT-PCR ürünlerin elektroforezisi. **1:** Panpesti generik primer çiftlerinden elde edilen DIG-işaretli prob. **2:** Panpesti generik primer çiftlerinden elde edilen DIG-işaretsiz prob. **3:** Border hastalığı spesifik primer çiftlerinden elde edilen DIG işaretli prob. **4:** Border hastalığı spesifik primer çiftlerinden elde edilen DIG işaretli prob. **5:** tPA kontrol prob, **M:** Marker 100bp.

Histopathological Findings

In the skin, a high proportion of the primary follicles was enlarged with conspicuously larger medulla. In some animals (case nos. 2, 3, 4 and 9), there were slight perivascular infiltrations and scattered macrophages and lymphocytes in subepithelial areas of the skin. In the thymus, there was a marked depletion of lymphocytes in follicular areas, hyperplasia of reticuloendothelial cells and sinusoids dilatation with macrophages. Similar lesions were observed in the spleen, tonsils, mesenteric and retropharyngeal lymph nodes. In many cases (12/23), the lungs showed interalveolar interstitial pneumonia characterized by infiltration of mononuclear cells and proliferation of pneumocytes in the interalveolar tissue. In five cases (case nos. 1, 5, 6, 16 and 20), the heart showed focal nonsuppurative interstitial myocarditis and epicarditis. In the liver, there were multifocal areas of coagulative necrosis, vacuolisation of hepatocytes, perivascular mononuclear infiltration in the portal areas, and lymphoid aggregations including macrophages within parenchyma. The kidneys (7/23) had hemorrhagic areas in the renal cortex and medulla. Lesions in the small intestines were consisted of diffuse edema of the submucosa, and infiltration of the lamina propria with

Table 1: Immunohistochemical distribution of BDV antigen in the tissues of naturally infected animals.**Tablo 1.** Doğal enfekte hayvanların dokularında BDV viral antijenlerin immunohistokimyasal dağılımı.

Case nos	Age	IHC with WS363 primer antibody				
		Lymh Nodes	Spleen	Intestines	Lungs	Heart
1	3 d	2+	2+	1+	2+	3+
2	2 d	1+	1+	2+	1+	0+
3	2 d	2+	1+	1+	2+	2+
4	Fetus	3+	3+	0+	2+	2+
5	1 d	2+	2+	0+	3+	3+
6	Fetus	0+	0+	0+	1+	2+
7	Fetus	1+	0+	1+	1+	0+
8	3d	2+	2+	1+	3+	0+
9	Fetus	0+	0+	0+	1+	1+
10	Fetus	1+	0+	0+	1+	2+
11	Fetus	2+	1+	1+	2+	2+
12	1 d	1+	0+	0+	3+	0+
13	Fetus	2+	1+	0+	2+	2+
14	Fetus	0+	1+	0+	1+	0+
15	1d	2+	2+	1+	3+	0+
16	1 d	2+	3+	0+	3+	3+
17	1d	2+	2+	0+	2+	2+
18	1 d	2+	2+	1+	2+	0+
19	2d	3+	3+	2+	3+	2+
20	2 d	2+	1+	0+	2+	3+
21	2 d	1+	1+	1+	1+	0+
22	15 d	2+	2+	2+	3+	1+
23	90 d	2+	1+	2+	3+	0+

D: day; (0+): absent ; (1+): weak immunopositivity; (2+): moderate immunopositivity; (3+): strong immunopositivity

mononuclear cells. The Peyer's patches had lymphoid depletion and reticuloendothelial cell hyperplasia.

Distribution of Viral Antigens in the Tissues

The ABC method showed that there was a good correlation in respect to the intensity and distribution between pestiviruses group specific antigen (WB103/105) and BDV specific antigen (WS363) in non-nervous tissues. Immunolabeling intensity and distribution of BDV antigen are represented in Table 1.

An intense immunolabeling of viral antigens was detected in epithelial lining cells of the bronchi and bronchioles as well as alveolar macrophages, mononuclear cells and pneumocytes in interstitium of the lungs (9/23) (Figure 3a). In the myocardium (7/23), myocytes exhibited granular and linear patterns of viral antigens (Figure 3b). In the tongue (5/20), a moderate to severe immunolabeling was found in epithelial cells of the mucosa, infiltrating macrophages in the propria, and occasionally in myocytes of the muscular layer (Figure 3c). The skin (3/15) showed light immunolabeling in epithelial cells of the mucosa and in infiltrating macrophages of the submucosa. In the intestines (10/23), a slight to moderate immunolabeling was seen in epithelial cells of the crypts and in mononuclear

cells of the lamina propria. A moderate to strong immunolabeling of viral antigen was present in epithelial cells of the renal tubules and renal pelvis (6/23) and occasionally in epithelial cells of the urinary bladder (2/15). In the spleen (5/23), thymus (8/20), lymph nodes (6/23) and tonsils (5/20), the immunolabeling was localized to sinusoidal macrophages and reticular cells. In the liver (6/23), the labeling of viral antigens was evidenced in hepatocytes and Kupffer cells and rarely in infiltrated cells. No immunolabeling was observed in the negative control slides (Figure 3d).

Discussion

As described in the present study, intrauterine infections with BDV in small ruminants can result in fetal death with resorption, mummification, abortion, stillbirths, brain malformations, intrauterine growth retardation and birth of unviable (Depner et al., 1990; Bielefeld-Ohmann et al., 2008; Garcia-Perez et al., 2009). Infected lambs can display common findings including "small weak with ataxia or paralysis, a variety of malformations including abnormally hairy fleece (so-called 'hairy-shaker' or 'fuzzy' lambs syndrome)" (Hewicker-Trautwein and Trautwein, 1994; Scherer et al., 2001; García-Pérez et al., 2009). However, gross lesions with porencephaly, hydranencephaly, hydrocephalus,

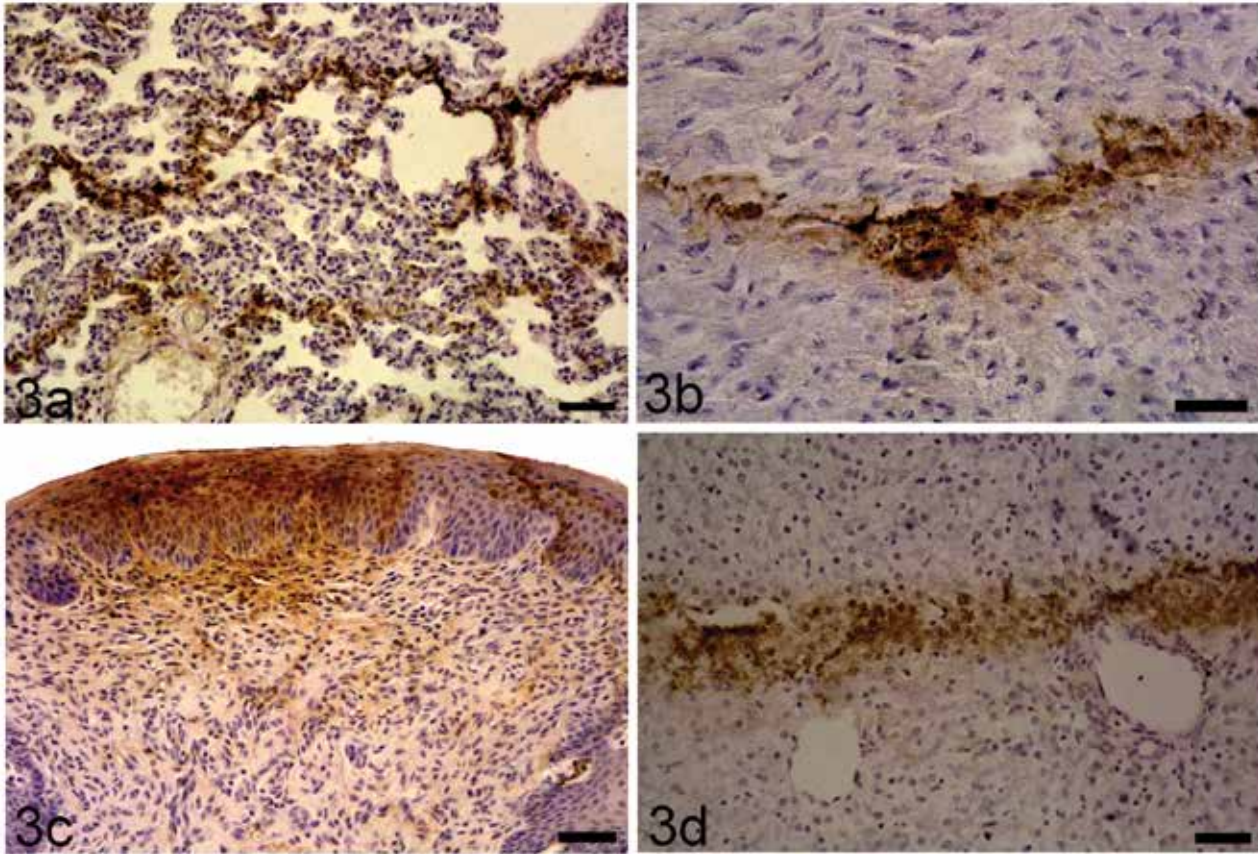


Figure 3. a) Immunolabeling of BDV antigen in alveolar epithelial cells and interstitial cells of the lung. IHC with anti-pestivirus group specific antigen. Bar=50 μ m. b) Granular and linear labellings of viral antigens in myocytes of the cardiac muscle. IHC with anti-pestivirus group specific antigen. Bar=50 μ m. c) Immunolabelling of the BDV antigen in epithelial cells and fibrocytes in the tongue. IHC with anti-BDV specific antigen. Bar=50 μ m. d) The viral antigen labeling of hepatocytes and Kupffer cells in the liver. IHC with anti-BDV specific antigen. Bar=50 μ m.

Şekil 3. a) Akciğerde alveol epitellerinde BDV immunpozitif reaksiyonlar. b) Kalp kasında BDV immunpozitif reaksiyonlar. c) Dilde epitel hücreleri ve fibrositlerde BDV immunpozitif reaksiyonlar. d) Karaciğerde hepatosit ve Kupffer hücrelerinde BDV antijen pozitifliği.

and cerebellar hypoplasia are usually ascribed to blue tongue virus infection especially in the Aegean region, Turkey. The lesions described in the non-nervous tissues were consisted of nonsuppurative inflammatory reactions, which are not specific findings for BD. Moreover, less frequently, persistently infected two lambs of the present cases showed erosive-ulcerative lesions with haemorrhage in the digestive system as unusual signs, which has some features analogous to the experimentally produced mucosal disease-like lesions (Monies et al., 2004). Such cases also need to be distinguished from peste des petits ruminants, which has frequently been observed in Turkey since 1993 (Alcigir et al., 1996; Toplu et al., 2004; Toplu et al., 2012). Thus, diagnosis of BD may be difficult because of the wide variability of clinical signs, gross and histologic lesions. Therefore, immunolabelling of pestivirus viral antigen and amplification of the viral genome were essential to clarify the differential diagnosis.

Historically, all small ruminant pestivirus isolates have been referred to as BDV, (Löken, 1982; Carlsson, 1991), because the differentiation between ovine and bovine pestiviruses can be difficult due to the fact that both BVDVs and BDV are closely related serologically and

often cross-neutralize with each other, furthermore both viruses can infect sheep, goats and cattle, and cause similar pathologic changes in CNS (Depner et al., 1990; Carlsson, 1991; Löken et al., 1991; Pratelli et al., 1999; Scherer et al., 2001; Bielefeldt-Ohmann et al., 2008). In the same manner, CNS inflammation characterized by nonsuppurative and/or necrotising meningoencephalomyelitis with hypomyelinogenesis is one of the most striking histological changes in small ruminants infected by BDV and BVDVs (Wohlsein et al., 1992; Pratelli et al., 1999; Scherer et al., 2001; Lamm et al., 2009; Toplu et al., 2010). Therefore, BDV needs differentiation from BVDVs. RT-PCR used in the present study has lead to a better discrimination between pestiviruses (Vilcek and Paton, 2000; Thabti et al., 2005; Oguzoglu et al., 2009). Moreover, Toplu et al. (2010) have developed in situ hybridization method to detect BDV RNA in formalin-fixed, paraffin embedded tissue specimens using a DIG-labelled cDNA probe. Such an advantage of this molecular method to RT-PCR allows localization and detection of BDV nucleic acid sequences in the tissue sections.

In the present study, the results of ABC method demonstrated that BDV antigens in non-nervous tissues

was predominantly localized in the lymph nodes, thymus, spleen, lung, cardiac myocytes, intestines, liver, kidneys and, to a lesser extent, in skin and urinary bladder. The ABC method was a practical and applicable diagnostic tool for detection and discrimination of BDV. Also, IHC may propose some advantages in detection of BDV according to other methods such as immunofluorescein, and RT-PCR. These advantages include direct visualization of antigens in infected tissues, use of ordinary light microscopy, and simultaneous observation of histopathologic changes (Jung et al., 2002). Based on our laboratory results, IHC is a useful method for detection and differentiation of BDV in tissues taken from naturally infected lambs and kids, and may be a valuable technique for studying the pathogenesis in BDV infection.

References

- Alcigir G, Vural S and Toplu N (1996). Erste pathomorphologische und immunhistologische beschreibung der peste des petits ruminants bei den lammern in der Türkei. Ankara Universitesi Veteriner Fakültesi Dergisi, 43, 181-189.
- Arnal M, Fernandez-de-Luco D, Riba L, Maley M, Gilray J, Willoughby K, Vilcek S and Nettleton PF (2004). A novel pestivirus associated with deaths in Pyrenean chamois (*Rupicapra pyrenaica pyrenaica*). *Journal of General Virology*, 85, 3653-3657.
- Ataseven VS, Ataseven L, Tan T, Babür C and Oguzoglu TC (2006). Seropositivity of agents causing abortion in local goat breeds in Eastern and South-eastern Anatolia, Turkey. *Revue de Médecine Vétérinaire*, 157, 545-550.
- Bielefeldt-Ohmann H, Tolnay AE, Reisenhauer CE, Hansen TR, Smirnova N and Van Campen H (2008). Transplacental Infection with Non-Cytopathic Bovine Viral Diarrhoea Virus Types 1b and 2: Viral Spread and Molecular Neuropathology. *Journal of Comparative Pathology*, 138, 72-85.
- Burgu I, AkçaY, Alkan F, Özkul A, Karaoğlu, T Bilge-Dağalp S., OğuzoğluTC and Yeşilbağ K (2001). The serological and virological investigations and pathogenesis of BVDV infection in sheep during pre- and post-partum periods. *Turkish Journal of Veterinary Animal Science*, 4, 551-558.
- Carlsson U (1991). Border disease in sheep caused by transmission of virus from cattle persistently infected with bovine virus diarrhoea virus. *The Veterinary Record*, 16, 145-147.
- De Mia GM, Greiser-Wilke I, Feliziani F, Giammarioli M and De Giuseppe A (2005). Genetic characterization of a caprine pestivirus as the first member of a putative novel pestivirus subgroup. *Journal of Veterinary Medicine B*, 52, 206-210.
- Depner, KR, Hubschle OJ and Liess B (1990). Transplacental BVD virus transmission after experimental inoculation of goats in different pregnancy stages. *Deutsche Tierärztliche Wochenschrift*, 97, 421-423.
- Garcia-Perez AL, Minguñon E, Estevez L, Barandika JF, Aduriz G, Juste RA and Hurtado A (2009). Clinical and laboratorial findings in pregnant ewes and their progeny infected with Border disease virus (BDV-4 genotype). *Research in Veterinary Science*, 86, 345-352.
- Heinz FX, Collett MS, Purcell RH, Gould EA, Howard CR, Houghton M, Moormann RJM, Rice CM and Tiehl H-J (2000). "Family Flaviviridae" Virus Taxonomy, Seventh Report of the International Committee on Taxonomy of Viruses Academic Press, San Diego.
- Hewicker-Trautwein M and Trautwein G (1994). Porencephaly, hydranencephaly and leucoencephalopathy in ovine fetuses following transplacental infection with ovine virus diarrhoea virus: distribution of viral antigen and characterization of cellular response. *Acta Neuropathologica*, 87, 385-397.
- Hughes LE, Kerschaw GP and Shaw IG (1959). "B" or Border Disease. *The Veterinary Record*, 71, 313-317.
- Jung T, Choi C, and Chae C (2002). Localization of Swine Influenza Virus in Naturally Infected Pigs. *Veterinary Pathology* 39:10-16.
- Lamm CG, Broaddus CC and Holyoak GR (2009). Distribution of bovine viral diarrhoea virus antigen in aborted fetal and neonatal goats by immunohistochemistry. *Veterinary Pathology*, 46, 54-58.
- Löken T (1982). Border disease in goats in Norway. *Research in Veterinary Science*, 33,130-131.
- Löken T, Krogsrud J and Bjerkas I (1991). Outbreaks of Border disease in goats induced by a pestivirus-contaminated orf vaccine with virus transmission to sheep and cattle. *Journal of Comparative Pathology*, 104, 195-209.
- Monies RJ, Paton DJ and Vilcek S (2004). Mucosal disease-like lesions in sheep infected with Border disease virus. *The Veterinary Record*, 155, 765-769.
- Oguzoglu TC, Tan MT, Toplu N, Demir AB, Bilge-Dagalp S, Karaoglu T, Ozkul A, Alkan F, Burgu I, Haas L and Greiser-Wilke I (2009). Border disease virus (BDV) infections of small ruminants in Turkey: A new BDV subgroup? *Veterinary Microbiology*, 135, 374-379.
- Pratelli A, Bollo E, Martella V, Guarda F, Chiocco D and Buonavoglia C (1999). Pestivirus infection in small ruminants: virological and histopathological findings. *New Microbiology*, 22, 351-356.
- Scherer CF, Flores EF, Weiblen R, Caron L, Irigoyen LF, Neves JP and Maciel MN (2001). Experimental infection of pregnant ewes with bovine viral diarrhoea virus type-2 (BVDV-2): effects on the pregnancy and fetus. *Veterinary Microbiology*, 79, 285-299.
- Thabti F, Letellier C, Hammami S, Pepin M, Ribiere M, Mesplede A, Kerkhofs P and Russo P (2005). Detection of a novel border disease virus subgroup in Tunisian sheep. *Archives of Virology*, 150, 215-229.
- Toplu N (2004). Characteristic and non-characteristic pathological findings in Peste des Petits Ruminants (PPR) of sheep in the Ege district of Turkey. *Journal of Comparative Pathology*, 131, 135-141.
- Toplu N, Oguzoglu TCE, Epikmen T, Aydogan A (2010). Neuropathologic study of border disease virus in naturally infected fetal and neonatal small ruminants and its association with apoptosis. *Veterinary Pathology*, 48, 576-583.
- Toplu N, Oguzoglu TC and Albayrak H (2012). Dual Infection of Fetal and Neonatal Small Ruminants with Border Disease Virus and Peste des Petits Ruminants Virus (PPRV): Neuronal Tropism of PPRV as a Novel Finding. *Journal of Comparative Pathology*,146, 289-297.
- Valdazo-González B, Alvarez-Martínez M and Sandvik T (2007). Genetic and antigenic typing of border disease virus isolates in sheep from the Iberian Peninsula. *Veterinary Journal*, 174, 316-324.
- Vilcek S, Herring AJ, Herring JA, Nettleton PF, Lowings JP and Paton DJ (1994). Pestiviruses isolated from pigs, cattle and sheep can be allocated into at least three genogroups using polymerase chain reaction and restriction endonuclease analysis. *Archives Virology*, 136, 309-323.
- Vilcek S, Belak S (1996). Genetic identification of pestivirus strain Frijters as a border disease virus from pigs. *Journal of Virological Methods*. 60, 103-108.
- Vilcek S and Paton DJ (2000). A RT-PCR assay for the rapid recognition of border disease virus. *Veterinary Research*, 31, 437-445.
- Wohlsein P, Trautwein G, Depner KR, Hübschle OJ and Liess B (1992). Pathomorphological and immunohistological findings in progeny of goats experimentally infected with pestiviruses. *Zentralblatt für Veterinärmedizin*, B, 39, 1-9.