



Short Paper

## Congenital Serous Cysts of the Liver in Cows: 5 Cases

Recai Tunca<sup>1</sup>, Hamdi Avci<sup>1</sup>, Hasan Özen<sup>2</sup>, Ahmet Aydoğan<sup>3</sup>, Erkmén Tuğrul Epikmen<sup>1</sup>

<sup>1</sup>Department of Pathology, Faculty of Veterinary Medicine, Adnan Menderes University, Aydın, Turkey, <sup>2</sup>Department of Pathology, Faculty of Veterinary Medicine, Kafkas University Kars, Turkey, <sup>3</sup>Department of Pathology, Faculty of Veterinary Medicine, Mehmet Akif Ersoy University, Burdur, Turkey

### ABSTRACT

Congenital liver cysts are classified as intrahepatic, serous and multiple cysts in domestic animals. In this case presentation study, gross and histopathologic aspects of congenital liver cysts observed during the routine necropsy examination were described. A total of 5 cases of Holstein breed, 6 and 7 month-old aborted two fetuses and 1, 2, and 3 month-old three calves, were studied. Grossly, the liver had fluctuant structure in the calves. In the aborted fetuses, the cysts were present both in the parietal and visceral surfaces of liver, and partially embedded into the liver parenchyma. In calves, the liver cysts were only present on the diaphragmatic surface and attached to the capsule. Clear, fluctuant and light yellowish colored cyst content was 100-200 ml in the fetuses and 0.5-3 l in the calves. In histopathologic examination, the inner cyst walls were seen to consist of squamous cells, though cuboidal cells were occasionally noted. Based on the observations, the liver cysts seen in these cases were named as congenital serous cysts.

*Keywords: Congenital serous cyst, Liver, Pathological findings.*

## Sığırlarda Konjenital Seröz Hepatik Kistler: 5 Olgu

### ÖZET

Evcil hayvanlarda konjenital karaciğer kistleri intrahepatik, seröz ve multiple kistler şeklinde sınıflandırılır. Bu çalışmada, 6 ve 7 aylık Holştayn ırkı atık fetüsler ile 1, 2 ve 3 aylık Holştayn ırkı buzağılarda nekropside rastlantsal olarak karşılaşılan konjenital karaciğer kistleri tanımlandı. Makroskopik muayenede, fetus ve buzağılarda fluktuan ve kese şeklinde genişlemeler gösteren kistler; atık fetüslerde karaciğerin hem pariyetal hem de visceral yüzünde ve organın paransimine doğru da bir gelişim göstermekteydi. Buzağılarda ise yalnızca diyaframatik yüzde kapsulaya yapışık olarak bulunmakta idi. Fetüslerde kistler, yaklaşık olarak 100-200 ml, buzağılarda ise 0.5-3 l miktarında, berrak, limon sarısı renginde, akışkan bir içerikle doluydu. Histopatolojik incelemede, kistlerin iç yüzlerinin tek katlı yassı epitel hücreleriyle örtülü olduğu görüldü. Bazı alanlarda ise bu hücreler kübik yapıda idi. Bu bulgulara göre tüm olgulardaki konjenital karaciğer kistlerinin seröz kist yapısında oldukları sonucuna varıldı.

*Anahtar Kelimeler: Konjenital seröz kist, Karaciğer, Patolojik bulgular.*

Correspondence to: Recai Tunca, Department of Pathology, Faculty of Veterinary Medicine, Adnan Menderes University, 09016 Isikli- Aydın, Turkey. Email: rtunca@adu.edu.tr

*Received: October 10, 2012 / Accepted: November 12, 2012*

## Introduction

Congenital liver cysts have been described in many domestic animal species (MacLachlan and Cullen, 1995; Newman et al., 2000; Kai et al., 2001). Based on the origin of cysts, they were classified as intrahepatic, multiple and serous cysts (Stalker and Hayes 2007). Intrahepatic congenital cysts have generally clear and serous content and develop from embryological bile ducts (Newman et al., 2002; Stalker and Hayes, 2007). The origin of serous cysts is unclear, however it was stated that they could be the serosal inclusion cysts (Van den Ingh and Rothuizen, 1985). Serous cysts were described in calves, lambs and foals, that are adherent to capsula at the diaphragmatic surface of liver (Stalker and Hayes, 2007). Multiple cysts, which originate from bile ducts, in cats, dogs and pigs were reported (Stebbins, 1989; Stalker and Hayes 2007).

In the present study, gross and histopathologic characteristics of congenital liver cysts that were occasionally observed during the necropsy examination of 5 cases were described.

## Materials and Methods

In this investigation, a total of 5 congenital liver cysts, 2 of aborted fetuses and 3 of calves were studied. Information regarding to the breed, sex, age and location where the cases were spotted are shown in Table 1. Tissue samples of livers and the cystic structures were collected during the necropsy examination, and then processed for 10% buffered formalin fixation and paraffin embedding. Thereafter, serial sections were cut for haematoxylin and eosin (HE) and Masson's Trichrome staining.

## Results and Discussion

Cases of two (Case no 1 and 2) were aborted fetuses, which were brought to routine necropsy examination. Growth retardation was observed in these cases considering the current abortion time. Subcutaneous edema and congestions were noted in various sites

of the bodies. In these fetuses, livers were soft in consistency, blunt-edged and showing a color range from light to dark red. Both livers had cystic structures both on the parietal and visceral surfaces (Figure 1). These cysts were in size of approximately 10% of the livers. They were enclosed by a clear and thin-walled membrane. The cystic structures in the fetuses were also noted to embed into the parenchyma of the liver. The 100 to 200 ml cyst content in fetuses was viscous and light yellowish in color.

Three cases of calves (Case no 3, 4 and 5) were clinically cachectic and anemic. In cases 4 and 5, anorexia and abdominal distention were noted. In case no 5, rumen rupture most probably due to maladministration of stomach tube and septic peritonitis were observed. The peritoneal surfaces especially the adjacent sites to the rupture were covered with scattered fibrinous exudates and the rumen content. The livers in calves were swollen, hard in consistency and dark red in color. In all calves, the cysts were were fluctuant and directed from the main localization to parietal surfaces of the liver. Especially in case no 3, the cysts was attached to the capsule on the diaphragmatic surface, and was outwarded from the surface of the liver (Figure 2). The content of these cysts, 0.5 l in case no 3 and approximately 3 l in case no 4 and 5, was serous and light yellowish to dark red in color.

Histopathologically, dilated blood vessels and sinusoidal congestion were seen in livers of all cases. Focal hemorrhages were also noted in some areas of the liver parenchyma. Hepatocytes located in close approximation to the cysts were atrophic and degenerative. The cyst walls in fetuses were thin and formed in embryonic structure. However, the cyst walls in calves were thick and composed of matured connective tissue which was stained by Masson's Trichrome. The inner surface of the cysts was generally lined by squamous epithelium, however cuboidal cells were occasionally noted in some areas. In case no 1 and 2, cysts with varying size were also detected in the parenchyma of liver (Figure 3).

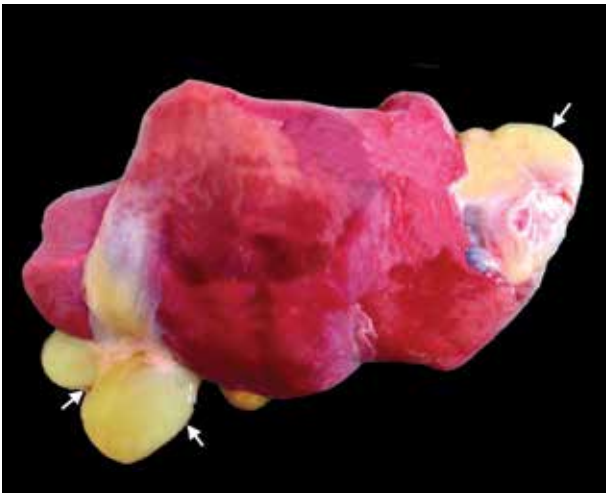


Figure 1. Aborted fetus (Case no 1). Congenital liver cyst on both surface of the liver (arrows).

Şekil 1. Atık fetüs (Olgu no 1). Karaciğerin her iki yüzünde yerleşim gösteren konjenital seröz kist (oklar).

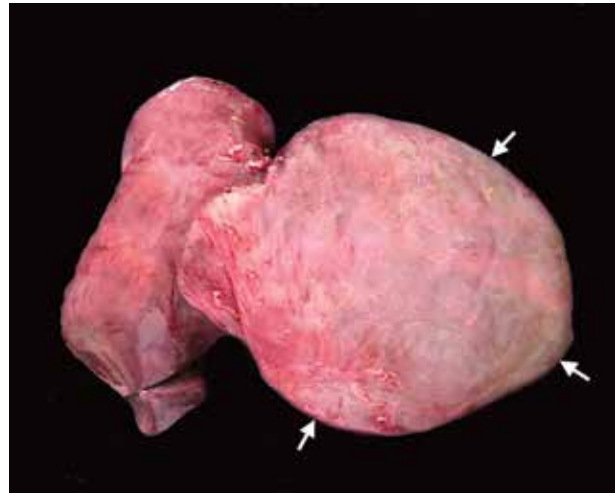
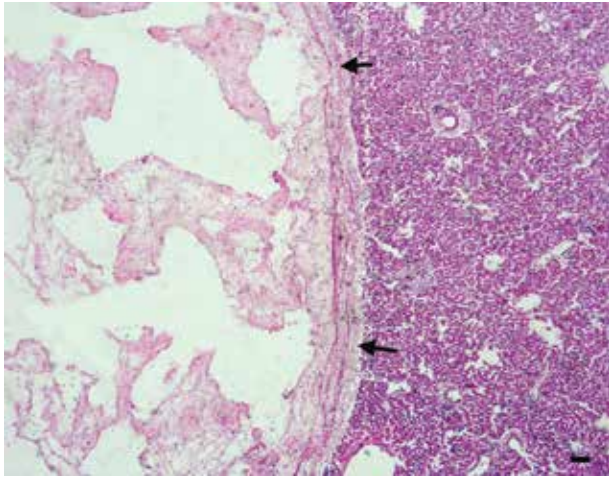


Figure 2. Calf (Case no 3). A congenital serous cyst on diaphragmatic surface of the liver (arrows).

Şekil 2. Buzağı (Olgu no 3). Karaciğerin diafragmatik yüzünde gelişim gösteren konjenital seröz kist (oklar).

**Table 1.** Information regarding to breed, sex, age and location of cases spotted and the clinical findings (-; no clinical finding)  
**Tablo 1.** Olgulara ait ırk, cinsiyet, yaş, tespit edildiği yer ve klinik bulgulara ait bilgiler (-; klinik bulgu yok)

Case No	Breed	Sex	Age	Location	Clinical Findings
1	Holstein	Female	6 months-fetus	Kars	-
2	Holstein	Female	7 months- fetus	Aydin	-
3	Holstein	Female	1 month-calf	Aydin	-
4	Holstein	Female	2 months-calf	Aydin	Abdominal distention
5	Holstein	Female	3 months-calf	Kars	Abdominal distention



**Figure 3.** Calf (Case no 1). Histopathologic appearance of the congenital liver cyst (arrows). HE. Bar = 100 µm.

**Şekil 3.** Buzağı (Olgu no 1). Konjenital karaciğer seröz kistin histopatolojik görüntüsü. HE. Bar = 100 µm.

In congenital liver cysts, no sexual predisposition has been reported in animals. In the present study, the liver cysts found incidentally during necropsy examination were determined in female fetuses and calves in all cases, which could be considered intriguing. Congenital liver cysts in many species have been reported to be associated with kidney and pancreas cysts (Stebbins et al., 1989; Krotec et al., 1996; Newman et al., 2000). Contrary to previous reports, the cysts seen in this study were localized exclusively in liver. The cysts observed in the calves were much bigger than those of spotted in the fetuses. Presence of larger cystic content in calves might be considered to be due to prolonged fluid accumulation after birth.

The clinical findings of long term lack of appetite and distension and bloating in abdominal regions seen in the calves of present study have not been noted in previous reports (MacLachlan and Cullen, 1995; Jones et al., 1997). Therefore, it would be suggested that congenital liver cysts in animals with aforementioned clinical findings should also be evaluated in addition to primary and secondary tympanis and tumors formed in abdominal cavity.

Congenital serous liver cysts should be distinguished from intrahepatic congenital liver cysts and multiple cysts originating from bile ducts, parasitic cysts and biliary cyst adenomas (MacLachlan and Cullen, 1995; Last et al., 2006; Stalker and Hayes, 2007). In the present study, the serous cysts were differentiated from other

congenital cysts in that they were attached to capsule on diaphragmatic surface of liver and did not have biliary pigment (McKenna and Carpenter, 1980; Stebbins et al., 1989; Jones et al., 1997). Moreover, they were separated from biliary cyst adenomas in that they had a tumor related change in cells on the walls of cyst (MacLachlan and Cullen, 1995; Jones et al., 1997; Stalker and Hayes, 2007).

## References

- Culling CFA, Allison RT and Barr WT (1985). Cellular Pathology Technique. 4th Ed., Butterworth & Co.(Publ.) Ltd, London.
- Jones TC, Hunt RD and King NW (1997). Veterinary Pathology (1997). 6th Edit., Williams & Wilkins A Waverly Company, USA, pp. 1090.
- Kai K, Sato N, Watanabe A, Shiraiwa K, Ogawa S and Kobayashi Y (2001). Polycystic disease of the kidney and liver in Crj: CD(SD). Journal of Toxicologic Pathology, 14, 51-55.
- Krotec K, Meyer BS, Freeman W and Hamir AN (1996). Congenital cystic disease of the liver, pancreas, and kidney in a Nubian goat (*Capra hircus*). Veterinary Pathology, 33, 708-10.
- Last RD, Hill JM, Roach M and Kaldenberg T (2006) Congenital dilatation of the large and segmental intrahepatic bile ducts (Caroli's disease) in two Golden retriever littermates. Journal of South African Veterinary Association, 77, 210-4.
- MacLachlan NJ and Cullen JM (1995). Liver, Biliary System, and Exocrine Pancreas. In: Thomson's Special Pathology, 2nd Edit., WW Carlton and MD McGavin (Eds.), Mosby, USA, pp. 85.
- McKenna SC and Carpenter JL (1980). Polycystic disease of the kidney and liver in the Cairn Terrier. Veterinary Pathology, 17, 436-42.
- Newman SJ, Lechner T, Crisman M and Ramos J (2000). Congenital cystic disease of the liver and kidney in a pygmy goat. Journal of Veterinary Diagnostic Investigation, 12, 374-8.
- Stalker MJ and Hayes MA (2007). Liver and Biliary system. In: Pathology of Domestic Animals, Vol 2, 5th Edit., MG Maxie, Elsevier Saunders, London, pp. 301-302.
- Stebbins KE (1989). Polycystic disease of the kidney and liver in an adult Persian cat. Journal of Comparative Pathology, 100, 327-30.
- Van den Ingh TSGAM and Rothuizen J (1985). Congenital cystic disease of the liver in seven dogs. Journal of Comparative Pathology, 95, 405-414.