




DOI: 10.38136/jgon.852602

**Prenatal Diagnosis of Joubert Syndrome With Whole Exome Sequencing****Joubert Sendromunun Tüm Ekzom Dizim ile Prenatal Tanısı**Erhan H. CÖMERT<sup>1</sup>Emine S. GÜVENDAĞ GÜVEN<sup>2</sup>Süleyman GÜVEN<sup>2</sup> Orcid ID:0000-0003-1431-2294 Orcid ID:0000-0002-8380-2804 Orcid ID:0000-0002-3347-4814<sup>1</sup> Clinic of Obstetric and Gynecology, Istanbul Rumeli University, Istanbul, Turkey<sup>2</sup> Karadeniz Technical University, Faculty of Medicine, Obstetrics and Gynecology, Trabzon, Turkey**ÖZ**

Joubert sendromu (JS), ilk olarak Marie Joubert tarafından tanımlanmıştır. Siliyopatiye ait genlerin nedensel mutasyonu ile karakterize, otozomal resesif geçişli kalıtsal bir hastalıktır.

27 yaşında bir kadın, prenatal yapılan ultrasonografide renal kist saptanması üzerine ileri araştırma için kliniğimize sevk edildi. Ayrıntılı ultrasonografik incelemede fetal polikistik böbrek gözlemlendi. Korion villus örneklemede INPP5E mutasyonu mevcuttu. Gebeliğin 23. haftasında yapılan ultrasonografide vermis hipoplazisi, polikistik böbrek ve molar diş bulgusu mevcuttu. Bu bulguların başta joubert sendromu olmak üzere sendromik bir durum olduğu düşünüldü. MRI incelemesindeki vermis hipoplazisi, posterior fossa genişlemesi ve bilateral polikistik böbrek gözlemlendi ve radyolog bu durumu Dandy-Walker'a bağlı olduğu bildirildi, fakat molar diş bulgusuna dikkat etmediği anlaşıldı ve tekrar konsülte edildi. Aileye prognoz hakkında bilgi verildi ve terminasyon seçeneği sunuldu. JS'nin en yaygın karakteristik beyin görüntüsü aksel düzlemdeki molar diş işareti (MTS), serebellar vermis (CV) hipoplazisi ve derinleşmiş interpedunküler fossadır. MTS, bu hastalık için anahtar tanısal özelliktir. Şimdiye kadar, JSRD'nin çeşitli alt tipleri için 30'dan fazla nedensel gen bulundu. Bunlardan biri INPP5E. Ekstra sinir sistemi kusurları arasında polikistik böbrek hastalığı, retina dejenerasyonu, iskelet kusurları (polidaktili gibi) ve karaciğer bozukluğu yer alır.

Joubert Sendromu prenatal dönemde teşhis edilebilir. MTS prenatal dönemde ultrasonografi ile rahatlıkla görülebilir. Vermian hipoplazisi ve ek organ anomalileri olması akla JS getirmeli ve molar diş bulgusu araştırılmalıdır.

**Anahtar Kelimeler:** joubert sendromu, molar diş bulgusu, vermis hipoplazisi, polikistik böbrek, INPP5E geni

**ABSTRACT**

Joubert syndrome (JS), was first discovered by Marie Joubert, which is a rare autosomal recessive inherited disease belonging to ciliopathy with the causative mutation of genes. A 27-years-old woman was referred to our clinic for advanced research over the detection of fetal renal cyst. We observed polycystic kidney in detailed ultrasonographic examination. INPP5E mutation was detected on chorion villus sampling. We were thought may be this findings will be associated with the any syndrome, primarily joubert syndrome (JS), upon detection the vermis hypoplasia, polycystic kidney and molar teeth sign were observed on USG in the 23rd week of pregnancy. The vermis hypoplasia, posterior fossa expansion and bilateral polycystic kidney were seen on MRI and the radiologist has reported as Dandy-Walker depend on this findings. They did not pay attention to the molar tooth finding. We were explained prognosis and suggested termination to the family. The fetus was terminated upon the approval of the family. The most common characteristic brain image of JS is the molar tooth sign (MTS) on the axial plane, cerebellar vermis (CV) hypoplasia, and a deepened interpeduncular fossa. The MTS is the key diagnostic feature for this disease. So far, more than 30 causative genes have been found for the various subtypes of JSRD. One of them is INPP5E. Defects of additional extra-nervous systems involve polycystic kidney disease, retinal degeneration, skeletal defects (such as polydactyly), and liver disorder.

Joubert Syndrome can be diagnosed in prenatal period. MTS can be seen easily with usg during prenatal period. The vermis hypoplasia and additional organ anomalies must be brought to mind JS and MTS should be searched and families should be given prenatal counseling

**Keywords:** joubert syndrome, molar teeth sign, vermis hypoplasia, polycystic kidney, INPP5E gene

**Sorumlu Yazar/ Corresponding Author:**

Erhan Huseyin COMERT

Adres: Clinic of Obstetric and Gynecology, Rumeli University, Istanbul, Turkey

E-mail: erhan.comert@hotmail.com

Başvuru tarihi : 04.01.2021

Kabul tarihi : 06.01.2022

## INTRODUCTION

Joubert syndrome (JS) is a rare autosomal recessive inherited disease. It was first defined by Marie Joubert in 1969 (1). The cerebellar vermis hypoplasia, midbrain anomalies and molar tooth sign (MTS) are most common typical brain image of JS. MTS is the diagnostic sign of JS on MRI (2). In addition, JS includes extra neurological symptoms such as, neural tube defects, retinal dystrophy, polydactyly, liver fibrosis and cystic renal disease. (3,4).

JS may get misdiagnosed as Dandy Walker Variant (DWV). A definitive diagnosis is important for the management of the disease because of the prognosis is different between JS and DWV. In this situation, The MTS finding on MRI facilitates distinction. The neurological findings which is detected by USG such as cerebellar vermis hypoplasia, ventriculomegaly are not specific for JS. In this suspected cases, MRI should be planned.(2,5)

In this case, we present a case of JS who decided to terminate after genetic consultation.

## CASE

A 27-years-old woman(G1P0) was referred to our clinic for advanced research over the detection of fetal renal cyst. We observed polycystic kidney in detailed examination. Upon this, we were proposed karyotype analysis of the fetus. The chorion villus sampling was made to the patient. Karyotype analysis was normal. In the 23rd week of pregnancy, the patient was referred for detailed ultrasonography because of present anomalies. We were thought may be this findings will be associated with the syndrome, primarily joubert syndrome (JS), upon detection the vermician hypoplasia, polycystic kidney and molar teeth sign (MTS) was observed on USG (figure 1, 2). MRI planned for further examination. The vermician hypoplasia, posterior fossa expansion and bilateral polycystic kidney was seen on MRI. The radiologist was reported as Dandy-Walker variant(DWV) depend on this findings. The radiologist was commented as Dandy-Walker with bilateral polycystic kidney at first stage. In the mutual consultation, the diagnosis of joubert syndrome was clarified because of molar teeth sign on MRI (figure 3, 4). We were explained prognosis and suggested termination to the family. The family was accepted and fetus was terminated. Cordosentez was taken for whole exome sequence analysis of the patient. The result is c.1340G>A (p.R435Q) Homozygous at

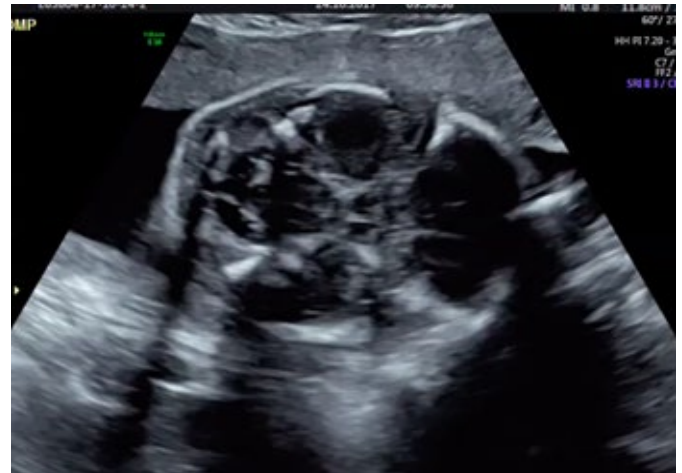INPP5E gene . Both parents are heterozygous carrier for the mutation.

## DISCUSSION

The typical brain image of JS is especially the molar tooth sign, a deepened interpeduncular fossa and cerebellar vermician hypoplasia (6). The pathognomonic feature of JS is MTS which is the part of JS, reported to accompany many syndromes in literature. Finally the terms Joubert syndrome and related disorders (JSRD) have been used for all disorders that indicate MTS on brain imaging studies (7,8).

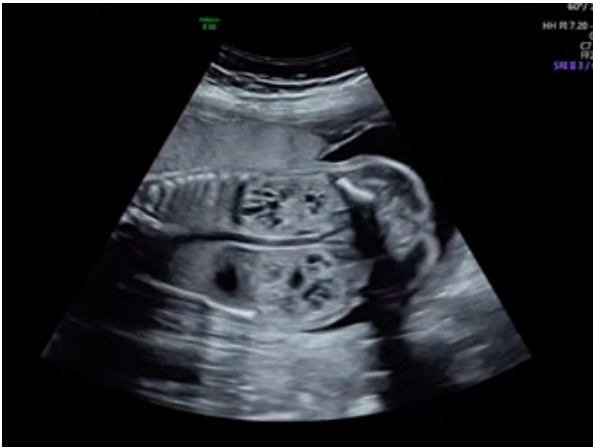In a study, who had abnormal cerebrospinal fluid collections were incorrect diagnosis as DWV, these constitute about 10% of the cases with JS. The prognosis is greatly different between JS and DWV. A definitive diagnosis is important for patient's management, genetic counseling and prediction of disease. Thus, the MTS on axial imaging can effectively separate Joubert and Dandy-Walker syndrome (2,5). The abnormalities as cerebellar vermician aplasia/hypoplasia, ventriculomegaly on prenatal ultrasound screening of fetuses are not specific for JS. MRI should be planned to the suspected cases in addition to serial ultrasonography (9). Such as in our case we suspected MTS on ultrasonography (figure 1)

**Figure 1-**Molar teeth sign in aksiyal ultrasound image of fetal brain

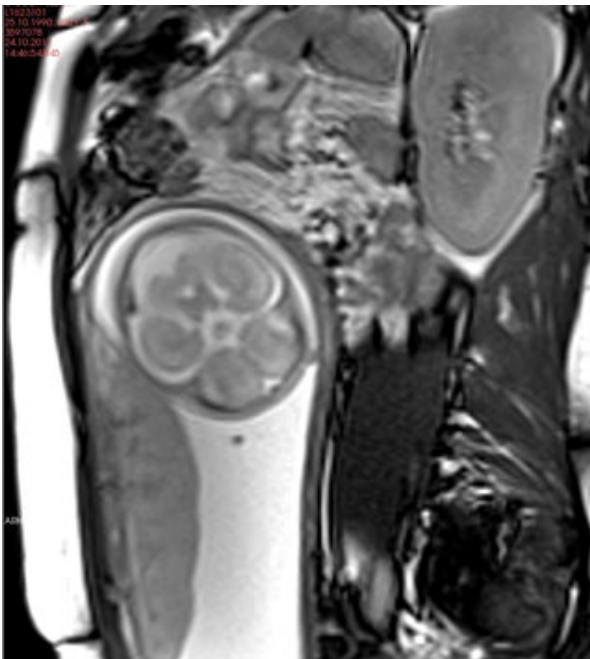

and we planned MRI for confirming to our diagnosis. The MTS finding has been a guide in our diagnosis of JS as shown in figure 3.

**Figure 2-** Ultrasound image of polycystic kidney of fetus. Both renal of fetus have polycystic appearance



**Figure 3-** Axial magnetic resonance imaging of fetal brain showing MTS.



The JSRD is more often diagnosed after birth also clinical symptoms may vary from mild to severe. The congenital ataxia, mental retardation, decreased muscle tone, neonatal intermittent dyspnea, abnormal eye movement and various growth retardations are common nervous system manifestations of JSRD. The MTS is the key diagnostic feature distinctive from other diseases of JSRD. The other organ abnormalities must be investigated because extra-neurological pathology may accompanied to JS (8,10,11).

Although uncertain, the incidence of JSRD may difference between 1/80,000 and 1/ 100,000 live births. It has subtypes according to different organ involvement (12,13). When subtypes of JSRD were investigated, more than 30 genes were found (14). The INPP5E gene in our case is one of these subtypes.

Bielas et al. (2009)(15) identified 5 different homozygous mu-

tations in the INPP5E gene in affected members of 7 families with JS. The polycystic kidney disease, liver disorders, skeletal defects and retinal degeneration can be evaluated as additional extra-nervous systems findings (8,16). When the case reports accompanying INPP5E mutation in the literature were examined, one of the 2 cases in one study had end-stage renal failure, and one of the 31 cases in the other study had cystic renal disease (15,17). Also in our case, in addition there were polycystic kidneys with accompanied with JS.

Joubert Syndrome can be diagnosed in prenatally period. At the same time, it would be appropriate to give prenatal counseling in such cases. Molar tooth finding, which is the key finding of JS, can be seen easily with usg during prenatal period. The vermian hypoplasia and additional organ anomalies must be brought to mind Joubert Syndrome and Molar Teeth Sign should be searched.

## REFERENCES

1. JoubertM, Eisenring JJ, Robb JP, et al. Familial agenesis of the cerebellar vermis. A syndrome of episodic hyperpnea, abnormal eye movements, ataxia, and retardation. *Neurology* 1969;19:813–25.
2. Maria BL, Quisling RG, Rosainz LC et al: Molar tooth sign in Joubert syndrome: clinical, radiologic, and pathologic significance. *J Child Neurol* 1999;14:368–376.
3. Parisi M, Glass I: Joubert Syndrome and related disorders. *Gene Rev*1993, rev. 2013.
4. Doherty D: Joubert syndrome: insights into brain development, cilium biology, and complex disease. *Semin Pediatr Neurol*2009;16:143–154
5. B. L.Maria, A. Bozorgmanesh, K.N. Kimmel, D.Teriaque, and R. G. Quisling, "Quantitative assessment of brainstem development in Joubert syndrome and Dandy-Walker syndrome," *Journal of Child Neurology*, vol. 16, no.10, pp. 751–758, 2001.
6. Louie CM, Gleeson JG. Genetic basis of Joubert syndrome and related disorders of cerebellar development. *Hum Mol Genet* 2005;2(14 SpecNo):R235–42.
7. Gleeson JG, Keeler LC, Parisi MA, Marsh SE, Chance PF, Glass IA, Graham JM Jr, Maria BL, Barkovich AJ, Dobyns WB: Molar tooth sign of the midbrain-hindbrain junction: occurrence in multiple distinct syndromes. *Am J Med Genet A* 2004, 125:125-134.
8. Brancati F, Dallapiccola B, Valente EM. Joubert Synd-

rome and related disorders. *Orphanet J Rare Dis* 2010;5:20

9. Siyuan Linpeng, Jing Liu, Jianyan Pan, Yingxi Cao, Yanling Teng, Desheng Liang , et. All. Diagnosis of Joubert Syndrome 10 in a Fetus with Suspected Dandy-Walker Variant by WES: A Novel Splicing Mutation in OFD1. *BioMed Research International* Volume 2018, Article ID 4032543, 7 pages <https://doi.org/10.1155/2018/4032543>
10. Kroes HY, Monroe GR, van der Zwaag B, et al. Joubert syndrome: genotyping a Northern European patient cohort. *Eur J Hum Genet* 2016;24:214–20
11. Elhassanien AF, Alghaiaty HAA. Joubert syndrome: clinical and radiological characteristics of nine patients. *Ann Indian Acad Neurol* 2013;16:239–44
12. Parisi MA, Doherty D, Chance PF, Glass IA: Joubert syndrome (and related disorders) (OMIM 213300). *Eur J Hum Genet* 2007, 15:511-521.
13. Kroes HY, van Zon PH, van de Putte DF, Nelen MR, Nivelstein RJ, Wittebol-Post D, van NO, Mancini GM, van der Knaap MS, Kwee ML, Maas SM, Cobben JM, De Nef JE, Lindhout D, Sinke RJ: DNA analysis of AHI1, NPHP1 and CYCLIN D1 in Joubert syndrome patients from the Netherlands. *Eur J Med Genet* 2008, 51:24-34
14. Vilboux T, Doherty DA, Glass IA, et al. Molecular genetic findings and clinical correlations in 100 patients with Joubert syndrome and related disorders prospectively evaluated at a single center. *Genet Med* 2017;19:875–82
15. Bielas, S. L., Silhavy, J. L., Brancati, F., Kisseleva, M. V., Al-Gazali, L., et al: Mutations in INPP5E, encoding inositol polyphosphate-5-phosphatase E, link phosphatidylinositol signaling to the ciliopathies. *Nat Genet* 2009;41:1032–1036.
16. Doherty D. Joubert syndrome: insights into brain development, cilium biology, and complex disease. *Semin Pediatr Neurol* 2009;16:143–54.
17. Travaglini L, Brancati F, Silhavy J et al: Phenotypic spectrum and prevalence of INPP5E mutations in Joubert syndrome and related disorders. *Eur J Hum Genet* 2013; 21:1074–1078