



Novel Chaphamaparvovirus in a Paradise Tanager Songbird with Encephalitis, Neuritis, and Ventriculitis

Eda Altan^{1,2a}, Steven Kubiski^{3b}, Ilse Stalis^{3c}, Yanpeng Li^{1,2d}, Xutao Deng^{1,2e}, Eric Delwart^{1,2f}

1. Vitalant Research Institute, 270 Masonic Ave, San Francisco, California, USA.

2. Department of Laboratory Medicine, University of California San Francisco, San Francisco, California, USA.

3. Disease Investigations, San Diego Zoo Alliance, 15600 San Pasqual Valley rd, Escondido, California, USA.

ORCID: 0000-0001-7903-6986^a, 0000-0002-6344-7841^b, 0000-0002-9957-7154^c, 0000-0002-0643-4809^d, 0000-0001-6619-9989^e, 0000-0002-6296-4484 0-0001^f

| Geliş Tarihi/Received | Kabul Tarihi/Accepted | Yayın Tarihi/Published |
|-----------------------|-----------------------|------------------------|
| 13.01.2021 | 22.02.2021 | 26.04.2021 |

Bu makaleye atıfta bulunmak için/To cite this article:

Altan E, Kubiski S, Stalis I, Li Y, Deng X, Delwart E: Novel Chaphamaparvovirus in a Paradise Tanager Songbird with Encephalitis, Neuritis, and Ventriculitis. *Atatürk University J. Vet. Sci.*, 16(1): 25-31, 2021. DOI: 10.17094/ataunivbd.859162

Abstract: *Parvoviridae* family being an extremely fast-growing family and is open to novel viral discoveries. Many new parvoviruses from different vertebrates and invertebrates hosts have been discovered in recent years. The taxonomy has changed with new classification by the International Committee on Taxonomy of Viruses. The subfamily *Hamaparvovirinae* has been added to the prior subfamilies that consisted of *Parvovirinae* and *Densovirinae*. *Chaphamaparvovirus* is a recently identified genus of *Hamaparvovirinae*, including some members associated with nephropathy in laboratory mice and high mortality in Tilapia fish. Samples from a deceased Northern paradise tanager (*Tangara chilensis paradisea*) with nonsuppurative encephalitis, neuritis, and ventriculitis were examined by light microscopy and ancillary histochemical stains for bacteria, protozoa, fungi, and other parasites. Samples were also analyzed by PCR for general protozoa, paramyxovirus, avian bornavirus, and herpesvirus. None of these known pathogens were detected. Using viral metagenomics we identified and characterized the genome of a novel chaphamaparvovirus in tissues of this bird. No other viral sequences were identified. This virus's contributory role to these lesions will require further studies.

Keywords: Chaphamaparvovirus, Chufflevirus, Metagenomics, Parvovirus, *Tangara chilensis paradisea*.

Ensefalit, Neurit ve Ventrikülit'li Paradise Tanager Ötücü Kuşunda Yeni Chaphamaparvovirus

Öz: *Parvoviridae* ailesi son derece hızlı büyüyen bir ailedir ve yeni virus keşiflerine açıktır. Son yıllarda bu aileye ait farklı omurgalılarından ve omurgasızlardan birçok yeni virus keşfedilmiştir. Yapılan yeni keşiflerle Uluslararası Virus Taksonomisi Komitesi tarafından taksonomi değiştirilmiştir. Daha önce *Parvovirinae* ve *Densovirinae* olan alt ailelere *Hamaparvovirinae* alt ailesi eklenmiştir. *Chaphamaparvovirus*, yakın zamanda tanımlanan bir parvovirus genusudur (*Parvoviridae* ailesi) bazı alt türleri laboratuvar farelerinde nefropati ile ilişkili ve Tilapia balıklarında yüksek ölüm oranı göstermektedir. Ensefalit, nörit ve ventrikülitli bulguları ile ölen bir Cennet Tangarası (*Tangara chilensis paradisea*) kuşundan alınan numuneler, ışık mikroskobu ve bakteriyolojik, protozoer, mantar, ve diğer paraziter etkenler yönünden histokimyasal olarak incelendi. Örnekler ayrıca genel protozoa, paramiksovirus, avian bornavirus ve herpesvirus için PCR ile analiz yapıldı ve bulaşıcı ajan tespit edilmedi. Yeni nesil sekanslama methodu ile viral metagenomik kullanarak, bu kuşun dokularındaki yeni bir chaphamaparvovirus genomunu karakterize edildi Herhangi başka hiçbir viral sekans (etken) tanımlanmadı. Bu çalışma yeni bir virus keşif yayını olup bu virusun bu lezyonlara katkıda bulunan rolünün doğrulanması için öncü nitelikte olacaktır.

Anahtar Kelimeler: Cennet Tangarası kuşu, Chaphamaparvovirus, Chufflevirus, Metagenomics, Parvovirus.

^aEda Altan

Vitalant Research Institute, 270 Masonic Ave, San Francisco, California, USA.

Department of Laboratory Medicine, University of California San Francisco, San Francisco, California, USA.

e-mail: edaltan@hotmail.com

INTRODUCTION

Paradise Tanager songbirds, in the Thraupidae family of the Passeriformes order, are small colorful birds found in tropical and subtropical forests of the Western and Northern Amazon Basin, including Brazil, Peru, Colombia, Venezuela, and Ecuador. Thraupidae is the second-largest family of birds representing 4% of all bird species (1).

Members of the *Parvoviridae* virus family have been reported in numerous vertebrate and invertebrate species (2,3) with single strain DNA (ssDNA) genomes 4–6.3 kb in size encoding two to four open reading frames (ORFs). Recently, the *Parvoviridae* family has been re-organized into three different subfamilies (3). Members of the *Parvovirinae* subfamily infect vertebrate hosts, those of the *Densovirinae* subfamily infects invertebrates, and those of the recently created *Hamaparvovirinae* subfamily infect either invertebrate (*Penstylhamaparvovirus*, *Brevihamaparvovirus*, *Hepanhamaparvovirus*, *Ichthamaparvovirus*) or vertebrates (*Chaphamaparvovirus*) (3). Chaphamaparvoviruses have recently been detected in dogs (4, 5), pigs (6), rats (7,8), red-crowned cranes (9), turkeys and chickens (10,11), macaques (12,13), bats (14,15), Tasmanian devils (16), fish (17), human (18) and most recently in cat (19).

Here we describe a novel member of the *Chaphamaparvovirus* genus in tissues of a bird with inflammation in the nervous and renal tissues.

MATERIALS and METHODS

Animal and Post-Mortem Examination and PCR

A young, adult female Northern paradise tanager (*Tangara chilensis paradisea*) housed in a large aviary at a zoological institution was found dead with no premonitory signs of disease. The bird that contributed tissues for metagenomics and PCR was necropsied due to a poor or grave prognosis for recovery in accordance with the American Association of Zoo Veterinarians Guidelines for Euthanasia of Non-Domestic Animals (2006) and the

American Veterinary Medical Association Guidelines for the Euthanasia of Animals (2013). Ethics approval and consent to participate samples were utilized under San Diego Zoo Wildlife Alliance's Institutional Animal Care and Use Committee (#18-024). Tissues utilized post mortem were collected as routine practice for tissue archiving purposes.

A full post-mortem examination was conducted the day the bird was found. A complete suite of tissues was collected, fixed in 10% neutral-buffered formalin. Paraffin-embedded tissue samples, sectioned at 5 μ m, were stained with hematoxylin and eosin (HE). Sections of the brain were also stained with Gram and Steiner's stains. Brain tissue was tested by polymerase chain reaction (PCR) for general protozoa, paramyxovirus, bornavirus, and herpesvirus; the methods were used as explained by others (20-23). Additionally, samples of the brain, lung, liver, and intestine were saved at -70°C.

Viral Metagenomics

Liver tissue from the affected paradise tanager which had been frozen at -70°C were thawed and homogenized with the rotor in approximately 10x volume of Phosphate-buffered saline. The homogenized sample was again frozen and thawed twice on dry ice to facilitate the release of viral particles. Centrifugation was performed at 15 000 \times g, 4°C for 10 minutes, and the supernatant filtered using a 0.45 μ m pores filter (Millipore). DNase and RNase enzymes were then incubated with filtrate to enrich for viral nucleic acids. MagMAX Viral RNA Isolation Kit (Ambion) was used for total nucleic acid extraction (24) For random RT-PCR and library preparation with dual barcoding we followed a previously described protocol (25).

An in-house bioinformatic pipeline was used to analyze raw sequence data. Before analysis, raw sequence reads were pre-processed to remove human and bacterial sequences, and duplicate and low-quality reads. ENSEMBLE program was then used

for de novo assembly (26), and both contigs and singlets viral protein sequences were analyzed for similarity with all annotated viral proteins available in GenBank (BLASTx v.2.2.7). The Geneious R10 program was used for sequence alignments and to generate genomes and identify viral motifs.

Phylogenetic Analysis

Paradise tanager parvovirus non-structural (NS1) and capsid protein (VP1) sequences were aligned using MAFFT in the Geneious program and the aa phylogenetic trees of parvoviruses were constructed using the Maximum likelihood method with two substitution models: Le_Gascule_2008 model (LG) with Freqs and gamma-distributed, invariant sites (G + I) MEGA software ver. X (27). The analysis involved 23 and 25 protein sequences of chaphamaparvoviruses and aveparvoviruses for the phylogenetic tree. Evolutionary analysis was conducted in MEGAX (28).

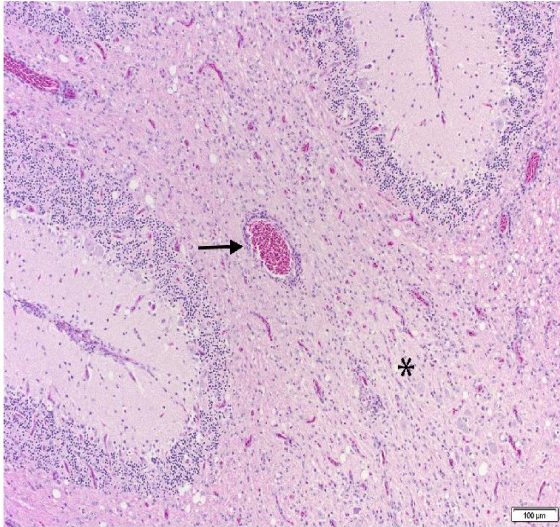


Figure 1. Leukoencephalitis of the cerebellum with hypercellular white matter (asterisk) and aggregates of lymphocytes and plasma cells around vessels (arrow). Hematoxylin and eosin, 200X magnification.
Şekil 1. Hipersellüler beyaz cevher (yıldız işareti) ve damarların çevresinde lenfosit ve plazma hücrelerinin agregaları (ok) içeren beyincikte lökoensefalit. Hematoksilen ve eozin, 200X büyütme.

RESULTS

Animal and Histology

There was no evident cause of death at necropsy and no gross lesions diagnosed. Histologically, there were multifocal areas of mild nonsuppurative inflammation in the brain, with hypercellularity and perivascular cuffing in the white matter of the cerebellum and optic lobe (Figure 1). In the sciatic nerve, inflammation was more significant with more moderate infiltration of mononuclear cells, thick perivascular aggregates, and axonal disruption (Figure 2). Brain tissue collected at necropsy and stored at -70°C was negative by PCR for general protozoa, paramyxovirus, bornavirus, and herpesvirus. Lesions were negative for bacteria, protozoa, fungi, and other parasites by light microscopy and ancillary histochemical stains, including silver stain (Steiner) and Gram stain (MacCallum-Goodpasture).

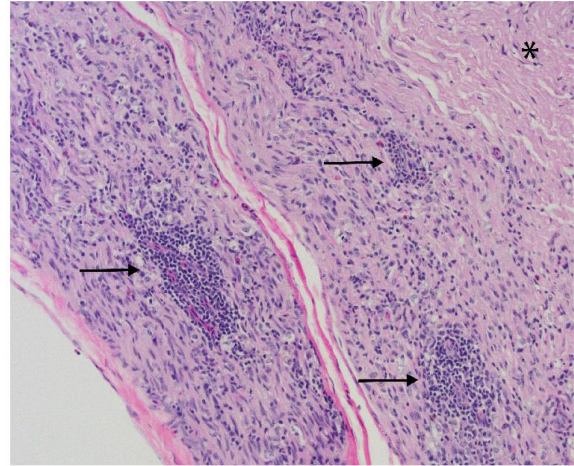


Figure 2. Sciatic neuritis with dense infiltration of lymphocytes and plasma cells and thick perivascular aggregates (arrows), as compared to fairly unaffected area of the nerve (asterisk). Hematoxylin and eosin, 100X magnification.

Şekil 2. Sinirin oldukça etkilenmemiş alanı (yıldız işareti) ile karşılaştırıldığında, yoğun lenfosit ve plazma hücreleri infiltrasyonu ve kalın perivasküler kümeler (oklar) ile siyatik nörit. Hematoksilen ve eozin, 100X büyütme.

Viral Metagenomics

A liver tissue sample was processed and a total number of 800 thousand reads were generated. The raw data is available in Short Reads Archive-SRA (National Center for Biotechnology Information-NCBI) under accession number SUB7782092. A total of 724 reads yielded matches to chaphamaparvovirus proteins in GenBank with E score ranging from $1.73e^{-171}$ to $6.12e^{-07}$, including a 2603 base contigs. No matches to other eukaryotic viral proteins (E score $<10^{-10}$) were detected. We, therefore, detected evidence for the presence of only one virus that we named chufflevirus. The length of the paradise tanager bird chaphamaparvovirus genome obtained was 4196 nucleotide (nt) long with typical genome organization of four major ORFs (Figure 3 - MT764779). The terminal repeats at the extremities of parvoviruses could not be detected, indicating that only a partial genome sequence was generated. The virus showed 41.7% G+C content with a distribution of 33.7% A, 24.64% T, 20.3% G, and 21.4% C. Both the ATP-/GTP-binding Walker A loop motif (GxxxxGKT/S; GPSNTGKS) and Walker B motif (EE) were found in the NS1 (29).

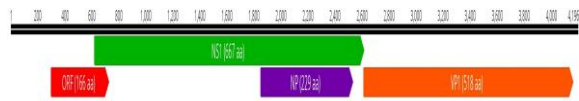


Figure 3. Chufflevirus genome structure (Created by Geneious R10).

Şekil 3. Chufflevirus genom yapısı (Geneious R10 tarafından oluşturulmuştur).

Phylogenetically the proteins of the chufflevirus clustered with recently generated chaphamaparvoviruses sequences from anal swabs of wild and zoo birds from China, particularly from bunting birds (Emberizidae) which like paradise birds (Thraupidae) are also members of the Emberizoidea superfamily in the (Figure 4A-B). The nonstructural

protein (NS1) and the capsid proteins (VP1) proteins have shown the closest aa identity of 50 to 83.3% and 44.4 to 82.9% to proteins of these bird parvoviruses.


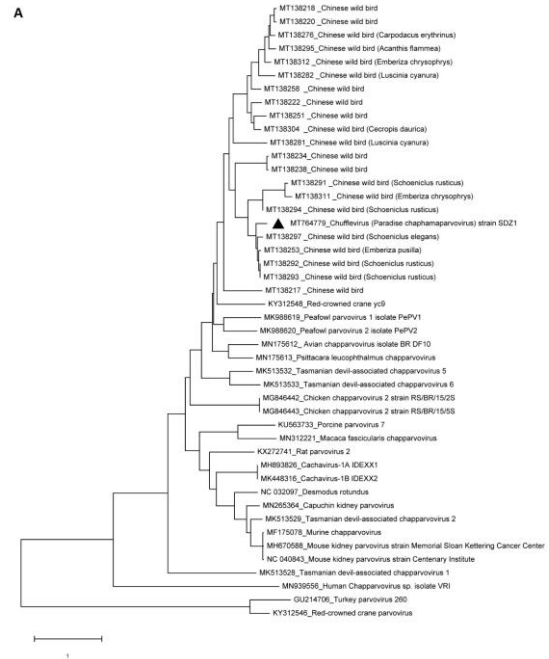


Figure 4. Phylogenetic trees (A; NS1 and B; VP1) were constructed using the Maximum likelihood method with two substitution models: Le_Gascule_2008 model (LG) with Freqs and gamma distributed, invariant sites (G + I) model MEGA software version X.

Şekil 4. Filogenetik ağaçlar (A; NS1 ve B; VP1), çift ikame modeliyle Maksimum olasılık yöntemi kullanılarak oluşturulmuştur: frekans ve gama dağılımı, değişmez bölgeler (G + I) modeli MEGA yazılım sürümü ile Le_Gascule_2008 modeli (LG).

DISCUSSION and CONCLUSION

Although the *Parvoviridae* family is a DNA virus family, it has a high mutation rate (30). Within this family, multiple new genomes are detected every year in different animal hosts and countries (2,4,5,13,18). Chaphamaparvoviruses have recently been detected in dogs (4), cats (19), pigs (6), rats (7,8), red-crowned cranes (9), turkeys and chickens (10,11,31), macaques (12,13), bats (14,15), Tasmanian devils (16), murine (32) and fish (17,33,34). A chaphamaparvovirus was recently reported in the serum of a febrile Brazilian (18). Chaphamaparvoviruses have been shown to cause nephropathy in laboratory mice (32,35) and tilapia fish (34). Some studies have shown an association between cat and dog chaphamaparvoviruses detection and diarrhea (4,19), while others have not (36).

The paradise tanager brain was used for PCR to test for pathogens often associated with brain inflammation and remaining tissues (liver and lung) were chosen for viral metagenomics. PCR for viruses associated with avian encephalitis and ganglioneuritis were negative, while other pathogens associated with these lesions (bacteria and fungi) were not seen in histologic sections. Despite these negative results, a viral etiology was the primary consideration based on the distribution and character of inflammation.

The chufflevirus genome was the only viral nucleic acid found in the lung and/or liver tissues using metagenomics. The detection of related chaphamaparvoviruses in fecal swabs of bunting birds indicates that avian chaphamaparvoviruses transmission likely occurs through the oral-fecal route. Viral detection in internal organs of the sick paradise tanager songbird indicated that chufflevirus can also replicate beyond the digestive tract, as is the case for other chaphamaparvoviruses including mouse kidney parvovirus resulting in murine nephropathy (32,35) and Tilapia parvovirus, which infects kidney, spleen, liver, intestine, and brain, resulting in massive fish mortality (34).

Whether this novel parvovirus is related to the inflammatory lesions in this songbird will require induction of disease using virus inoculation, observation of a disease outbreak involving this virus, or significantly increased prevalence and viral loads in a case-control epidemiological study. In situ methods for demonstrating chaphamaparvoviral DNA in anatomical lesions would also add support for an association between infection and disease. While uncommon, similar lesions have been seen in other tanagers, so an investigation into this novel virus's role in disease is warranted.

Conflict of interest

The authors declare that they have no conflict of interest.

REFERENCES

1. Gunnarsson G., Latorre-Margalef N., Hobson KA., Van Wilgenburg SL., ElMBERG J., Olsen B., Fouchier RA., Waldenstrom J., 2012. Disease dynamics and bird migration—linking mallards *Anas platyrhynchos* and subtype diversity of the influenza A virus in time and space. *PLoS One* 7, e35679.
2. Aydin H., Timurkan MO., Aktas O., 2019. Genetic diversity of primate erythrovirus 1 between 2009 and 2016: First report from Turkey. *Microb pathog*, 131-135.
3. Penzes JJ., Soderlund-Venermo M., Canuti M., Eis-Hubinger AM., Hughes J., Cotmore SF., Harrach B., 2020. Reorganizing the family *Parvoviridae*: a revised taxonomy independent of the canonical approach based on host association. *Arch Virol*, 165, 2133-2146.
4. Fahsbender E., Altan E., Seguin MA., Young P., Estrada M., Leutenegger C., Delwart E., 2019. Chapparvovirus DNA Found in 4% of Dogs with Diarrhea. *Viruses*, 11,398.
5. Dinçer E., Timurkan MÖ., Polat Dinçer FP., Aydın H., 2020. Co-circulation of canine chaphamaparvovirus and canine parvovirus 2 in dogs with diarrhea in Turkey. *Thai J Vet Med*. 50, 495-501.

6. Palinski RM., Mitra N., Hause BM., 2016. Discovery of a novel Parvovirinae virus, porcine parvovirus 7, by metagenomic sequencing of porcine rectal swabs. *Virus Genes*, 52, 564-567.
7. Williams SH., Che X., Garcia JA., Klena JD., Lee B., Muller D., Ulrich W., Corrigan RM., Nichol S., Jain K., Lipkin WI., 2018. Viral Diversity of House Mice in New York City. *mBio* 9. e01354-17.
8. Yang S., Liu Z., Wang Y., Li W., Fu X., Lin Y., Shen Q., Wang X., Wang H., Zhang, W., 2016. A novel rodent Chapparvovirus in feces of wild rats. *Virol J*, 13, 133.
9. Wang Y., Yang S., Liu D., Zhou C., Li W., Lin Y., Wang X., Shen Q., Wang H., Li C., Zong M., Ding Y., Song Q., Deng X., Qi D., Zhang W., Delwart E., 2019. The fecal virome of red-crowned cranes. *Arch Virol*, 164, 3-16.
10. Lima DA., Cibulski SP., Tochetto C., Varela APM., Finkler F., Teixeira TF., Loiko MR., Cerva C., Junqueira DM., Mayer FQ., Roehe PM., 2019. The intestinal virome of malabsorption syndrome-affected and unaffected broilers through shotgun metagenomics. *Virus Res*, 261, 9-20.
11. Reuter G., Boros A., Delwart E., Pankovics P., 2014. Novel circular single-stranded DNA virus from turkey faeces. *Arch Virol*, 159, 2161-2164.
12. Kapusinszky B., Ardeshir A., Mulvaney U., Deng X., Delwart E., 2017. Case-control comparison of enteric viromes in Captive Rhesus Macaques with acute or idiopathic chronic diarrhea. *J Virol*, 91. e00952-17. 1-19
13. Sawaswong V., Fahsbender E., Altan E., Kemthong T., Deng X., Malaivijitnond S., Payungporn S., Delwart E., 2019. High diversity and novel enteric viruses in fecal viromes of healthy wild and captive Thai *Cynomolgus* Macaques (*Macaca fascicularis*). *Viruses*, 11, 1-19.
14. Baker KS., Leggett RM., Bexfield NH., Alston M., Daly G., Todd S., Tachedjian M., Holmes CE., Crameri S., Wang LF., Heeney JL., Suu-Ire R., Kellam P., Cunningham AA., Wood JLN., Caccamo M., Murcia PR., 2013. Metagenomic study of the viruses of African straw-coloured fruit bats: detection of a chiropteran poxvirus and isolation of a novel adenovirus. *Virology*, 441, 95-106.
15. Yinda CK., Ghogomu SM., Conceicao-Neto N., Beller L., Deboutte W., Vanhulle E., Maes P., Van Ranst M., Matthijnsens J., 2018. Cameroonian fruit bats harbor divergent viruses, including rotavirus H, bastroviruses, and picobirnaviruses using an alternative genetic code. *Virus Evol*, 4, vey008.1-15.
16. Chong R., Shi M., Grueber CE., Holmes EC., Hogg CJ., Belov K., Barrs VR., 2019. Fecal viral diversity of captive and wild Tasmanian Devils characterized using virion-enriched metagenomics and metatranscriptomics. *J Virol*, 93. e00205-19.1-18.
17. Du J., Wang W., Chan JF., Wang G., Huang Y., Yi Y., Zhu Z., Peng R., Hu X., Wu Y., Zeng J., Zheng J., Cui X., Niu L., Zhao W., Lu G., Yuen KY., Yin F., 2019. Identification of a novel ichthyic parvovirus in Marine Species in Hainan Island, China. *Front Microbiol*, 10, 2815.
18. Fahsbender E., Charlys da-Costa A., Elise Gill D., Augusto de Padua Milagres F., Brustulin R., Julio Costa Monteiro F., Octavio da Silva Rego M., Soares D'Athaide Ribeiro E., Cerdeira Sabino E., Delwart E., 2020. Plasma virome of 781 Brazilians with unexplained symptoms of arbovirus infection include a novel parvovirus and densovirus. *PLoS One* 15, e0229993.
19. Li Y., Gordon E., Idle A., Altan E., Seguin MA., Estrada M., Deng X., Delwart E., 2020. Virome of a feline outbreak of diarrhea and vomiting includes Bocaviruses and a Novel Chapparvovirus. *Viruses*, 12, 1-15.
20. Delnatte P., Ojkic D., Delay J., Campbell D., Crawshaw G., Smith DA., 2013. Pathology and diagnosis of avian bornavirus infection in wild Canada geese (*Branta canadensis*), trumpeter swans (*Cygnus buccinator*) and mute swans (*Cygnus olor*) in Canada: a retrospective study.

- Avian Pathol, 42, 114-128.
21. Shanan S., Abd H., Bayoumi M., Saeed A., Sandstrom G., 2015. Prevalence of protozoa species in drinking and environmental water sources in Sudan. *Biomed Res Int*, 2015, 345619.
 22. Tong S., Chern SW., Li Y., Pallansch MA., Anderson LJ., 2008. Sensitive and broadly reactive reverse transcription-PCR assays to detect novel paramyxoviruses. *J Clin Microbiol*, 46, 2652-2658.
 23. VanDevanter DR., Warrener P., Bennett L., Schultz ER., Coulter S., Garber RL., Rose TM., 1996. Detection and analysis of diverse herpesviral species by consensus primer PCR. *J Clin Microbiol*, 34, 1666-1671.
 24. Li L., Deng X., Mee ET., Collot-Teixeira S., Anderson R., Schepelmann S., Minor PD., Delwart E., 2015. Comparing viral metagenomics methods using a highly multiplexed human viral pathogens reagent. *J Virol Methods*, 213, 139-146.
 25. Altan E., Li Y., Sabino-Santos G., Jr. Sawaswong V., Barnum S., Pusterla N., Deng X., Delwart E., 2019. Viruses in Horses with Neurologic and Respiratory Diseases. *Viruses*, 11, 1-12.
 26. Deng X., Naccache SN., Ng T., Federman S., Li L., Chiu CY., Delwart E., 2015. An ensemble strategy that significantly improves de novo assembly of microbial genomes from metagenomic next-generation sequencing data. *Nucleic Acids Res*, 43,7, 20,e46.
 27. Le SQ., Gascuel O., 2008. An improved general amino acid replacement matrix. *Mol Biol Evol*, 25, 1307-1320.
 28. Tamura K., Stecher G., Peterson D., Filipski A., Kumar S., 2013. MEGA6: Molecular Evolutionary Genetics Analysis version 6.0. *Mol Biol Evol*, 30, 2725-2729.
 29. Zadori Z., Szelei J., Lacoste MC., Li Y., Garipey S., Raymond P., Allaire M., Nabi IR., Tijssen P., 2001. A viral phospholipase A2 is required for parvovirus infectivity. *Dev Cell*, 1, 291-302.
 30. Lopez-Bueno A., Mateu MG., Almendral JM., 2003. High mutant frequency in populations of a DNA virus allows evasion from antibody therapy in an immunodeficient host. *J Virol*, 77, 2701-2708.
 31. Kim HR., Kwon YK., Jang I., Bae YC., 2020. Viral metagenomic analysis of chickens with runting-stunting syndrome in the Republic of Korea. *Virol J*, 17, 53.
 32. Lee Q., Padula MP., Pinello N., Williams SH., O'Rourke MB., Fumagalli MJ., Orkin JD., Song R., Shaban B., Brenner O., Pimanda JE., Weninger W., Marciel de Souza W., Melin AD., Wong JLL., Crim MJ., Monette S., Roediger B., Jolly CJ., 2020. Murine and related chapparvoviruses are nephro-tropic and produce novel accessory proteins in infected kidneys. *PLoS Pathog*, 16, e1008262.
 33. Penzes JJ., Soderlund-Venermo M., Canuti M., Eis-Hubinger AM., Hughes J., Cotmore SF., Harrach B., 2020. Reorganizing the family Parvoviridae: a revised taxonomy independent of the canonical approach based on host association. *Arch Virol*, 165(9):2133-2146
 34. Liu W., Zhang Y., Ma J., Jiang N., Fan Y., Zhou Y., Cain K., Yi M., Jia K., Wen H., Liu W., Guan W., Zeng L., 2020. Determination of a novel parvovirus pathogen associated with massive mortality in adult tilapia. *PLoS Pathog*, 16, e1008765.
 35. Roediger B., Lee Q., Tikoo S., Cobbin JCA., Henderson JM., Jormakka M., O'Rourke MB., Padula MP., Pinello N., Henry M., Wynne M., Santagostino SF., Brayton CF., Rasmussen L., Lisowski L., Tay SS., Harris DC., Bertram JF., Dowling JP., Bertolino P., Lai JH., Wu W., Bachovchin WW., Wong JJ., Gorrell MD., Shaban B., Holmes EC., Jolly CJ., Monette S., Weninger W., 2018. An atypical Parvovirus drives chronic tubulointerstitial nephropathy and kidney fibrosis. *Cell*, 175, 530-543 e524.
 36. Hu W., Liu Q., Chen Q., Ji J., 2020. Molecular characterization of Cachavirus firstly detected in dogs in China. *Infect Genet Evol*, 85, 104529.