



ODÜ Tıp Dergisi / *ODU Journal of Medicine*
http://otd.odu.edu.tr

Olgu Sunumu

Case Report

Odu J Med
(2015) 1: 14-e16

Mobile Right Ventricle Thrombosis in Young Adult: Acute Pulmonary Embolus Surgery
Genç Erişkinde Hareketli Sağ Ventrikül Trombüsü: Akut Pulmoner Emboli Cerrahisi

Deniz Demir¹, Cumhuri Murat Tulay², Tuba Yiğit³

Şanlıurfa Mehmet Akif İnan Education and Research Hospital Departments of ¹Cardiovascular Surgery, ²Thoracic Surgery, and ³Anesthesiology, Şanlıurfa/ Türkiye

Yazının geliş tarihi / Received: 27 Ocak 2014 / Jan 27, 2014
Düzeltilme / Revised: 15 Temmuz 2014 / July 15, 2014
Kabul tarihi / Accepted: 18 Temmuz 2014 / July 18, 2014

Abstract

Pulmonary embolism is a life-threatening clinical condition. Although there are well-known risk factors for pulmonary embolism, approximately 1/3 of cases occur without any predisposing factor. Anticoagulation, thrombolysis, catheter embolectomy and surgery are treatment strategies. We wanted to explain a case who had multiple mobile thrombotic masses which extended from right atrium to the right ventricle. Right atriotomy with cardiopulmonary bypass was done to the patient and about 20-30 cc fresh thrombus were taken from the right atrium.

Key Words: Pulmonary embolism, emergency pulmonary embolectomy, ventricular thrombosis

Özet

Pulmoner emboli hayatı tehdit eden klinik bir durumdur. Pulmoner emboli için iyi bilinen risk faktörleri olmasına rağmen, vakaların yaklaşık 1/3'ünde altta yatan predispozan faktör bulunmamaktadır. Antikoagülasyon, tromboliz, katater embolektomi ve cerrahi tedavi seçenekleridir. Biz burada sağ atriumdan sağ ventriküle uzanım gösteren multiple hareketli trombotik lezyonları olan vakamızı sunmak istedik. Kardiyopulmoner bypass ile sağ atriometri uygulanarak yaklaşık 20-30 cc taze trombus sağ atriumdan çıkartıldı.

Anahtar Kelimeler: Pulmoner emboli, acil pulmoner embolektomi, ventriküler tromboz

Introduction

Pulmonary embolism is a life-threatening condition with prevalence about 0.4%. Although old age, deep vein thrombosis, prolonged bed-rest, hypercoagulability, malignancies are well-known risk factors, 30% of cases occur without any predisposing factor.(1) Acute major pulmonary embolism has high mortality rates. While massive pulmonary embolism results of shock condition, right ventricular dysfunction results from submassive form without hemodynamic instability. Anticoagulation with heparin, thrombolysis, catheter embolectomy and open pulmonary embolectomy are treatment strategies.(2) We wanted to explain a case who had life-threatening multiple mobile thrombotic masses detected by echocardiography which extended from right atrium to right ventricle.

Case Report

A 27 year-old male was admitted to emergency service with respiratory distress and chest pain. Deep vein thrombosis which was occurred 2 years ago and 6 months warfarin use were learned from his past medical history. Multiple mobile thrombotic masses detected by echocardiography which extended from right atrium to right ventricle and mean pulmonary artery pressure was 52 mmHg. Hemodynamically stable patient was taken to emergency operation. Right atriotomy with cardiopulmonary bypass was done to patient and about 20-30 cc fresh thrombus were taken from right atrium. Inferior vena cava was approximately occluded by thrombus and it was removed. Pulmonary arteriotomy was done. About 2x2 cm size thrombus was excised from right and left pulmonary artery distinction.(Figure 1) Repeating embolectomies were done by different catheter sizes and too much embolus material were removed from left and right pulmonary arteries. Opened cardiac spaces were washed with heparin. Operation was ended by no macroscopic embolus material. Clinical and hemodynamic evaluations were normal at fourth month after operation and mean pulmonary artery pressure was measured 20-25 mmHg.

Discussion

Pulmonary embolism is a serious pathology which was defined in 1819. Mortality and morbidity are increased by pulmonary embolism. The first successful surgical operation with extracorporeal circulation was reported by Sharp in 1962 (3).

Pleuritic chest pain and dyspnea are the most common symptoms for pulmonary embolism. Deep veins thrombosis of lower extremities is common cause of pulmonary embolism (4). Deep vein thrombosis history was seen in our case. While operative mortality rate of acute massive pulmonary emboli was about 20-57% in the past, it has been changed to 5.3-19% today. Preoperative cardiopulmonary resuscitation, massive or submassive emboli, hemodynamic stability of patient and early surgery are important factors that affect mortality. While mortality is observed 59% of preoperative CPR performed patients, this ratio is decreased to 29% of patient in non-performed ones (5).

In our patient, mobile thrombus which was expanded from right atrium to ventricle by echocardiography and we decided to emergency operation due to life-threatening condition. Mobile right heart ventricle thrombosis is a rare condition and it generally causes mortality (6). We think that early surgery for massive pulmonary emboli with hemodynamic stability decreases mortality rates.

References

1. Jacek K, Jerzy G, Maciej G, Anna C, Marek J. S. Multislice Computed Tomography Angiography as an Imaging Modality of Choice in Patients with Suspicion of Pulmonary Embolism—Own Experiences and Modern Imaging Techniques *Adv Clin Exp Med* 2013, 22, 5, 705–13.
2. Yalamanchili K, Fleisher AG, Lehrman SG, Axelrod HI, Lafaro RJ, Sarabu MR, Zias EA, Moggio RA. Open pulmonary embolectomy for treatment of major pulmonary embolism. *Ann Thorac Surg.* 2004;77(3):819.
3. Yekeler İ, Ateş A, Cerrahoğlu M, Koçak H, Becit N, Karaoğluoğlu N, Başoğlu A, Ateşal S. Akut Pulmoner Embolide İnvaziv Girişim, Erken Embolektomi ve Profilaksi. *Türk Göğüs Kalp Damar Cerrahisi Dergisi.* 1997, 5; 4:286-91.
4. Kadakal F, Çetinkaya E, Yıldız P, Soysal F, Tekin A, Yılmaz V. Klinik Olarak Yüksek Olasılıklı Pulmoner Emboli Olgularında Tanı. *Solunum Hastalıkları* 2000; 11: 140-3.
5. Taniguchi S, Fukuda W, Fukuda I, Watanabe K, Saito Y, Nakamura M, Sakuma M. Outcome of pulmonary embolectomy for acute pulmonary thromboembolism: analysis of 32 patients from a multicentre registry in Japan. *Interact Cardiovasc Thorac Surg.* 2012;14(1):64-7.
6. Kazuki H, Takafumi Y, Daisuke O. Surgical Embolectomy of a Floating Right Heart. Thrombus and Acute Massive Pulmonary Embolism: Report of a Case *Ann Thorac Cardiovasc Surg* 2013; 19: 316–9.

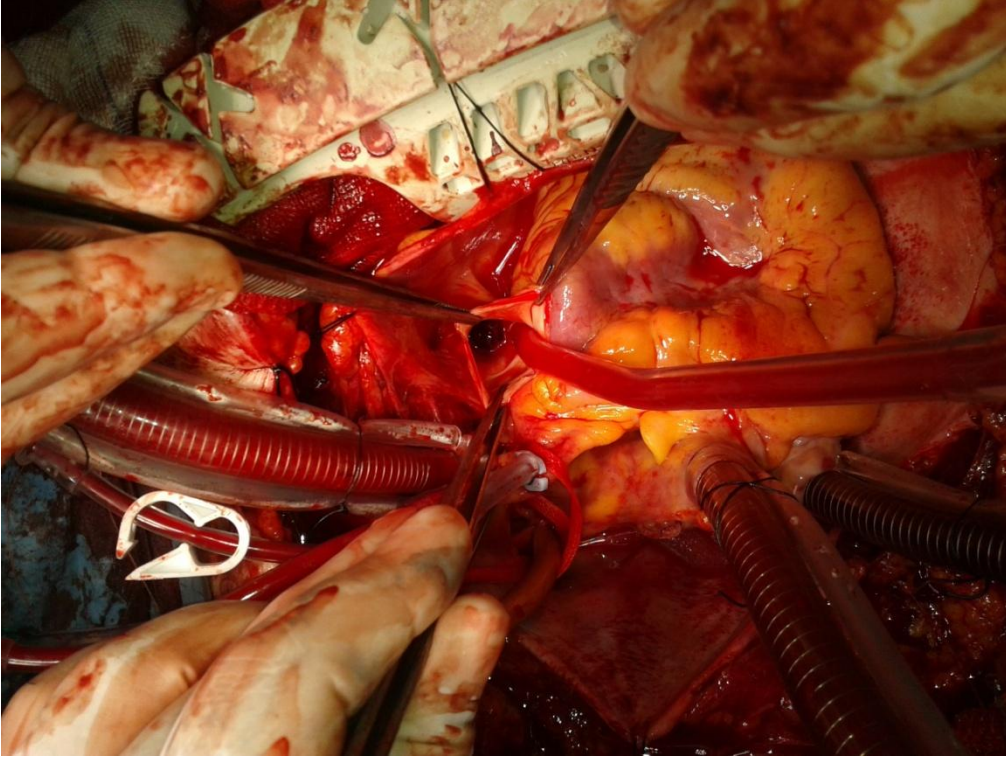


Figure 1: Intraoperative appearance of emboli