

# Examination of craniofacial parameters in Turkish males with golden ratio in piriform aperture size

Seda Sertel Meyvacı<sup>1</sup>, Mustafa Hızal<sup>2</sup>, Handan Ankaralı<sup>3</sup>

<sup>1</sup> Bolu Abant İzzet Baysal University, Faculty of Medicine, Department of Anatomy, Bolu, Turkey

<sup>2</sup> Bolu Abant İzzet Baysal University, Faculty of Medicine, Department of Radiology, Bolu, Turkey

<sup>3</sup> Istanbul Medeniyet University, Faculty of Medicine, Department of Biostatistics and Medical Informatics, Istanbul, Turkey

ORCID ID of the author(s)

SSM: 0000-0002-9450-145X

MH: 0000-0002-4888-0962

HA: 0000-0002-3612-0523

## Corresponding Author

Seda Sertel Meyvacı

Department of Anatomy, Faculty of Medicine,  
Bolu Abant İzzet Baysal University, Gölköy  
Campus, 14030, Bolu, Turkey  
E-mail: sedasertelmeyvacı@gmail.com

## Ethics Committee Approval

Ethical permission was obtained from Bolu Abant İzzet Baysal University, Clinical Research Ethics Board for this study on 29.09.2020 with the decision number of 2020/235.

All procedures in this study involving human participants were performed in accordance with the 1964 Helsinki Declaration and its later amendments.

## Conflict of Interest

No conflict of interest was declared by the authors.

## Financial Disclosure

The authors declared that this study has received no financial support.

## Published

2021 March 19

Copyright © 2021 The Author(s)

Published by JOSAM

This is an open access article distributed under the terms of the Creative Commons Attribution-NonCommercial-NoDerivatives License 4.0 (CC BY-NC-ND 4.0) where it is permissible to download, share, remix, transform, and build upon the work provided it is properly cited. The work cannot be used commercially without permission from the journal.



## Abstract

**Background/Aim:** Piriform aperture, an anatomical structure usually in the form of a pear, is created by the maxilla and nasal bone. The shape and width of PA have significant effects on nasal breathing and are also aesthetically important. In the present study, it was aimed to reveal normal morphometric values by evaluating the craniofacial parameters of young Turkish male cases at the piriform aperture with the help of computerized tomography.

**Methods:** A total of six craniofacial parameters were examined from the 3-dimensional computerized tomography reconstruction images of 103 young adult male cases with golden ratios between the ages of 21 and 30 years. Three indices were calculated from these craniofacial parameters and nine parameters were evaluated. The cases were divided into four groups according to the ratio of the piriform aperture. The descriptive values for the data obtained from craniofacial parameters and indices were calculated as mean and standard deviation. In terms of measurements, the differences between the groups were examined with ANOVA analysis.

**Results:** In our study, there were five cases in the 1<sup>st</sup> group, 39 cases in the 2<sup>nd</sup> group, 38 cases in the 3<sup>rd</sup> group, and 19 cases in the 4<sup>th</sup> group. Two cases were not included in any of the groups. Significant differences were detected between the groups in terms of maximum cranial width, bizygomatic width, nasal width and upper face index parameters ( $P<0.05$ ).

**Conclusion:** Differences were detected between the groups in which craniofacial parameters of all male cases were examined. In the inter-group examination, the craniofacial parameters of only a few cases fit the golden ratio fully. For this reason, we recommend examining the identifying values of the craniofacial parameters of more faces on which the piriform aperture is fully compatible with the golden ratio.

**Keywords:** Golden ratio, Piriform aperture, Facial aesthetics, Craniofacial parameters, Young adult Turkish males

## Introduction

Piriform aperture (PA) is an anatomical structure usually in the form of a pear, created by the maxilla and nasal bone from facial bones [1]. The shape and width of PA have significant effects on the effectiveness of nasal breathing and are also aesthetically important because the PA is at the center of the face [2, 3].

When the limited number of studies conducted on PA were examined in the literature, it was seen that the effects of gender and ethnic differences, particularly morphometric properties, were evaluated [3-5]. Morphometric studies concentrated on PA height and width parameters, and the golden ratio related to these parameters were detected by us in male cases for the first time [6]. Other researchers examining the golden ratio in PA studied the effect of gender and age on this rate [7].

The golden ratio is approximately 1:1.618, which is widely found in nature and is believed to represent an excellent agreement by ancient Greeks. Because of this feature of the golden ratio, there are studies conducted on facial aesthetics [8-10].

In the literature, the morphometric measurements of the parameters of the bony structure of the face were not evaluated among people with the golden ratio. It is also known that facial bones are affected by aging [11]. For this reason, there are no studies limiting the age range of cases and investigating the normal morphometric values of craniofacial parameters of cases with a golden ratio in the face area.

The purpose of this study was to limit the age range in Turkish male cases with the golden ratio in PA, evaluate the craniofacial parameters of young adults with the help of computerized tomography (CT), and determine the normal morphometric measurement values of these parameters.

## Materials and methods

This study was conducted in Bolu Abant Izzet Baysal University, Faculty of Medicine, Department of Radiology. Ethical permission was obtained from Bolu Abant Izzet Baysal University, Clinical Research Ethics Board on 29.09.2020 with the decision number of 2020/235. The principles of the Helsinki Declaration were obeyed when the study was conducted.

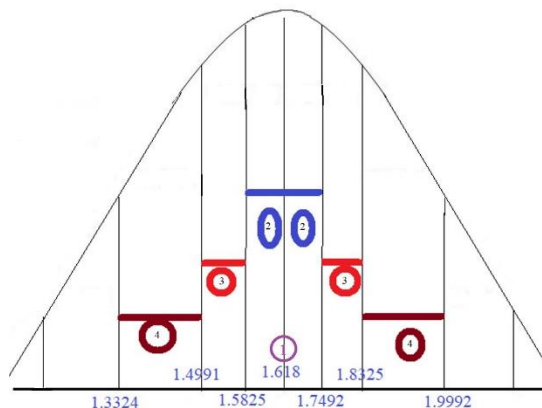
In the literature, studies only include young adult male with a golden ratio of nasal height to PA height (n-ns:rh-ns) [6]. In this study, a total of 103 male cases aged between 21-30 years were evaluated with head CT images. The age range was limited because of the age-related change of the body midface skeleton and the bony tissue on the PA margins [11]. In our previous study [6], the average ratio of nasal height to PA height was calculated as 1.6658 (0.16671), which was presented as the golden ratio. In this study, the cases were divided into 4 groups, considering the deviations from the golden ratio.

- Cases that were fully compatible with the golden ratio (1.618) were included in the first group,
- Cases with values ranging between 1.5825-1.7492 were included in the second group (0.5 standard deviation (SD) from the golden ratio),
- Cases in the third group had a ratio of 0.5 SD to 1 SD from the golden ratio (at least 0.5 SD lower to 1 SD higher) (1.4991-1.8325),

- Cases with ratios of at least 1 SD, at most 2 SD from the golden ratio (1.3324-1.9992) were included in the fourth group.

Groups are graphically summarized in Figure 1.

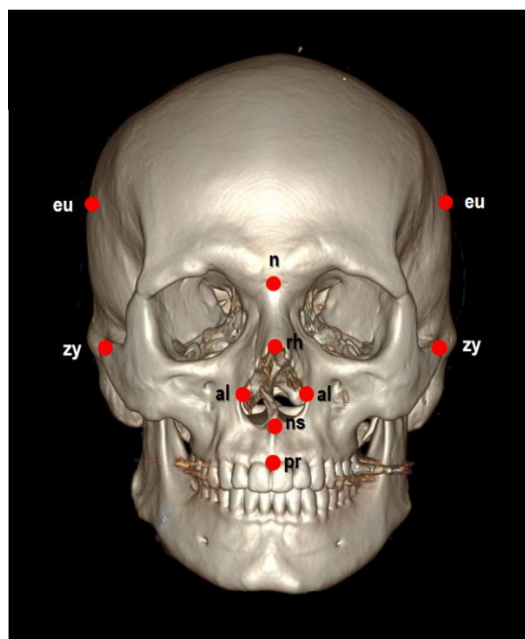
Figure 1: Groups formed by the ratio of nasal height to PA height



The six craniofacial parameters of the cases were measured by a radiologist with 3-Dimensional Computerized Tomography (3D-CT) reconstruction images of the head; and three facial indices were calculated from these measurements.

The seven different anatomical points and abbreviations regarding our parameters are euryon (eu), nasion (n), rhinion (rh), zygion (zy), alare (al), nasospinale (ns) and prosthion (pr), as presented in Figure 2.

Figure 2: Image of 7 different anatomic points in craniofacial skeleton



## CT protocol

All patients underwent CT with 64-slice Multi-Detector CT (MDCT) device (Revolution EVO, GE healthcare, Waukesha, WI, the USA) with the same examination protocol using 64x0.5 mm collimation scanner with a gantry rotation speed of 400 ms/rotation, range of box of 450-500, image thickness of 5 mm, standard pitch factor of 0.641, reconstruction interval of 0.625 mm and a total exposure time of 11 seconds. Each scan was obtained with a tube voltage of 120KV and 320mAs. Images were transferred to a separate workstation (GE, Advantage Workstation 4.4) for measurements.

## Measurements of parameters

A total of 6 different craniofacial parameters were measured in the head 3D-CT reconstruction images [12,13]. The

parameters were measured in millimeters (mm) and had a one-decimal measurement sensitivity. In addition, the age and six craniofacial parameter measurements were recorded for each patient in Excel Program.

**1) Piriform aperture height (rh-ns):** It is the distance between rhinion and nasospinale points.

**2) Nasal height (n-ns):** It is the distance between nasion and nasospinale points.

**3) Upper face height (n-pr):** It is the distance between nasion and prosthion points (Figure 3).

**4) Maximum cranial width (eu-eu):** This measurement, which is also called as maximum transverse width, is the distance between the euryon points on both parietal bones.

**5) Bizygomatic width (zy-zy):** This measurement, which is called face width, is the distance between the zygion points, i.e. the most lateral points on the zygomatic arcs.

**6) Nasal width (al-al):** It is the distance between the most lateral points of nasal alaria (Figure 4).

Figure 3: The representation of the 3 craniofacial parameters on 3D-CT reconstruction: 1) rh-ns; 2) n-ns; 3) n-pr

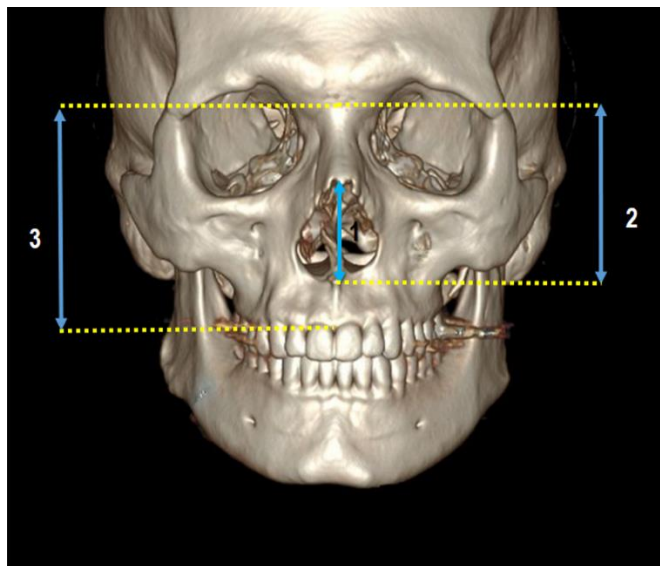
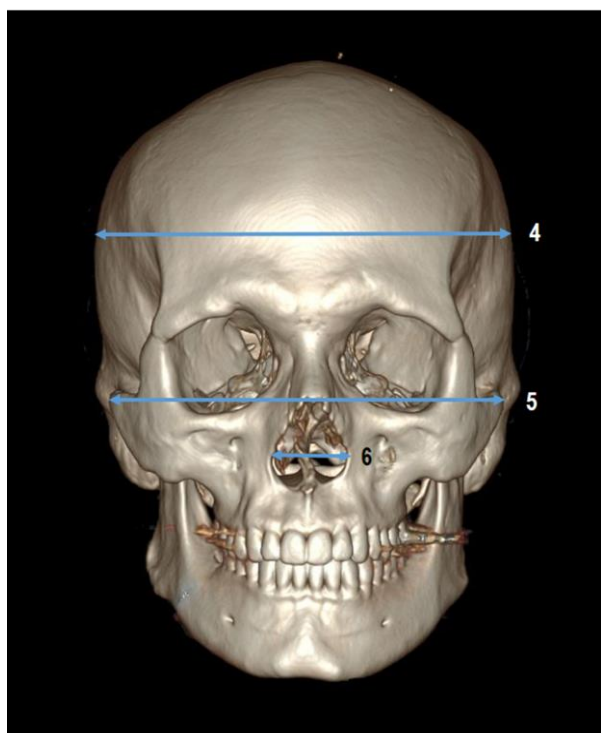


Figure 4: The representation of the 3 craniofacial parameters on 3D-CT reconstruction: 4) eu-eu; 5) zy-zy; 6) al-al



From the six craniofacial parameters measured, three indices were calculated using zy-zy, eu-eu, n-pr, al-al and n-ns parameters.

**The explanations and abbreviations of the three indices calculated:**

**1) Transverse Craniofacial Index (TCFI):** Calculated as  $(zy-zy) / (eu-eu) \times 100$ .

**2) Upper Face Index (UFI):** Calculated as  $(n-pr) / (zy-zy) \times 100$ .

**3) Nasal Index (NI):** Calculated as  $(al-al) / (n-ns) \times 100$ .

**Statistical analysis**

The descriptive values of the data obtained were calculated as mean (Standard deviation). The fitness of the measurements to normal distribution was evaluated with the Kolmogorov-Smirnov Test, and the differences between the groups were examined with the ANOVA Model. Significant differences were determined with the Post-Hoc Tukey Test.  $P < 0.05$  was considered significant, and the SPSS (ver. 23) Program was used for calculations.

**Results**

A total of 103 cases aged between 21-30 years were examined in four groups. There were five cases in the 1<sup>st</sup> group, 39 cases in the 2<sup>nd</sup> group, 38 cases in the 3<sup>rd</sup> group, and 19 cases in the 4<sup>th</sup> group. Two cases were not included in any of the groups. The descriptive values of all cases are presented in Table 1.

The cases were grouped considering the mean and standard deviation values of the golden ratio index of PA. In the 1<sup>st</sup> group, the mean age of five patients who fully complied with the golden ratio of 1.618 was 27.80 (3.35) years. The craniofacial parameters of these cases are presented in Table 2.

Table 1: The descriptive values of 103 cases with the golden ratio

n=103	Mean	SD	Minimum	Maximum
Age (years)	25.45	3.58	21	30
Golden ratio (n-ns:rh-ns)	1.667	0.14	1.368	2.019
rh-ns (mm)	32.34	2.23	25.60	38.90
n-ns (mm)	53.65	2.41	49.10	64.60
n-pr (mm)	73.78	3.66	66.90	85.40
eu-eu (mm)	152.87	6.80	137.10	167.80
zy-zy (mm)	139.94	5.17	124.70	150.60
al-al (mm)	24.11	1.80	20.30	27.90
TCFE (zy-zy:eu-eu)	91.60	2.43	86.05	97.00
UFI (n-pr:zy-zy)	52.76	2.65	47.61	61.46
NI (al-al:n-ns)	45.01	3.53	35.30	51.06

SD: Standard Deviation

Table 2: The descriptive values of the craniofacial parameters and indices of the male cases in group 1

n=5	Mean	SD	Minimum	Maximum
Golden ratio (n-ns:rh-ns)	1.6143	0.0023	1.6110	1.6161
rh-ns (mm)	32.82	0.63	32.30	33.60
n-ns (mm)	52.95	1.00	52.10	54.30
n-pr (mm)	72.44	3.60	67.90	77.50
eu-eu (mm)	154.36	7.15	147.20	165.30
zy-zy (mm)	139.24	4.59	135.90	147.20
al-al (mm)	23.88	1.45	21.70	25.60
TCFE (zy-zy:eu-eu)	90.26	1.99	88.58	92.55
UFI (n-pr:zy-zy)	52.02	1.60	49.27	53.46
NI (al-al:n-ns)	45.09	2.98	41.33	49.04

The mean age of 39 individuals in Group 2, who had the closest value to the golden ratio, was 24.97 (3.55) years. The craniofacial parameters of these cases are given in Table 3.

In the 3<sup>rd</sup> group, there were 38 cases with a mean age of 25.79 (3.50) years. The craniofacial parameters of these cases are given in Table 4.

Group 4 comprised 19 cases with a mean age of 24.89 (3.90) years. The craniofacial parameters of these cases are presented in Table 5.

Table 3: The descriptive values of the craniofacial parameters and indices of the male cases in group 2

n=39	Mean	SD	Minimum	Maximum
Golden ratio (n-ns:rh-ns)	1.6587	0.0568	1.583	1.744
rh-ns (mm)	32.04	1.36	28.20	35.00
n-ns (mm)	53.08	1.59	49.10	58.90
n-pr (mm)	74.04	2.95	68.60	79.10
eu-eu (mm)	155.67	7.50	137.10	167.80
zy-zy (mm)	141.75	4.43	130.40	148.50
al-al (mm)	23.53	1.59	20.80	26.30
TCFE (zy-zy:eu-eu)	91.15	2.11	88.34	95.36
UFI (n-pr:zy-zy)	52.24	1.71	49.68	58.47
NI (al-al:n-ns)	44.36	3.30	37.01	50.00

SD: Standard Deviation

Table 4: The descriptive values of the craniofacial parameters and indices of the male cases in group 3

n=38	Mean	SD	Minimum	Maximum
Golden ratio (n-ns:rh-ns)	1.6256	0.1197	1.504	1.820
rh-ns (mm)	33.08	1.78	29.20	37.40
n-ns (mm)	53.59	2.09	50.50	58.40
n-pr (mm)	72.89	3.14	66.90	79.10
eu-eu (mm)	151.82	5.35	142.10	161.00
zy-zy (mm)	139.28	5.33	124.70	150.60
al-al (mm)	24.69	1.55	21.10	27.00
TCFE (zy-zy:eu-eu)	91.77	2.64	86.09	97.00
UFI (n-pr:zy-zy)	52.39	2.88	47.61	61.46
NI (al-al:n-ns)	46.13	3.25	36.30	51.06

Table 5: The descriptive values of the craniofacial parameters and indices of the male cases in group 4

n=19	Mean	SD	Minimum	Maximum
Golden ratio (n-ns:rh-ns)	1.7444	0.2296	1.368	1.996
rh-ns (mm)	31.59	3.84	25.60	38.90
n-ns (mm)	54.35	3.14	50.10	60.90
n-pr (mm)	74.40	4.61	68.50	84.50
eu-eu (mm)	148.93	6.05	138.30	160.60
zy-zy (mm)	137.46	5.62	125.90	147.50
al-al (mm)	23.97	2.33	20.30	27.90
TCFE (zy-zy:eu-eu)	92.33	2.59	86.05	96.49
UFI (n-pr:zy-zy)	54.15	3.02	49.68	59.29
NI (al-al:n-ns)	44.19	4.35	35.30	50.80

Two cases with a mean age of 27.50 (2.12) years were incompatible with the golden ratio and not included in the study groups. The craniofacial parameters of these cases were as follows: n-ns:rh-ns: 2.0111±0.0108, rh-ns: 30.25±2.47 mm, n-ns: 60.85±5.30 mm, n-pr: 83.25±3.04 mm, eu-eu: 152.15±0.07 mm, zy-zy: 142.20±0.85 mm, al-al: 26.60±0.28 mm, TCFE: 93.46±0.51, UFI: 58.54±1.79 and NI: 43.86±3.36.

The mean ages of the groups were similar ( $P=0.374$ ). In terms of all the parameters that were examined, the mean values of only group 4 were significantly lower in terms of eu-eu measurements compared to the mean values of the 1<sup>st</sup> and 2<sup>nd</sup> groups ( $P=0.005$ ). In terms of the other parameters (i.e. zy-zy measurements), the mean value of only group 4 was significantly lower than the mean value of the 2<sup>nd</sup> group ( $P=0.033$ ). In terms of al-al measurements, which is the PA width, the mean value of group 3 was significantly higher than the other groups ( $P=0.014$ ). The mean UFI value of group 4 was significantly higher compared to the 1<sup>st</sup>, 2<sup>nd</sup>, and 3<sup>rd</sup> groups ( $P=0.001$ ). No significant differences were detected between the groups in terms of other features not defined above ( $P>0.05$ ).

## Discussion

Anthropometry is the biological science of human body measurements [14]. Radiological imaging methods in anthropometric studies are modern methods which decrease the time and costs needed for analyses [15]. In our study, the purpose was to examine the craniofacial parameters of male cases with a golden ratio in the PA skeleton with the help of CT, and to interpret the relations of these parameters with different golden ratio groups.

According to the results of our study, differences were found in eu-eu, zy-zy, al-al, and UFI values among the four groups.

The n-ns:rh-ns indices in AP were fully compatible with the golden ratio in five individuals who were included in Group 1 (4.85%). The distribution frequency of the cases with a similar golden ratio index was not equal among the other three groups. However, the craniofacial parameters of all young adult males in four groups varied among the groups except for 2 cases that were not compatible with the golden ratio.

Studies that investigate PA in morphometric terms are limited in the literature. The golden ratio in PA was first detected in our study [6]. The study of Kabakci et al. [7] on the golden ratio was conducted considering the effects of age and gender on the index between PA height and PA width. It was found that although there was no difference between the genders in this index, there was a difference between age groups. This shows that the PA skeleton is affected by age. In our study, the normative data of the craniofacial parameters were obtained by limiting the age range of the cases by ensuring that the measurement values of the craniofacial skeleton may be affected by age.

In another study conducted with the help of CT on PA, PA height, PA width and the indices between PA height and PA width were evaluated in 120 cases [16]. In this study, a difference was detected between gender groups in terms of PA height, PA width and PA height and PA width. Only the nasal bone sizes were examined as craniofacial parameters in male cases in which the PA length was 3.34±0.29 cm. In a different study conducted with the help of CT, the PA length was 38.24±7.82 mm [17]. In the study investigating the upper and lower width of PA according to age groups, the mean PA subwidth was 23.6±0.5 mm among males [2]. Other studies assessing the PA width did not evaluate the craniofacial parameters [18, 19].

In the present study, the age range was limited, and individuals between 21 and 30 of age were included. In other studies, the age ranges were very wide [16-19]. Hommerich et al. [2] conducted a study and found that the mean of the data varied with age after they categorized their cases in terms of age into groups of ten. The PA subwidth was 23.6 mm on average among male cases. In our study, PA width was 23.29±1.86 mm and PA height was 32.74±2.94 mm. Although the age ranges in these studies were different, the results were similar to ours except for the value of PA width parameter reported in the study of Abdelaleem et al. [17].

Dry bone studies of craniofacial parameters on the cranium investigated the distance between the anthropometric points of 149 male craniums, revealing a range of 43.41±12.88 mm, and the following mean values: eu-eu: 140.86±10.76 mm, n-ns: 51.25±3.88 mm, n-pr: 68.85±5.41 mm, zy-zy: 127.02±5.97 mm and al-al: 25.83±2.72 mm [20].

In another study, the parameters of 44 male craniums with unknown age were evaluated, and the following values were reported: zy-zy: 128.9±4.41 mm, rh-ns: 53.7±3.54 mm, al-al: 24.8±2.21 mm and n-pr: 71.3±3.91 mm. The craniofacial parameters of 90 males with a high average age (68.94 (13.41) years) were examined to yield the following values: zy-zy: 130.54±5.13 mm, n-pr: 69.38±6.56 mm, al-al: 23.98±2.54 mm and rh-ns: 51.60±3.04 mm [13]. The fact that the measurements

were not performed with the help of CT, the variety of anatomical points to measure, and the different age range make the study results difficult to compare. In our study, these parameters were as follows: rh-ns:  $32.34 \pm 2.23$  mm, n-ns:  $53.65 \pm 2.41$  mm, n-pr:  $73.78 \pm 3.66$  mm, zy-zy:  $139.94 \pm 5.17$  mm, al-al:  $24.11 \pm 1.80$  mm and eu-eu:  $152.87 \pm 6.80$  mm.

Some researchers analyzed craniofacial skeletal parameters; however, until now, no studies evaluated the craniofacial parameters and relevant indices of the cases with a golden ratio in the face.

The present study provided new data for the analysis and interpretation of the anatomical characteristics of craniofacial parameters of male young adults with the golden ratio at the center of the facial skeleton. Detailed data are provided in our results for professionals interested in plastic surgery, maxillofacial surgery, and anthropometry with a better understanding of this complex clinical anatomic area, which has aesthetic significance.

### Conclusion

The descriptive values of the craniofacial parameters of young adult Turkish males with a golden ratio in PA were determined with the results of our study. Differences were found in some craniofacial parameters between the groups. In this inter-group study, the craniofacial parameters of only five males fully met the golden ratio at PA. We recommend that further studies are conducted with an increased number of individuals with golden ratios at PA and the descriptive values of the craniofacial parameters of these cases are examined.

### References

1. de Araújo TMS, da Silva CJT, de Medeiros LKN, Estrela Y da CA, Silva N de A, Gomes FB, et al. Morphometric analysis of piriform aperture in human skulls. *Int J Morphol*. 2018;36:483–7. doi: 10.4067/S0717-95022018000200483.
2. Hommerich CP, Riegel A. Measuring of the piriform aperture in humans with 3D-SSD-CT-reconstructions. *Ann Anat*. 2002;184:455–9. doi: 10.1016/S0940-9602(02)80078-4.
3. Moreddu E, Puymerail L, Michel J, Achache M, Dessi P, Adalian P. Morphometric measurements and sexual dimorphism of the piriform aperture in adults. *Surg Radiol Anat*. 2013;35:917–24. doi: 10.1007/s00276-013-1116-2.
4. Asghar A, Dixit A, Rani M. Morphometric study of nasal bone and piriform aperture in human dry skull of Indian origin. *J Clin Diagnostic Res*. 2016;10:AC05–7. doi: 10.7860/JCDR/2016/15677.7148.
5. McDowell JL, L'Abbé EN, Kenyhercz MW. Nasal aperture shape evaluation between black and white South Africans. *Forensic Sci Int*. 2012;222:397.e1–397.e6. doi: 10.1016/j.forsciint.2012.06.007.
6. Serel Meyvaci S, Kosif R, Bamaç B, Hizal M, Ankarali H. Evaluation of apertura piriformis and related cranial anatomical structures through computed tomography: Golden ratio. *Folia Morphol*. 2019;78:839–46. doi: 10.5603/FM.a2019.0021.
7. Kabakci AG, Polat S, Öksüzler M, Öksüzler FY, Yücel AH. The determination of the piriform aperture morphology and golden ratio in healthy Turkish subjects. A CT study. *Int J Morphol*. 2020;38:444–7. doi: 10.4067/S0717-95022020000200444.
8. Prokopakis EP, Vlastos IM, Picavet V, Trenité GN, Thomas R, Cingi C, et al. The golden ratio in facial symmetry. *Rhinology* 2013;51:18–21. doi: 10.4193/Rhino12.111.
9. Williams K. Bülent Atalay: Math and the Mona Lisa. *Nexus Netw J*. 2005;7:113–5. doi: 10.1007/s00004-005-0027-x.
10. Hicks KE, Thomas JR. The Changing Face of Beauty: A Global Assessment of Facial Beauty. *Otolaryngol Clin North Am*. 2020;53:185–94. doi: 10.1016/j.otc.2019.12.005.
11. Jeon A, Sung KH, Kim SD, Lee UY, Lee JH, Han SH, et al. Anatomical changes in the East Asian midface skeleton with aging. *Folia Morphol*. 2017;76:730–5. doi: 10.5603/FM.a2017.0027.
12. Key PJ. Craniometric Relationships Among Plains Indians 1983;T2-A2:1-189 PB-University.
13. Kranioti EF, İçcan MY, Michalodimitrakis M. Craniometric analysis of the modern Cretan population. *Forensic Sci Int*. 2008;180:110.e1–110.e5. doi: 10.1016/j.forsciint.2008.06.018.
14. Studies BC. Development and Comparison of Anthropometric Ratios 2012;23:75–83. doi: 10.1097/SCS.0b013e3182468612.
15. Ekizoglu O, Hocaoglu E, Inci E, Can IO, Solmaz D, Aksoy S, et al. Assessment of sex in a modern Turkish population using cranial anthropometric parameters. *Leg Med*. 2016;21:45–52. doi: 10.1016/j.legalmed.2016.06.001.
16. Yüzbaşıoğlu N, Yılmaz MT, Çicekcibasi AE, Seker M, Sakarya ME. The evaluation of morphometry of nasal bone and pyriform aperture using multidetector computed tomography. *J Craniofac Surg*. 2014;25:2214–9. doi: 10.1097/SCS.0000000000001063.
17. Abdelaleem SA, Younis RHA, Kader MA. Sex determination from the piriform aperture using multi slice computed tomography: Discriminant function analysis of Egyptian population in Minia Governorate. *Egypt J Forensic Sci*. 2016;6:429–34. doi: 10.1016/j.ejfs.2016.11.003.
18. Karadağ D, Özdoğru NC, Beriat K, Akinci T. CT evaluation of the bony nasal pyramid dimensions in Anatolian people. *Dentomaxillofacial Radiol*. 2011;40:160–4. doi: 10.1259/dmfr/35578628.
19. Zamani Naser A, Panahi Boroujeni M. CBCT Evaluation of Bony Nasal Pyramid Dimensions in Iranian Population: A Comparative Study with Ethnic Groups. *Int Sch Res*. Not 2015;1–5. doi: 10.1155/2014/819378.
20. Sexual D, Lineales D, Alejandra D, Matamala Z. Sexual Dimorphism Determination From The Lineal Dimensions of Skulls. *Int J Morphol*. 2009;27(1):133–7.