



ODÜ Tıp Dergisi / *ODU Journal of Medicine*
http://otd.odu.edu.tr

Araştırma Yazısı

Odu Tıp Derg
(2016) 3:1-7

Research Article

Odu J Med
(2016) 3:1-7

Does Climate Affect the Presence of Retention Cysts in the Maxillary Sinus?
İklim Maksiller Sinüste Retansiyon Kisti Varlığını Etkiler mi?

Mehmet Melih Omezli¹, Damla Torul², Mehmet Emrah Polat³, Ferhat Ayrancı¹, Ertunc Dayı³

¹Ordu University, Department of Oral and Maxillofacial Surgery, Ordu, Turkey

²Ondokuz Mayıs University, Department of Oral and Maxillofacial Surgery, Samsun, Turkey

³Ataturk University, Department of Oral and Maxillofacial Surgery, Erzurum, Turkey

Yazının geliş tarihi / Received: 20 Eylül 2014/Sep 20, 2014

Kabul tarihi / Accepted: 25 Şubat 2015/Feb 25, 2015

Abstract

Purpose: The aim of this study was to investigate the influence of climate on the prevalence of retention cysts (RCs) in different geographical regions by comparing the prevalence of RCs in a Turkish patient population in the Black Sea and Eastern Anatolian regions. **Materials and Methods:** Patients were scanned using panoramic radiographs. Panoramic radiographs of 17,659 patients from the archives of two centers were reviewed. **Results:** The prevalence of RCs was 1,6 % in the Black Sea region and 0,4 % in the Eastern Anatolian region. Males were affected more than females and there was no correlation observed between age groups in either study group. A total of 169 RCs were detected with a mean size of 3,7 cm² in the Black Sea region while 37 RCs were detected in the Eastern Anatolian region with a mean size of 7 cm². Most of the patients from the two centers were dentate and had dental pathologies in the teeth adjacent to the sinus. The correlation between cyst size and patient age was not significant. **Conclusion:** This paper shows that RCs were more prevalent in the geographical regions that have higher temperature.

Keywords: Geographic location, maxillary sinus, mean temperature, retention cyst

Özet

Amaç: Bu çalışmanın amacı farklı coğrafik bölgelerde retansiyon kistlerinin prevalansı üzerinde iklimin etkisinin Karadeniz ve Doğu Anadolu Bölgelerindeki retansiyon kistlerinin prevalansları karşılaştırılarak araştırılmasıdır. **Yöntem:** Çalışmada iki merkezin arşivlerindeki 17,659 hastanın panoramik radyografileri değerlendirilmiştir. **Bulgular:** Retansiyon kistinin prevalansı Karadeniz Bölgesinde % 1,6 Doğu Anadolu Bölgesinde ise % 0,4 olarak bulunmuştur. Erkekler kadınlardan daha fazla etkilenmiştir ve iki bölgede de yaş grupları arasında herhangi bir korelasyon bulunamamıştır. Karadeniz Bölgesinde ortalama büyüklüğü 3,7cm² olan 169 retansiyon kisti, Doğu Anadolu Bölgesinde ortalama büyüklüğü 7cm² olan 37 retansiyon kisti bulunmuştur. İki merkezde de hastaların çoğu dişlidir ve çoğunun sinüse komşu dişlerinde dental patolojiler mevcuttur. Kist büyüklüğü ve hasta yaşı arasında anlamlı bir korelasyon saptanamamıştır. **Sonuç:** Bu çalışma sıcaklığın yüksek olduğu coğrafik bölgelerde retansiyon kistlerinin daha yaygın olduğunu göstermektedir.

Anahtar kelimeler: Coğrafik konum, maksiller sinüs, ortalama sıcaklık, retansiyon kisti

Introduction

The maxillary sinus is the largest of the paranasal sinuses and is subject to various pathologies that are often discovered incidentally during routine radiographic examinations (1-3). The most common incidental pathology observed in the maxillary sinus is retention cysts (RCs) with a reported incidence of 1,4 % to 35,6 % (4, 5,7-10). RCs occur as a result of a partial blockage of the seromucinous glands in the sinus lining and are induced by a prolong inflammation of the sinus mucosa. RCs often contain clear, yellowish fluid (6,7). Radiographically, these lesions are described as a round, ovoid, or dome-shaped shadow of uniform density within the maxillary sinus and continuous with the floor or wall of the sinus (1, 4, 7).

Retention cysts are generally asymptomatic lesions and need no treatment (5,8,9). Approximately 17,6 % to 38 % of RCs rupture and clear up spontaneously (10). Occasionally, they are related to a variety of symptoms including headache or facial pain, nasal obstruction, nasal discharge, and sinusitis (6,7). The pathogenesis of these lesions still remains unclear; however, allergies, barotraumas, dental disease, rhinitis, sinusitis, and smoking have all been shown to be etiologic factors contributing to the development of RCs (3,5). Several investigators have also emphasized an environmental cause for the formation of RCs, such as upper respiratory infections in the late winter period, air conditioning and air pollution or dust (11-13). To our knowledge, there have been no previous studies that investigated the relationship between the occurrence of RCs and climate by comparing the prevalence of RCs in various geographical regions.

The aim of this study was therefore to investigate the influence of the climate on the occurrence of RCs by comparing the prevalence of RCs in the Black Sea and Eastern Anatolian regions. To accomplish this goal, we used panoramic radiographs from the archives of the two centers. We also evaluated the other possible risk factors of RCs.

Materials and Methods

The present retrospective study reviewed panoramic radiographs obtained from the patients who presented to the Oral and Maxillofacial Surgery Services of Ordu University Faculty of Dentistry and Ataturk University Faculty of Dentistry. The first study group consisted of 9,659 patients from Ordu in the Black Sea region that has a mean temperature of 15,3 °C and an altitude of 3 m. The second group consisted of 8,000 patients from Erzurum in the Eastern Anatolian region that has a mean temperature of 6 °C and an altitude of 1,890 m. Patients in both study groups consisted of only urban

residence from the two centers and aged between 10 to 90 years old were included in the study. Images of low resolution quality and/or those in which the presence of artifacts impaired sinus visualization were excluded from study. The study design was approved by the Ordu University Ethics Committee (protocol no. 2013/35).

The panoramic radiographs in Ordu University were obtained using a Kodak 8000C Digital Panoramic and Cephalometric Extraoral Imaging System (Kodak Dental Systems, Rochester, NY). A Planmeca PM 2002 CC (Planmeca Oy, Helsinki, Finland) was used in Ataturk University. The panoramic radiographs from the archives of two centers were reviewed and discussed by the same

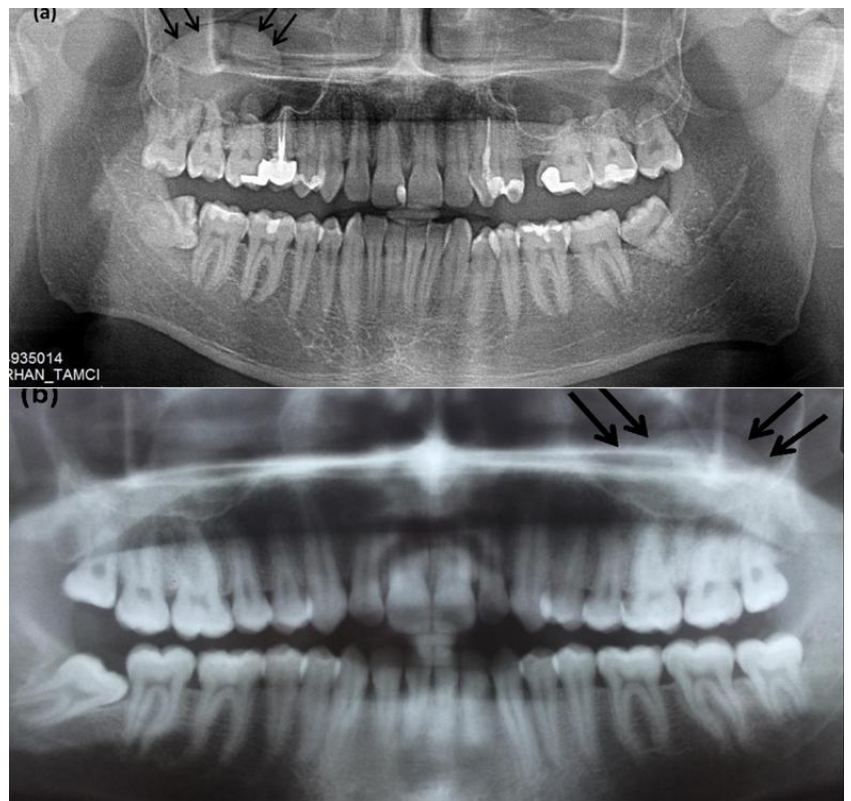

Figure 1. A: A panoramic radiograph showing the typical appearance of Retention Cyst in the right maxillary sinus. (arrow). B: A panoramic radiograph showing the typical appearance of Retention Cyst in the left maxillary sinus (arrow).

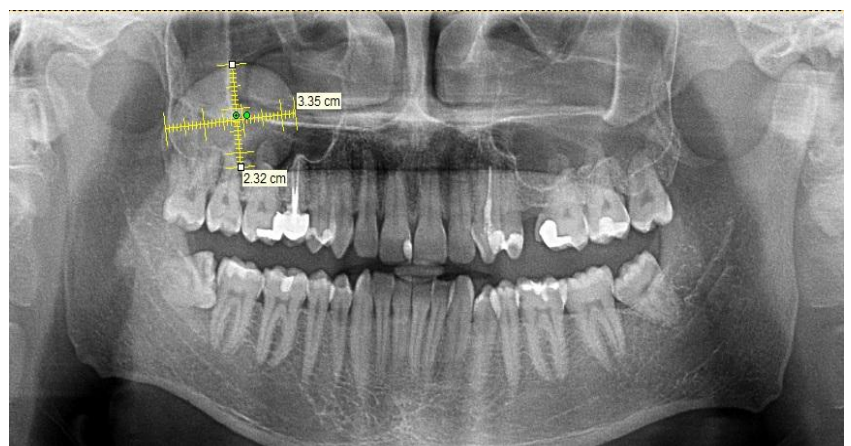
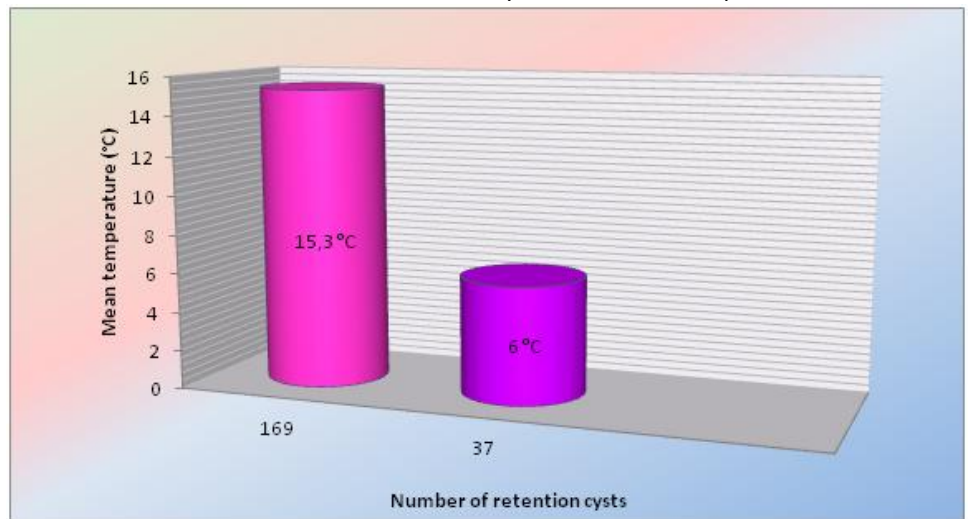


Figure 2. Measurement of Retention Cyst on panoramic radiograph

group of researches. RCs on each image were radiologically diagnosed from the appearance of a uniformly dense dome-shaped shadow of variable sizes arising from the wall or floor of the maxillary sinus (Figure 1a and 1b). RCs characteristics that were analyzed included the location, number, and size. Superoinferior and lateromedial measurements of RCs were made on panoramic radiographs by using a digital archiving system (Turcasoft Dent, Samsun, Turkey) at Ordu University (Figure 2). At Atatürk University, measurements were done manually according to the longest dimensions of the cyst. Data on mean temperatures and altitudes in the two Turkish cities were supplied by TUMAS (Turkish Meteorological Service Data Archiving System) and the temperatures were reported as the mean for the last five years. The age and gender of the patients, side of the RCs within the sinus, dental pathologies (caries, fillings, and root-canal fillings) in the teeth adjacent to the RCs, size of the RCs, and the number of RCs were recorded for comparisons between the two centers. For statistical analysis, patients were classified into the following age groups: 10–19, 20–29, 30–39, 40–49, 50–59, and ≥ 60 years. Results were recorded and statistically analyzed using the SPSS package (11.0; SPSS Inc., Chicago, IL, USA). The Pearson correlation coefficient was used to correlate size of RCs with patient age. One-way Anova was used to correlate the size of the cyst with age groups. To compare the prevalence of RCs in two regions Two-proportion Z-test was used. To investigate the relation between the frequency of RCs and the age groups Chi-square analysis was used. Student t-test was used for the comparison of the cyst size between two regions. $P < 0,05$ probability value was considered as significant.


The age of the patients ranged from 10 to 78 years with a mean of 33 years in Ordu and in Erzurum, ages ranged from 11 to 74 years with a mean of 31 years. In both regions, male patients showed more RCs than female patients. The male-to-female ratio was 1,4: 1 and 2,3: 1,3 in Ordu and in Erzurum, respectively. Within the age groups, the highest number of RCs was found for the groups aged between 30 to 39 years in Ordu and 20 to 29 years in Erzurum; however, no statistically significant differences were found between age groups ($P=0,329$). The size of the RCs measured on panoramic radiographs ranged from 0,8 to 9,5 cm^2 with a mean of 3,7 cm^2 in Ordu. We also observed that the RC sizes increased with age in Ordu. However, this finding was not statistically significant. In Erzurum the size of the RCs measured on panoramic radiographs ranged from 1,7 to 12 cm^2 with a mean of 7 cm^2 ; in this case, we observed no correlation between the patient's age and the size of the RCs. The size of RCs was found significantly large in Erzurum ($P < 0,001$), (Graph 2). In both study groups, the majority of RCs appeared on the floor of the maxillary sinus. Statistical analysis shows that the prevalence of RCs was



Graph 1. Distribution of retention cysts among two regions

Results

A total of 17,659 radiographs were obtained and reviewed from patients in two different regions of Turkey that have different mean temperatures and altitudes. There were 8,000 patients from the Eastern Anatolian region (Erzurum) and RCs were observed in 36 (23 males and 13 females) of them with a frequency of 0,4 %. From the Black Sea region (Ordu), there were 9,659 patients and RCs were observed in 158 (94 males and 64 females) of them with a frequency of 1,6 %. A total of 169 RCs were detected in Ordu while a total of 37 RCs were detected in Erzurum (Graph 1).



Graph 1. Relation of the mean cyst size with the number of RCs and the mean temperature

significantly higher in the Black Sea region where the mean temperature was higher (Table 1). The distribution of RCs, with regard to location, dental pathologies, and dental status are shown in Table 2.

Discussion

Retention cysts are common incidental findings in the paranasal sinuses and are mostly seen in the maxillary sinus (4-5). These cysts are the second most common inflammatory lesions of the maxillary sinus, after mucosal thickening (14). The formation of these lesions results from an inflammatory period when the duct of a seromucinous gland is partially blocked, causing the dilatation of the duct forming it into an epithelial-lined true cystic structure (5,6,13). These cystic structure often involves a thin, clear, yellowish, amber, or straw-colored fluid that has a chemical composition similar to blood serum and frequently consists of cholesterol crystals as with odontogenic cysts (7). Because of the location of the seromucinous glands, which are plentiful around the ostium of the maxillary sinus, RCs could occur in that region (15). On the other hand, probably as a result of gravity and/or the proliferation of the gland, the sinus region for the majority of these lesions is on the floor of the maxillary sinus (7,15), approximately 40 mm from the ostium (9).

RCs are usually present in the second or third decade of life (16,19) and are more prevalent among males (7,13,16). Since the developments of the paranasal sinuses are incomplete at younger ages, these cysts are fairly rare in childhood (17). These lesions are often diagnosed accidentally on plain radiographs or with cross-sectional images that are obtained for other reasons, such as dental rehabilitation, impacted teeth, or to assess the alveolar ridge for implantation (18). The radiographic appearance of retention cyst is typically described as a round, ovoid, or dome-shaped shadow (1,4,7) and different from odontogenic cysts RCs have no cortical bonding (17). In most previous studies, different types of imaging modalities were used to investigate the prevalence of RCs (4,12,18). However, other than certain limitations (19), panoramic radiography is still used as a routine screening tool for the evaluation of the maxillomandibular complex because of its low cost, availability and ease of interpretation (8,17,20).

Although the majority of RCs are asymptomatic and are therefore incidental findings, some may give rise to discomfort such as headache, facial pain (7,21), postnasal drip and nasal discharge (6), toothaches (1), and rarely, an ocular disturbance (8). Wang et al. (10) reported nasal obstructions in 52,5 %, nasal discharge in 35,7 %, and headaches in 2,5 % of patients with RCs. In another study by Busaba and Kieff (22), facial pain or pressure in the sinus area was observed in all of the patients with RCs. A rare case of an RC causing pain on the infraorbital nerve

was reported by Ence and Parsons (21). Unfortunately, the pathogenesis of these lesions is still not fully understood. Local factors such as allergies, barotraumas, dental diseases, rhinitis, sinusitis, and smoking have been considered as factors that may induce the formation of these lesions (5). Also, upper respiratory infections in the late winter period, air conditioning, air pollution or dust, and the mean temperature are considered to be among predisposing environmental factors for the genesis of these lesions (12,13,16-18).

The incidence of RCs among previous studies was slightly higher in men than in women, with a reported male-to-female ratio of approximately 2:1 (7,13,16). The reason for this is still unclear but some possibilities were reported. According to MacDonald-Jankowski (23), the reason RCs are mostly detected in men is that men are out working and are exposed to high humidity and air pollution more than women, who are generally at home. Similarly, Vallo et al. (17) reported that men were being exposed to respiratory infections during their national service and therefore, had more sinus findings than women. In the present study, we found men had the majority of RCs in both study groups. We suggest the reason for the men's predominance in our study may be that men and women in Turkey generally have different working environments and outdoor activities. Another reason for the male predominance may be that the consumption of tobacco was more prevalent among the men in Turkey.

The reported size of RCs ranged from 1,0 to 15 cm² (8). In the present study, the mean size of the RCs was 3,7 cm² in Ordu (Black Sea region) and 7 cm² in Erzurum (Eastern Anatolian region). When compared, the mean size in Erzurum was larger than the sizes reported in most of the previous studies (8,16,18), and also larger than the mean size in Ordu where the mean temperature is higher. According to this finding it can be said that the size of the retention cyst not correlate with the temperature. The relationship between age groups and cyst size was not significant in this study. Similarly, Casamassimo and Lilly (16) reported that there was no relationship between cyst size and patient age. However, the same authors observed a positive association between the dental disease severity and the cyst size. Contrary to this, MacDonald-Jankowski (8) reported that the size of RCs are not affected by dental tissue pathologies. RCs generally remain the same size, or the size may decrease and disappear over time, as reported in several studies (10, 16, 20). Wang et al. (10) observed that 50 % of the RCs in their study decreased and disappeared; they also reported that if the RC increases significantly in size after four years, it is likely to increase further and should be kept under observation.

The relationship between the prevalence of RCs and the climate was not clear among previous papers (5,8,17). Casamassimo and Lilly (16) observed the cysts predominantly in the late winter period, which is when

upper respiratory infections are mostly seen. A similar correlation was suggested by Ruprecht (13) who reported that the variation in prevalence favoring the last quarter of the year in North America, might be due to an increased incidence in the common cold. In contrast, patients in Riyadh, where there is a mild winter season, did not show this correlation (13,24). Also, Gardner (15) and Rodrigues et al. (11) observed no correlation between RCs and mean temperature, similar to the findings in Riyadh. In the present study, we compared the prevalence of RCs in two Turkish cities that are in different geographical locations and found that the prevalence of RCs was higher in Ordu, where the mean temperature was higher. Therefore, this result supports the hypothesis that, with an increase in temperature, there would be a significant increase in the number of lesions observed with radiographic detection.

Retention cysts are benign and self-limiting conditions, and are generally detected incidentally in asymptomatic patients (1,7,10). These cysts usually rupture and clear up spontaneously (1, 6, 10, 16). No need for treatment exists unless they are associated with symptoms or considerable radiographic expansion (8). In the presence of symptoms, management of retention cysts is surgical. Puncture and aspiration through the inferior meatus or natural ostium, or removal by the Caldwell-Luc approach, are the common procedures for treatment of this condition (5, 6, 10).

Conclusion

In this study the occurrence of RCs were found significantly high in the region with high temperature/low altitude when compared with the region that have low temperature/high altitude. Therefore, we think that RCs were more prevalent in the geographical regions that have high temperature. These marked increases in the prevalence of RCs reinforce the importance of the climate on the occurrence of these pathologies. Therefore, the results of this study indicate that, in a population of patients who were living in the regions that have high temperature, the presence of RCs in maxillary sinus strongly associated with the air conditions.

References

1. MacDonald A, Newton CW. Pseudocyst of the maxillary sinus. *J Endod* 1993;19(12):618-21.
2. Bell GW, Joshi BB, Macleod RI. Maxillary sinus disease: diagnosis and treatment. *Br Dent J* 2011;210(3):113-8.
3. Moon IJ, Kim ST, Han DH, Rhee CS, Lee CH, Min YG. Characteristics and risk factors of mucosal cysts in the paranasal sinuses. *Rhinology* 2011;49:309-14.
4. Harar RP, Chadha NK, Rogers G. Are maxillary mucosal cysts a manifestation of inflammatory sinus disease? *J Laryngol Otol* 2007;121(8):751-4.

5. Albu S. Symptomatic maxillary sinus retention cysts: should they be removed? *Laryngoscope* 2010;120(9):1904-9.
6. Hadar T, Shvero J, Nageris BI, Yaniv E. Mucus retention cyst of the maxillary sinus: the endoscopic approach. *Br J Oral Maxillofac Surg* 2000;38(3):227-9.
7. Allard RH, van der Kwast WA, van der Waal I. Mucosal antral cysts. Review of the literature and report of a radiographic survey. *Oral Surg Oral Med Oral Pathol* 1981;51(1):2-9.
8. MacDonald-Jankowski DS. Mucosal antral cysts observed within a London inner-city population. *Clin Radiol* 1994;49(3):195-8.
9. Chan HL, Wang HL. Sinus pathology and anatomy in relation to complications in lateral window sinus augmentation. *Implant Dent* 2011;20(6):406-12.
10. Wang JH, Jang YJ, Lee BJ. Natural course of retention cysts of the maxillary sinus: long-term follow-up results. *Laryngoscope* 2007;117(2):341-4.
11. Rodrigues CD, Freire GF, Silva LB, Fonseca da Silveira MM, Estrela C. Prevalence and risk factors of mucous retention cysts in a Brazilian population. *Dentomaxillofac Radiol* 2009;38(7):480-3.
12. Paparella MM. Mucosal cyst of the maxillary sinus: diagnosis and management. *Arch Otolaryngol* 1963;77:650-70.
13. Ruprecht A, Batniji S, el-Neweih E. Mucous retention cyst of the maxillary sinus. *Oral Surg Oral Med Oral Pathol* 1986;62(6):728-31.
14. Rege IC, Sousa TO, Leles CR, Mendonca EF. Occurrence of maxillary sinus abnormalities detected by cone beam CT in asymptomatic patients. *BMC Oral Health* 2012;12:30.
15. Gardner DG. Pseudocysts and retention cysts of the maxillary sinus. *Oral Surg Oral Med Oral Pathol* 1984;58(5):561-7.
16. Casamassimo PS, Lilly GE. Mucosal cysts of the maxillary sinus: a clinical and radiographic study. *Oral Surg Oral Med Oral Pathol* 1980;50(3):282-6.
17. Vallo J, Suominen-Taipale L, Huuonen S, Soikkonen K, Norblad A. Prevalence of mucosal abnormalities of the maxillary sinus and their relationship to dental disease in panoramic radiography: results from the Health 2000 Health Examination Survey. *Oral Surg Oral Med Oral Pathol Oral Radiol Endod* 2010;109(3):e80-7.
18. Mardinger O, Manor I, Mijiritsky E, Hirshberg A. Maxillary sinus augmentation in the presence of antral pseudocyst: a clinical approach. *Oral Surg Oral Med Oral Pathol Oral Radiol Endod* 2007;103(2):180-4.
19. Ahmad M, JJ, Downie M. Application of cone beam computed tomography in oral and maxillofacial surgery. *Aust Dent J*. 2012;57(1):82-94.
20. Donizeth-Rodrigues C, Fonseca-Da Silveira M, Goncalves-De Alencar AH, Garcia-Santos-Silva MA, Francisco-De-Mendonca E, Estrela C. Three-dimensional images contribute to the diagnosis of mucous retention cyst in maxillary sinus. *Med Oral Patol Oral Cir Bucal* 2013;18(1):e151-7.
21. Eence BK PD. Mucous retention cyst causing pain of the infraorbital nerve. *Otolaryngol Head Neck Surg* 1990;103(1031-4).
22. Kieff DA BN. Negative predictive value of normal nasal endoscopy for sinus disease as a cause of isolated facial pain. *J Laryngol Otol* 2011;125(10):1038-41.
23. DS M-J. Mucosal antral cysts in a Chinese population. *Dentomaxillofac Radiol* 1993;22(4):208-10.
24. Carter LC, Calamel A, Haller A, Aguirre A. Seasonal variation in maxillary antral pseudocysts in a general clinic population. *Dentomaxillofac Radiol* 1998;27(1):22-4.

Table 1. Descriptive statistics and the result of Student *t*-test for the regions

| Region | N | Mean | SD* | P-values for Shapiro-Wilk** | <i>t</i> -value | P-values |
|---------|-----|------|------|-----------------------------|-----------------|----------|
| Ordu | 158 | 3,64 | 1,64 | 0.073 | -6.274 | <0.001 |
| Erzurum | 36 | 5,94 | 3,06 | 0.126 | | |

*:Standard Deviation; **:Test of Normality

Table 2. Distribution of RCs regarding demographical and radiographical data

| Age Groups (Year) | Black Sea Region | | | | | | | | | | Eastern Anatolian Region | | | | | | | | | |
|-------------------|------------------|----|------------|-----------|------|----|-----------------------------|---------------|-----|-------------------|--------------------------|-----|------------|-----------|------|-----|-----------------------------|---------------|-----|-------------------|
| | Gender | | Unilateral | Bilateral | Side | | Mean Size(cm ²) | Dental Status | | Dental Pathology* | Gender | | Unilateral | Bilateral | Side | | Mean Size(cm ²) | Dental Status | | Dental Pathology* |
| | M | F | | | R | L | | E | D | | M | F | | | R | L | | E | D | |
| 10-19 | 22 | 11 | 32 | 1 | 15 | 17 | 3,52±1,56 | --- | 33 | 11 | 3 | 4 | 7 | --- | 4 | 3 | 6,04±2,95 | --- | 7 | 3 |
| 20-29 | 16 | 17 | 30 | 3 | 18 | 12 | 3,61±1,39 | --- | 33 | 9 | 8 | 4 | 12 | --- | 5 | 7 | 5,9±2,59 | --- | 12 | 3 |
| 30-39 | 18 | 17 | 32 | 3 | 20 | 13 | 3,62±1,57 | --- | 35 | 22 | 10 | 1 | 10 | 1 | 5 | 5 | 6,61±4,03 | 1 | 10 | 6 |
| 40-49 | 18 | 7 | 23 | 2 | 16 | 8 | 3,65±1,76 | 1 | 24 | 13 | 1 | --- | 1 | --- | 1 | --- | 1,71±--- | 1 | --- | 13 |
| 50-59 | 10 | 6 | 14 | 2 | 6 | 8 | 3,79±1,33 | 3 | 13 | 3 | --- | 2 | 2 | --- | --- | 2 | 6,60±0,85 | 1 | 1 | --- |
| ≥60 | 10 | 6 | 16 | --- | 5 | 9 | 4,11±2,57 | 7 | 9 | 5 | 1 | 2 | 3 | --- | 2 | 1 | 4,20±1,97 | 2 | 1 | 1 |
| Total | 94 | 64 | 147 | 11 | 80 | 67 | 3,64±1,64 | 11 | 147 | 63 | 23 | 13 | 35 | 1 | 17 | 18 | 5,94±3,07 | 5 | 31 | 26 |

M=Male; F=Female; R=Right; L=Left; E=Edentulous; D=Dentate; *Caries, Restorations, Root-canal filling