




TJVR 2021; 5 (1): 25-33

Turkish Journal of Veterinary Research

<http://www.dergipark.gov.tr/tjvr>

e-ISSN: 2602-3695

**Effects on the wound healing process using ozonated oils (*Sesame*, *Nigella sativa*, *Hypericum perforatum*) in rats**Ibrahim Canpolat¹ Yesari Eroksuz² Tamara Rızaoğlu¹ ¹ Department of Surgery, Faculty of Veterinary Medicine, University of Firat, Turkey² Department of Histopathology, Faculty of Veterinary Medicine, University of Firat, Turkey

Correspondence: Ibrahim Canpolat (icanpolat@firat.edu.tr)

Received: 15.01.2021

Accepted: 22.02.2021

ABSTRACT

Objective: In this study, the effects of three different ozonated oils (*Sesame*, *Nigella sativa* and *Hypericum perforatum*) on wound closure rate, healing process and possible complications were examined macroscopically and microscopically.

Materials and Methods: Twenty-one adult Wistar albino female rats were used in the study. Subjects were divided into three groups, early wound healing, (7 days), medium wound healing, (14 days) and late wound healing (21 days). Four full-thickness skin wounds of equal size (10 mm in diameter) were formed on the back regions of all rats. This region was chosen for preventing self-inflicted injuries and reducing external irritation. The wound was left open during the healing process. While the first wound (control) received no treatment in the second wound, ozonated *Sesame* oil, in the third wound ozonated *Nigella sativa* oil and in the fourth wound ozonated *Hypericum perforatum* oil were used. No group obtained parenteral drug administration. First, second and third main groups were euthanized on days 7, 14 and 21, respectively. The wound healing was assessed macroscopically daily. Wound sizes of individual rats were measured with a caliper and digitally photographed every day from the day of injury. After euthanasia, all wound sites of the subjects were evaluated histopathologically.

Results: There were no significant differences in wound healing between treatments in the first day 7. On they 14, it was found that the healing was better in the group applied *Nigella sativa* and *Sesame* oils ($p \leq 0.05$). On day 21 wound healing was completed in all subjects with a resultant of better outcome in *Nigella sativa* oil treatment compared with others ($p \leq 0.01$).

Conclusion: In this study the best wound healing outcome was achieved with *Nigella sativa* oil and *Sesame* oil where three different minced oils were used.

Keywords: Wound healing, Ozonated oil, *Sesame*, *Nigella sativa*, *Hypericum perforatum*

INTRODUCTION

The definition of a wound is interruption of ordinary congruity of structures typically limited to those caused by physical means and cause damage and injury (Lazarus et al., 1994). It is wound types that are performed in a manner compatible with anatomical and functional repair within normal healing period. Under appropriate conditions,

healing occurs within 20 to 30 days. These types of injuries are usually short-lived tissue injuries that are not very invasive surgical procedures, and healing is short-term and occurs in four distinct stages (Strodtbeck, 2001; Li et al., 2007). Wound healing is one of the most complex biological events after birth. It is a complex process of the replacement of dead tissue by a vital tissue. The

response of the body to local injury begins during in the process of inflammation, and results in repair and regeneration. Wound healing consists of four distinct phases, namely hemostasis phase, inflammatory phase, proliferative phase and maturational or remodeling phase, intermingled with each other. These phases can not be completed within the time of the failure should occur, or may occur in any one phase may result in the delay or closure of the wound healing (Cotran et al., 1999). Strong antibacterial, antiviral and antifungal effect, immunomodulatory effect, due to its positive effect on the transport and release of oxygen in the tissues, as well as its quick and efficient healing properties, medical ozone can be used in a wide range of indications (Viebahn-Haensher, 2002). The few studies on the therapeutic effects of ozonated oils on acute skin scarring in animal models does not analyze the dose / behavior response, expressed as the amount of peroxide present in the ozonated derivative used (Bocci, 2007). Recently, a quantitative evaluation of the therapeutic effect of locally applied ozonized sesame oil on acute skin scarring in mice as an animal model has been developed (Kim et al., 2009). The results indicate that low (<1000) and high (>3000) doses, expressed in terms of peroxide value (see the corresponding section in this article), delay skin healing. Such evidence is reinforced by a number of results between groups where the "average" concentration (about 1500) has the most beneficial effect in accelerating the rate of wound closure (Bocci, 2007). *Nigella sativa* has been found that broad spectrum medicines applied to diseases seen in animals affect people who consume them by accumulating in the animals' structures. This effect has been shown to impair people's immune system. It has antihistaminic, anti-inflammatory, anti-infective properties and has bronchodilator and vasodilator characteristics (Burits and Bucor, 2000; Ali and Blunden, 2003). The healing effect of the wounds of *H. perforatum* is well known. Human health and well characterized from the wound in Anatolia are used in many more people because of the positive effect. *H. perforatum* wound-healing effect, as well as sedative, antiseptic, antioxidant, anti-depression, spasm, antiviral and antimicrobial, hepatoprotective, diuretic effect and is referred to by the presence of antibiotic (Greenson et al., 2001; Hunt et al., 2001; Öztürk et al., 2007).

H. perforatum L. oily preparations, topical minor burns, wounds, skin infections and are used for various pains. Plant preparations are used in

anxiety and depressive problems (Di Carlo et al., 2001). Wound-healing effect of *H. perforatum* prepared from St. John's Wort oil has been known for a long time. This drug leads to photosensitization when used extensively and exposed to sunlight, inflammation and dermatitis occur in the mucosa and skin (Cingi, 1991; Çirak, 2006). The most important characteristic of sesame oil is resistance to oxidative degradation. Sesame oil high stability; in the composition of sesamol, sesaminol located just tocopherols from compounds acting on other edible oil from the oil-specific and potent antioxidant than these, hydrocarbons and some is due to the antioxidant effect of certain sterol (Anonymous 1). Sesame oil has many physiological functions such as lowering estrogenic activity, blood lipids and arachidonic acid level. The key step in determining the color, composition and quality of sesame oil is roasting. Antioxidant factors that provide stability are affected by roasting parameters (Agosa, 2011). Considering these advantages of ozonated oils, in this study, it was aimed at investigating which of the following results would be better using *Nigella sativa*, *Sesame* seeds and *Hypericum perforatum* in treatment of an experimental wound induced in rats.

MATERIALS and METHODS

Twenty-one 2-month-old female Wistar albino rats weighing 220-250 g were used and the study was conducted in the Firat University Experimental Research Center. Animals were maintained and fed under standard conditions; they were left free in the cages. This study approved by Local Ethics Experimental Animal Committee of Firat University, Turkey (19.12.2016-219). General anesthesia of rats was performed i.m. injection of 10 mg/kg Xylazine HCl (Rompun, Bayer®) and 80 mg/kg Ketamine Hydrochloride (Ketalar, Parke-Davis®). Following adequate anesthesia depth, i.e. loss of the pedal and eyelid reflex, the rats were placed on the operation table in the abdominal position and their back regions were shaved, scrubbed and painted using povidone iodine, covered with sterile surgical drapes and prepared for aseptic surgery. All operation procedures were performed following strict aseptic and atraumatic surgical guidelines. In the back region of the rats four full-thickness skin wounds of 1 cm in diameter were created with biopsy punch (Figure 1) on the back of each rat. The wound sites were divided into four groups according to agents used. While the

right cranial wound site was served as a control group, the left cranial which marked with "S" was allocated to group OS (ozonated sesame oil), right caudal marked with "Kt" (Control Group) to group ON and left caudal marked with "Ç" to group OH (ozonated *Hypericum perforatum* oil) (Figure 2). While control group wound site received no agent throughout the study, group OS, ON (ozonated *Nigella sativa* oil) and OH wound sites were applied ozonated sesame oil, ozonated *Hypericum perforatum* oil and ozonated *Nigella sativa* oil twice a day (morning and evening), respectively. All wounds were left uncovered throughout the study. The status of wound healing was evaluated macroscopically, the size of individual wounds in each rat were measured by a caliper (Figure 3) and photographed every day, beginning on the day of wounding. The rats were also divided randomly into three groups, days 7 (group 1), 14 (group 2) and 21 (group 3) of animals with equal number (no: 7) according to the day of euthanasia in order to evaluate the early, middle and late findings of wound healing. Group 1 (early wound healing) subjects were euthanized on postop day 7, group 2 subjects (middle-term wound healing) on post-op day 14, group 3 subjects (late wound healing) on postop day 21 by carbon dioxide inhalation. The wound sites were harvested with a scalpel and placed into %10 formalin liquid and presented to pathology department for histopathological evaluation. Histopathological evaluation was performed according to the wound healing assessment criteria shown in Table 1. Inflammation, ulceration and vascular proliferation was scored non (-), mild (+), moderate (++) and severe (+++). Closure of the wound surface, epithelization and fibroblast activity increase were graded as present (+) or absent (-). The mean scores of the histopathological findings were calculated scoring system, i.e. non (-), mild (+), moderate (++) and severe (+++) with 1, 2, 3 and 4 points, respectively.

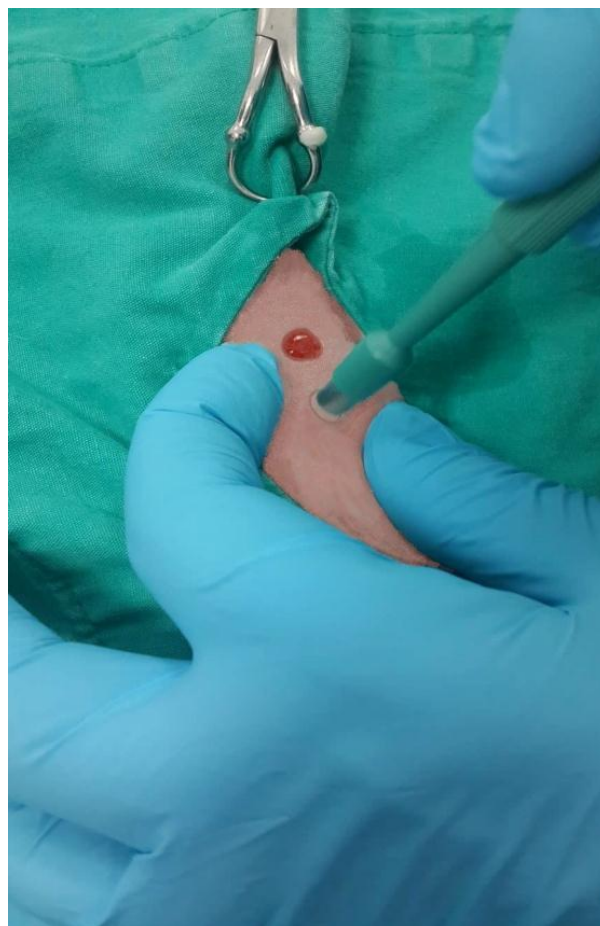


Figure 1. Creation of full-thickness skin wound with biopsy punch.

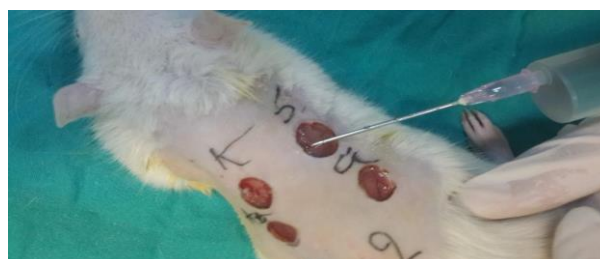

Figure 2. Each letter depicts which treatment had been applied for each wound. Ozonated sesame oil administration to the wound site "S".

Table 1. Evaluation criteria for the variables used in wound healing score.

Inflammation	Ulceration	Vascular Proliferation	Surface Closure	Epithelisation	Increased Fibroblast Activity
No	No	No	No	No	No
Mild	Mild	Mild (less than 5 vessels)	Yes/Have	Yes/Have	Yes/Have
Moderate	Moderate	Moderate (6-10 vessels)	-	-	-
Severe	Severe	Severe (More than 10 vessels)	-	-	-



Figure 3. Measurement wound size with vernier caliper.

Statistical analysis

All data was presented as mean \pm SD. Statistical analysis was performed with one-way analysis of variance (ANOVA) followed by Dunnet's post hoc test where multiple comparisons were made (SPSS22.0, USA). Differences set to $p < 0.01$ and $p < 0.05$ were considered statistically significant.

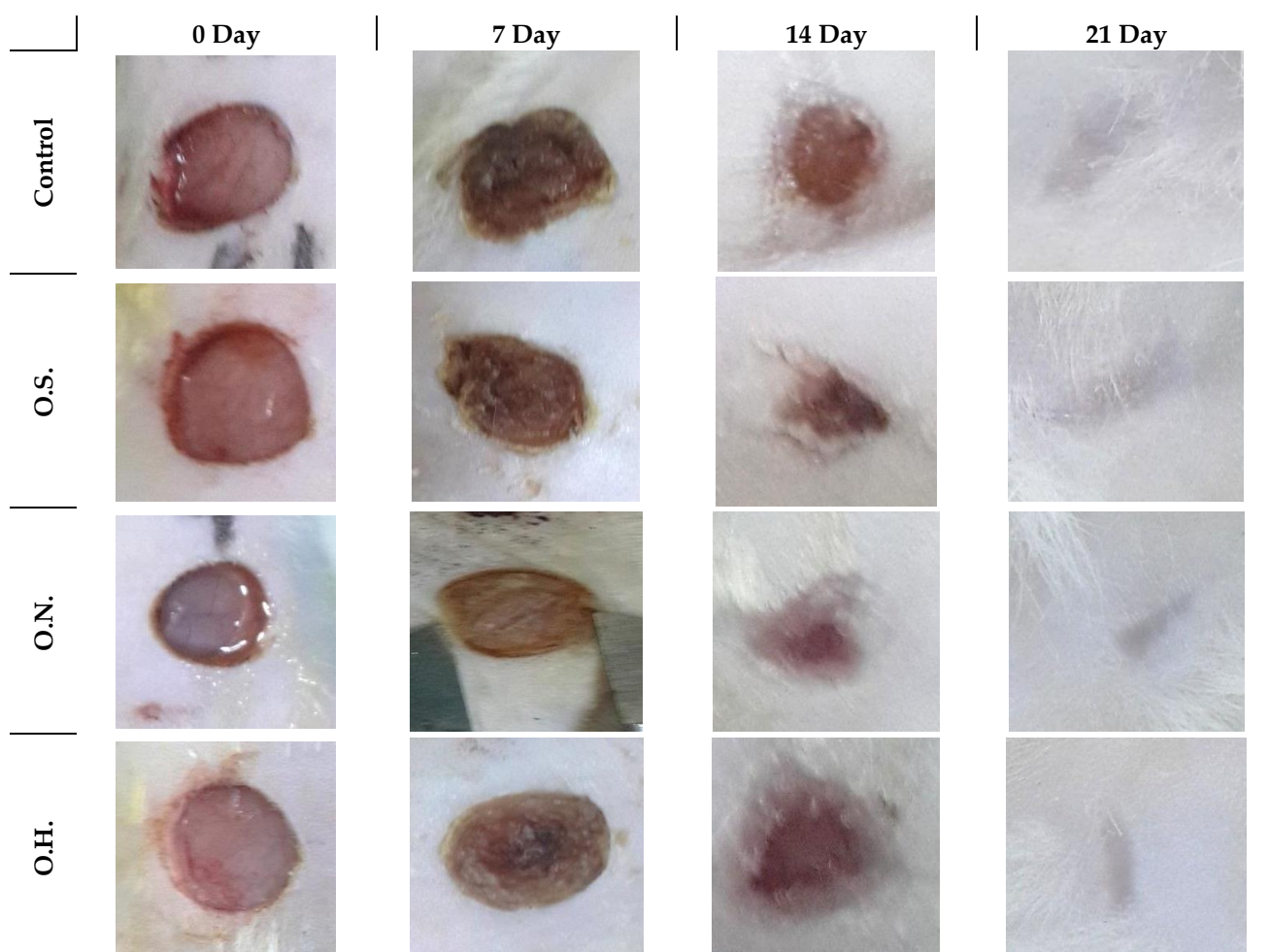


Figure 4. Wound healing processes throughout the study in four groups (control, groups OS, ON, OH) based on wound sites.

RESULTS

During the experimental study, no postoperative complications including wound infection and abnormal health status were recorded. Based on the statistical results, no significant difference was found between control as well as groups OS, ON and OH in post-op day 7 (group 1). However, when the data of group 2 (post-op 14) were statistically

evaluated the healing rate of wound sites treated with ozonated *Nigella sativa* oil (group ON) was significantly higher ($p < 0.01$), which is followed successively by the ozonated sesame oil (group OS, $p < 0.01$) and ozonated *Hypericum perforatum* oil (group OH, $p < 0.05$) compared to the control group. On post-op day 18, while all wound sites treated with ozonated oils (groups OS, ON, OH) reached

full recovery, healing in control wound site were still continuing, which were also observed to reach fully recovered on post-op day 19. As a result,

healing processes in all wound sites (control, group OS, ON, and OH) of all subjects completed before post-op day 21 (Figure 4).

Table 2. Distribution of the variables according to histopathological evaluation in rats euthanized on day 7 (group 1).

Variables/Groups	Control	Sesame oil	<i>Nigella sativa</i> oil	<i>Hypericum perforatum</i> oil
Inflammation	3	2	1	2
Ulceration	2	1	1	1
Vessel Proliferation	3	2	1	1
Surface Closure	–	–	–	–
Epithelisation (p≤0.01)	–	–	+	–
Fibroblast Activity (p≤0.01)	–	+	+	+

Table 3. Distribution of data according to histopathological evaluation in rats euthanized on day 14 (group 2).

Variables/Groups	Control	Sesame oil	<i>Nigella sativa</i> oil	<i>Hypericum perforatum</i> oil
Inflammation	2	0	0	1
Ulceration	1	0	0	0
Vessel Proliferation	2	1	0	1
Surface Closure (p≤0.01)	-	+	+	+
Epithelization (p≤0.01)	-	+	+	+
Fibroblast Activity Increase (p≤0.01)	+	+	+	+

Histological Results

Histopathological findings in group I (Day 7):

According to the histopathological scoring data, in control group wound sites contained a quite high inflammation and vascular permeability rates, newly formed fibroblast proliferation but no epithelization development. In group ON, there was a relatively less distinctive inflammation but high vascular permeability and high fibroblast proliferation compared to control group. In this group unlike control group epithelization process started. In group OS and OH moderate inflammation, increased vascular permeability and the edema formation were present. In both groups fibroblast proliferation also indicated (Figure 5) (Table 2).

On the seventh day, in all the groups, the lesions were characterized by skin ulcer including inflammatory infiltration, complete epithelial loss and dermatitis. Inflammatory reaction consisted of the neutrophils, macrophages and lymphocytes. There was no difference between the control and experimental groups in terms of inflammatory response, epithelization and connective tissue formation in all groups.

Histopathological Findings in Group 2 (Day 14):

According to the histopathological scoring data, control and OH groups showed moderate levels of inflammation and increased vascular permeability with newly formed fibroblast proliferation. In these groups' epithelization appeared to occur in most parts of the wound area. Unlike the control, in groups OS and ON, no inflammation was observed. In the control group it was determined that there was little edema compared to groups OS and ON. There was less increased vascular permeability in group ON than in group OS (Table 3).

In all groups of rats examined on day 14 of the study, fibrous connective tissue regeneration with no sebaceous and sweat glands was evident. Control group wound sites contained no epithelial regeneration but include irregularly laid down fibrous ligament. In the experimental groups, i.e. groups OS, OH and ON, had well developed epithelial regeneration. In the experimental groups, epithelization rate can be ordered from the most down to the lowest as group ON, OH and OS (Figure 6).

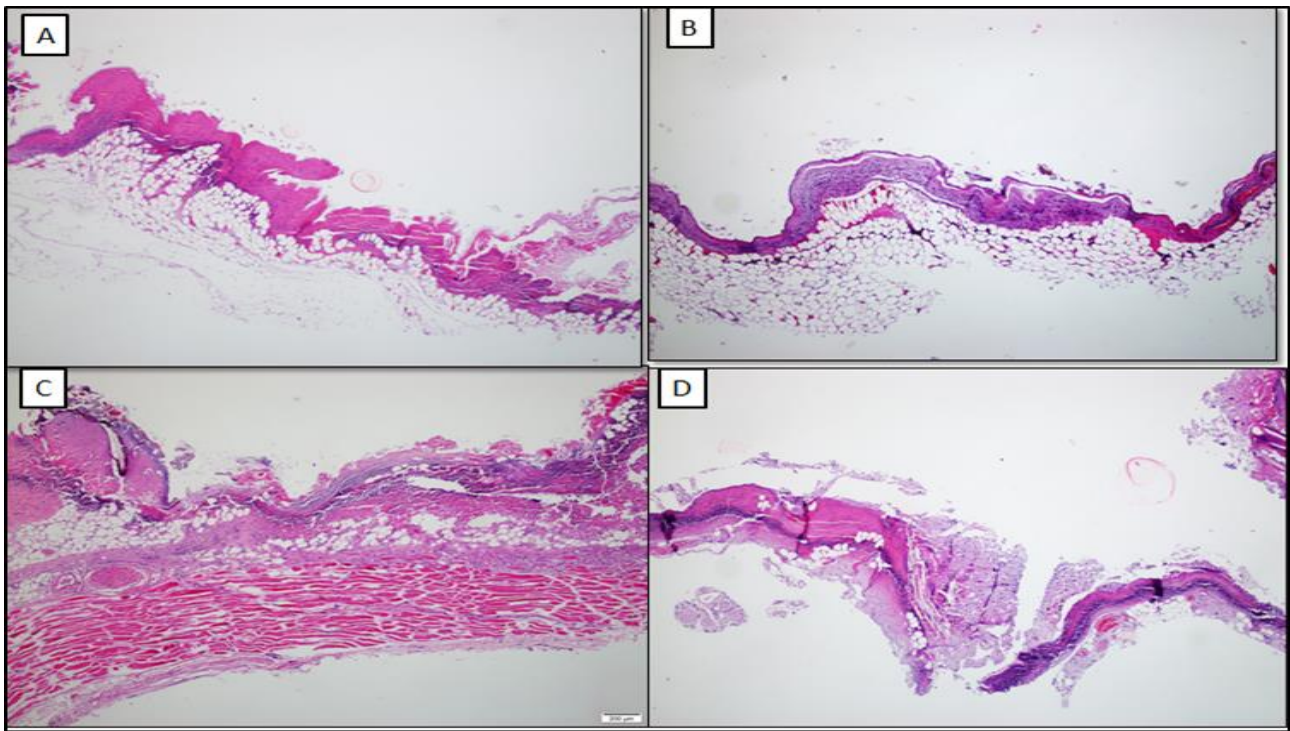


Figure 5. Skin ulcers characterized by necrotic debris and inflammatory infiltration with total absence of epidermis in all groups, including the control group, i.e. **A:** Control group, **B:** ON group, **C:** OH group, **D:** OS group, H-E, x4.

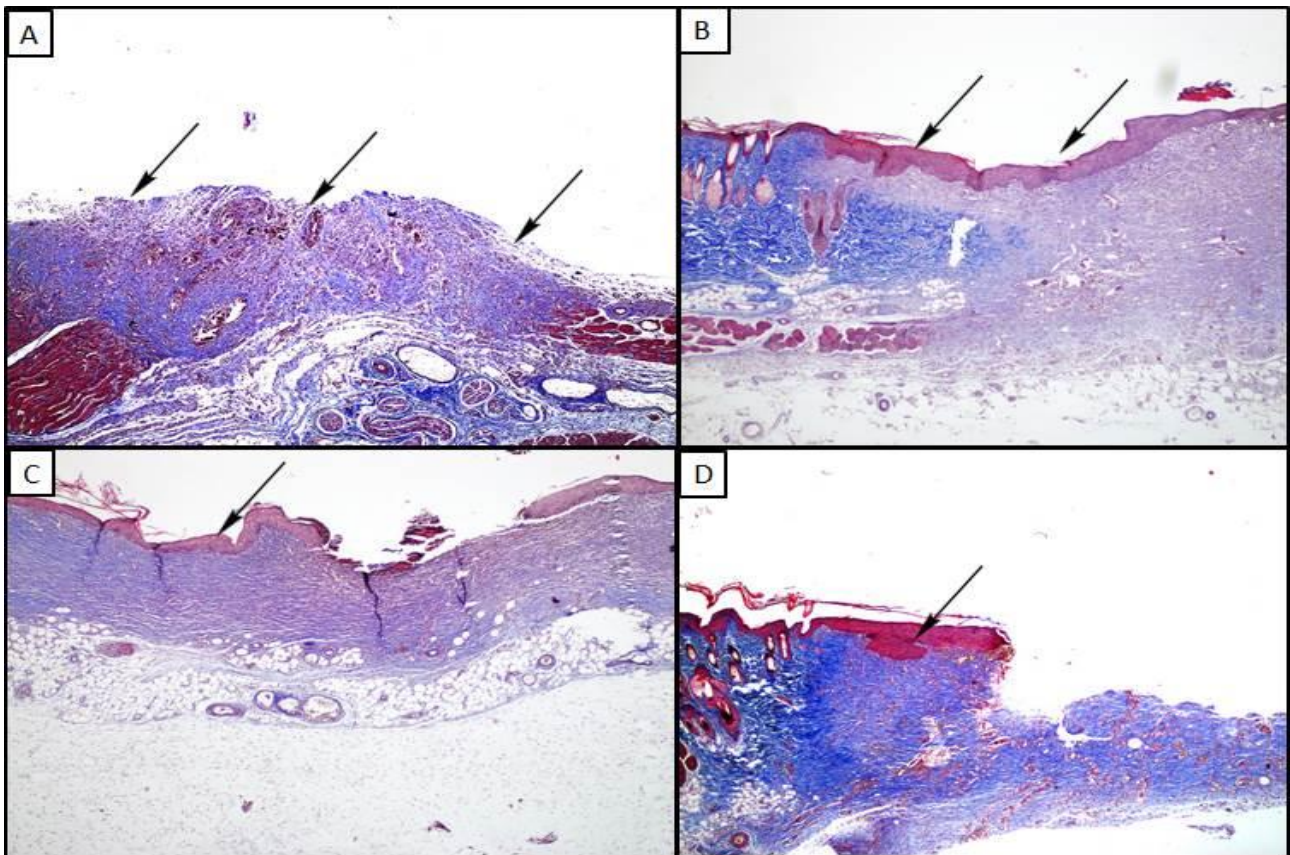


Figure 6. A: Complete removal of epidermis and irregular granulation tissue (arrows) in control group, MT, x10. **B:** Complete recovery of epidermis and development of granulation tissue (arrows), MT, x10. **C:** Partially epidermal (arrow) and dermal regeneration, (arrows) MT, x10. **D:** Partial epidermal (arrow) and dermal regeneration (arrows), MT, x10 in group OS.

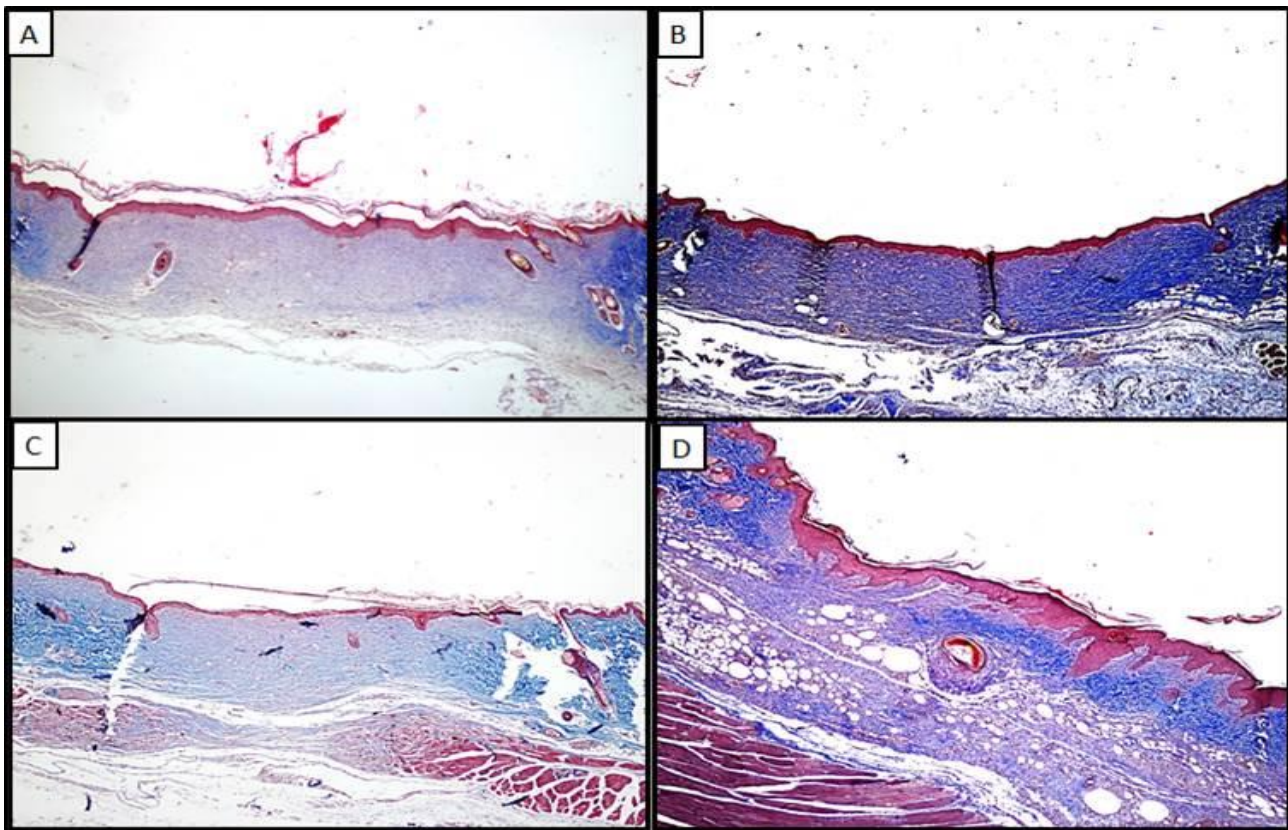


Figure 7. A: Epidermal regeneration and granulation tissue formation in the control group, MT, x10, B: Full recovery of the epidermis and granulation tissue development, MT, x10. C: Partial epidermal and dermal regeneration, MT, x10. D: Partial epidermal (arrow) and dermis regeneration, MT, x10 in group OS.

Histopathological Findings in Group 3 (Day 21):

In the third group, lesions in all experimental and epidermal regeneration and granulation tissue formation in the control group (Figure 7).

DISCUSSION

Wound healing in a defect tissue consists of a number of repair and reorganization processes, during which coagulation systems become active, acute and chronic inflammatory responses arise, new vascular events occur through angiogenesis and vasculogenesis, cells become proliferative, divide, apoptotic, extracellular matrix accumulates (Witte, 1997).

There are many products used under the name of dressing materials for therapeutic purposes in wound healing. Many herbal and fat-containing products have antioxidant activity and these products have been tested for topical wound healing promotion. Recently, *H. perforatum*, known as kantaron oil, has come to the agenda as a topical treatment agent especially in burns wound care (Blumenthal, 1998). Hammer et al. (2007) in their study reported that considering its antimicrobial, antioxidant, anti-inflammatory and

immunomodulatory effects its anti-inflammatory activities kantaron oil can be uses as active ingredient to induce wound healing. Dunic (2009) showed that kantaron oil contains high amounts of quercetin and biapigenin (129 $\mu\text{g} / \text{ml}$ and 52 $\mu\text{g} / \text{ml}$, respectively). Lavagne and Secci (2001) showed that topical use of *H. perforatum* containing oils has positive effects on epithelial regeneration of surgical wounds.

Sesame oil has recently begun to be used in wound healing (Valacchi et al., 2011). Suja (1998) reported that antioxidant property of sesame oil is due to ingredients such as sesamin, sesamol and sesamol present in its content. Sesame oil also contains 55% lipid and 20% protein. Kang (2000) revealed in vivo and in vitro studies that the sesamol is the most important free radical scavenger agent. In the same studies, these agents, i.e. sesamin, sesamol and sesamol, were shown to have inhibitory effects in membrane lipid peroxidation.

In a study conducted by Valacchi et al. (2011), was investigated the topical effects of ozonated sesame oil on wound healing, where it revealed that ozonated sesame oil interacts with polyunsaturated fatty acids and therefore has antioxidant effect. This

product promotes angiogenesis in wound healing and increases vascular endothelial growth factor as well as cyclin D1 expression.

Studies on the antimicrobial properties of *Nigella sativa* are available in the literature (Islam et al., 1989; Burits and Bucor, 2000; Arici et al., 2005). A study (Arici et al., 2005) determined that antimicrobial properties of *Nigella sativa* have a potential to accelerate wound healing. In a study by Arici et al. (2005), the antibacterial activity of *Nigella sativa* oil was investigated in vitro and a total of 24 antibacterial effects, which were mediated by the combination of thymoquinone, p-cymene and carvacrol components, were observed. Islam et al. (1989) tested the antifungal activity of *Nigella sativa* oil against 24 fungal organism of pathogenic and industrial strains and at the end of the study, they found that *Nigella sativa* oil had significant activity and stronger and wider range of actions against fungi. Bruits and Bucor (2000) found that *Nigella sativa* oil had especially antioxidants and free radical sweeping features but not pro-oxidant.

Flavonoids and triterpenoids are well-known to enhance wound healing. Because flavonoids and triterpenes are also components of *Nigella sativa* we hypothesized that the wound healing in this group would take place in a shorter period. Ozone, a powerful oxidant, is known as one of the strongest disinfectants because of this property. It is also used in the treatment of certain disorders such as dermatitis, alone or in combination with other agents, e.g. ozonated oil. Ozone gas reacts with oil via carbon-carbon double bonds (oleic acid, linoleic, linolenic acid, etc.) found in unsaturated fatty acids of vegetable oils (Suja, 1998). As a result of this reaction different products such as hydrogen peroxide, hydroxyhydroperoxide, aldehyde and ozonit are released (Lazarus et al., 1994). In the light of all these studies, we planned a study showing the effects of ozonated *H. perforatum* oil (St. John's Wort oil), sesame oil and *Nigella sativa* oil on topical wound healing. In this study, mean epithelialization days of *Nigella sativa*, sesame oil, *H. perforatum* oil and control (K) groups were measured as 5.08 ± 0.36 , 16.17 ± 0.46 , 16.83 ± 0.46 and 16.93 ± 0.46 , respectively. These data shows that *Nigella sativa* application has positive effects on wound epithelialization rate. Additionally, in our study, wound closure rates were assessed daily throughout the study and it was found that this rate was significantly higher ($p < 0.001$) in the treatment groups compared to the control groups. After 7th day and 14th day in wound treatment,

macroscopical findings demonstrated that the granulation tissue was smoother and more alive and histological parameters showed that wound healing developed healthier and vascularization reduced more markedly in experimental groups compared to control.

The wound area is the most obvious symptom of wound healing and can be evaluated measured with the closure rate of the wound surface. Contraction, known as the centripetal motion of the wound edges, which speeds up the closing process of open wounds, is governed by the myofibroblast and the extracellular matrix around it. Wound contraction is 80% effective in closing open wounds in where with loose skin texture (Robbins, 1992; Gençcelep et al., 2001; Engin, 2009). In our study, it was observed that contraction rate was significantly higher in *H. perforatum* group which were proceeded by *Nigella sativa* and sesame oil groups compared to control.

CONCLUSION

We investigated the effects of sesame oil, *Nigella sativa* oil and *H. perforatum* oil on wound healing considering their antiseptic and antibacterial properties. The wound healing rates were statistically more significant in the experimental groups than in the control groups except the 7th day. Macroscopic evaluation showed that recovery rate was faster in *Nigella sativa* oil and sesame oil group however when the experimental groups (sesame oil, *H. perforatum* oil) were compared with respect to histopathologic result no difference between experimental groups in terms of regeneration formation was found. The quantitative data of this study showed that ozonated *Nigella sativa* oil promoted wound healing significantly ($p < 0.001$) as compared to other groups. These results demonstrate that ozonated oils, especially the ozonated *Nigella sativa* oil may improve acute cutaneous wound repair, mainly via shortening the duration of epitalization. Topical application of specific ozonated oil may be considered as an alternative therapeutic modality to enhance cutaneous wound healing. Therefore, we believe that *Nigella sativa* oil can be used as an adjunct or an alternative agent to existing treatments in the future wound healing due to its antimicrobial, antioxidant, anti-inflammatory and immunomodulatory.

ACKNOWLEDGMENTS

This article was summarized from master thesis of third author.

Conflict of Interests: The authors declared that there is no conflict of interests.

Financial Disclosure: This study was supported by Research Fund of Firat University with the project number VF 17.03.

Author's Contributions: Creating an experimental 1 cm wound on rats and applying ozonated oils on them until the wound healed were performed by İC and TR. Histopathological examinations were performed by YE. Collecting, evaluating and writing the experimental data was done by İC and TR.

REFERENCES

- Agosa ET. Physical and Physiological Characteristics' of Seed of Agosa ET. Physical and Physiological Characteristics' of Seed of Sesame (*Sesamum indicum L.*) Varieties Grown in Nigeria [Master Thesis]. Abeokuta: University of Agriculture; 2011.
- Ali BH, Blunden G. Pharmacological and toxicological properties of *Nigella sativa*. *Phytother Res.* 2003; 17:299-306.
- Anonymous 1. Seed. Available at: <https://www.fairdinkumseeds.com/products-page/brassica-lettuce-and-asian-greens/sesame-indicum-white-sesame-seeds/>. Accessed May 20, 2017.
- Arici M, Sagdic O, Gecgel U. Antibacterial effect of Turkish black cumin (*Nigella sativa L.*) oils. *Grasas Y Aceites.* 2005; 56:259-262.
- Blumenthal M. St John's Wort. American Botanical Council. 1998; 11:470-485.
- Bocci V. The case for oxygen-ozonotherapy. *Br J Biomed Sci.* 2007; 64:44-49.
- Burits M, Bucar F. Antioxidant activity of *Nigella sativa* essential oil. *Phytother Res.* 2000; 14:323-328.
- Cingi Mİ. Sarı kantaron yağının yara iyileştirmesindeki yeri. *Anadolu Tıp Derg.* 1991; 13:35-39.
- Çırak C. Farklı Doku Kültürü Uygulamalarının İki Kantaron Türünde (*Hypericum perforatum* ve *H. bupleuroides*) Mikroçoğaltım Yeteneği Ve Hiperisin İle Toplam Fenolik Birikimi Üzerine Etkileri [Doktora Tezi]. Samsun: Ondokuz Mayıs Üniversitesi; 2006.
- Cotran RS, Kumar V, Collins T. Robbins Pathologic Basis of Disease. 2nd ed. Philadelphia: WB Saunders; 1999. p.107-109.
- Di Carlo G, Borrelli F, Ernst E, Izzo AA. St John's wort: Prozac from the plant Kingdom. *Trends Pharmacol Sci.* 2001; 22(6):292-297.
- Dunic GZ. Evaluation of *Hypericum perforatum* oil extracts for an antiinflammatory and gastroprotective activity in rats. *Phytother Res.* 2009; 23(11):1559-1564.
- Engin A. Yara iyileşmesi. In: Sayek İ, ed. Temel Cerrahi El Kitabı. Ankara: Güneş Tıp Kitapevleri; 2009. p.135-140.
- Gençelep M, Aslan L, Yüksel H, Karasu A, Bakır B. Otolog fibrin yapıştırıcının açık yara tedavisinde iyileşme üzerine etkisi: deneysel çalışma. *YYÜ Vet Fak Derg.* 2001; 12(1-2):101-104.
- Greeson JM, Sanford B, Monti DA. St. John's wort (*Hypericum perforatum*): a review of the current pharmacological, toxicological, and clinical literature. *Psychopharmacology.* 2001; 153:402-414.
- Hammer KDP, Hilwing ML, Solco AKS. Inhibition of prostoglandin E2 production by antiinflamatuvar *Hypericum perforatum* extracts and constituents in RAW264.7 mouse macrophage cells. *J Agric Food Chem.* 2007; 55:7323-7331.
- Hunt EJ, Lester CAE, Lester EA, Tackett RL. Effect of St. John's wort on free radikal production. *Life Sciences.* 2001; 69:181-190.
- Islam SK, Ahsan M, Hassan CM, Malek MA. Antifungal activities of the oils of *Nigella sativa* seeds. *Pak J Pharm Sci.* 1989; 2:25-28.
- Kang MH. Mode of action of sesame ligands in protecting low density lipoprotein against oxidative damage in vitro. *Life Sci.* 2000; 66:161-171.
- Kim HS, Noh SU, Han YW, Kim KM, et al. Therapeutic effects of topical application of ozone on acute cutaneous wound healing. *J Korean Med Sci.* 2009; 24(3):368-374.
- Lavagna SM, Secci D. Efficacy of Hypericum and Calendula oils in the epithelial reconstruction of surgical wounds in childbirth with caesarean section. *Farmaco.* 2001; 56:451-453.
- Lazarus GS, Cooper DM, Knighton DN, et al. Definitions and guidelines for assessment of wounds and evaluation of healing. *Arch Dermatol.* 1994; 130(4):489-493.
- Li J, Chen J, Kirsner R. Pathophysiology of acute wound healing. *Clin Dermatol.* 2007; 25:9-18.
- Öztürk N, Korkmaz S, Öztürk Y. Wound-healing activity of St. John's wort (*Hypericum perforatum L.*) on chicken embryonic fibroblasts. *J Ethnopharmacol.* 2007; 111(1):33-39.
- Robbins KC. Temel Patoloji (Basic Patology). 5th ed. İstanbul: Nobel Tıp Kitapevleri; 1992. p.47-60.
- Strodtbeck F. Physiology of wound healing. *New Inf Nurs Rev.* 2001; 1:43-52.
- Suja KP. Antioksidant efficacy of sesame cake extract in vegetable oil protection. *Food Chem.* 1998; 84:393-400.
- Valacchi G, Lim Y, Belmonte G, et al. Ozonated sesame oil enhances cutaneous wound healing in SKH1 mice. *Wound Repair Regen.* 2011; 19:107-115.
- Viebahn-Haensler R. The Use of Ozone in Medicine. Heidelberg: Karl F. Haug; 2002. p.83-84.
- Witte MB, Barbul A. General principles of wound healing. *Surg Clin of North Am.* 1997; 77(3):509-528.