

## A Rare Diagnosis of Syncope: Type 2 Brugada Syndrome

### Senkopta Nadir Tanı: Tip 2 Brugada Sendromu

Sertac GÜLER<sup>1\*</sup>, Dilber ÜÇÖZ KOCAŞABAN<sup>1</sup>

<sup>1</sup>Sağlık Bilimleri Üniversitesi, Ankara Eğitim ve Araştırma Hastanesi, Acil Tıp Kliniği, Ankara, Türkiye  
<sup>1</sup>Health Sciences University, Ankara Training and Research Hospital Department of Emergency Medicine

### ABSTRACT

Brugada syndrome (BS) is an autosomal-dominant inherited genetic disorder characterized by mutations in cardiac sodium-channel genes, characteristic changes in electrocardiography (ECG) and associated with increased risk of ventricular arrhythmia and sudden cardiac death. BS mostly affects Asian races and its prevalence varies in different societies. Although it is a rare disease, it should be considered in patients admitted to the emergency department (ED) with the complaint of syncope. In a study, it was revealed that the main complaint in 28% of patients with BS was syncope. Here, we present a 19-year-old male patient who admitted to ED with the complaint of syncope and was diagnosed with BS.

**Key Words:** Brugada Syndrome, Emergency Medicine, Sudden Cardiac Death, Syncope (MeSH Database).

### ÖZET

Brugada Sendromu (BS), kardiyak sodyum kanal genlerindeki mutasyonlar, elektrokardiyografide (EKG) tipik değişiklikler ile karakterize ve artmış ventriküler aritmi ve ani kardiyak ölüm riski ile ilişkili otozomal-dominant kalıtsal bir genetik hastalıktır. Brugada Sendromu çoğunlukla Asya ırklarını etkiler ve toplumdan topluma görülme sıklığı farklılıklar gösterir. Nadir bir hastalık olmasına rağmen acil servise (AS) senkop şikayeti ile başvuran hastalarda akılda tutulmalıdır. Yapılan bir çalışmada BS'li hastaların %28'inde ana şikayetin senkop olduğu ortaya konmuştur. Burada AS'ye senkop şikayeti ile başvuran ve BS tanısı konan 19 yaşındaki erkek hastayı sunuyoruz.

**Anahtar Sözcükler:** Brugada Sendromu, Acil Tıp, Ani Kardiyak Ölüm, Senkop (MeSH Veritabanı).

### INTRODUCTION

Brugada syndrome (BS) is an autosomal-dominant inherited genetic disorder characterized by mutations in cardiac sodium-channel genes, characteristic changes in electrocardiography (ECG) and associated with increased risk of ventricular arrhythmia and sudden cardiac death. As the classic ECG finding, a pseudo-right bundle branch block pattern and a permanent ST segment elevation are observed in leads V1-V3 (1, 2). In classical or type 1 BS, the high ST segment descends on the inverted T wave with an upward convexity ("coved-type"). In Type 2 BS, on the other hand, the ST segment has a "saddle type" wave configuration and shows a rise again towards the T wave as the higher ST segment descends. BS mostly affects Asian races and its prevalence varies in different societies (3). Its prevalence is 0.7-1.0 (4.5) in Japan and 0.012-0.4 (6) in America. Although it is a rare disease, it should be considered in patients admitted to the emergency department (ED) with the complaint of syncope. In a study, it was shown that the main complaint in 28% of patients with BS was syncope (7). Here, we present a 19-year-old male patient who presented to ED with the complaint of syncope and was diagnosed with BS.

### CASE PRESENTATION

A 19-year-old male patient was admitted to ED with complaint of syncope by his relatives. While sitting, the patient suddenly became unresponsive and, as the relatives said, this situation lasted for 2-3 minutes. The patient did not have any history of illness, substance or alcohol use. On physical examination, blood pressure was 130/70 mmHg, pulse of 83 beats/min, respiratory rate of 16/min, oxygen saturation 98% and body temperature was 36.8 °C. The patient looked a little tired and weak. His neurological examination was normal, his GCS score was 15. No pathology was found in other system examinations. Bedside fingerstick blood glucose was 105 mg/dL and his COHb level was 2.3. The type 2 BS pattern was observed on the ECG (Figure 1).

\*Sorumlu Yazar:Sertac GÜLER

<sup>1</sup>Sağlık Bilimleri Üniversitesi, Ankara Eğitim ve Araştırma Hastanesi, Acil Tıp Kliniği, Ankara, Türkiye

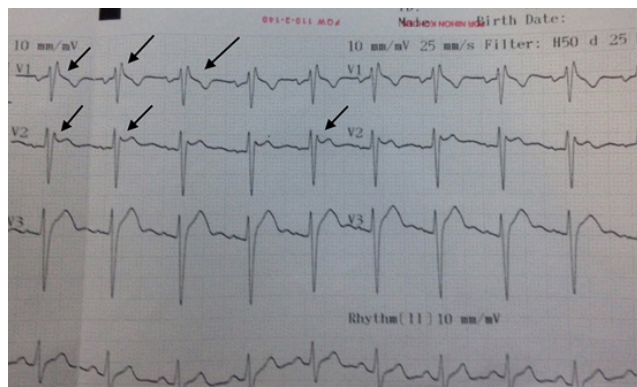
e-mail: drsertacguler@gmail.com

ORCID ID:// 0000-0002-6266-6145

Geliş tarihi: 16.01.2021

Kabul tarihi: 30.01.2021

**Figure 1.** ST segment elevation observed with rSR' pattern in leads of V1 and V2.



In rectal examination, there was no signs of gastrointestinal bleeding. The patients' hemoglobin levels, serum electrolytes and cardiac markers were within normal limits. The patient was monitored and consulted with Cardiology with the diagnosis of symptomatic type 2 BS. No pathology was found in the echocardiography performed by Cardiology. The patient was admitted to the Cardiology service for observation and evaluation of the need for an implantable cardioverter defibrillator (ICD).

## DISCUSSION

Brugada Syndrome is more common in men, and men more often present with syncope or sudden cardiac arrest (8). The average age of diagnosis of the patients is 41 (9). The presented patient is also a male patient and the age of diagnosis is quite early. Right ventricular abnormalities, cardiac sodium-channel gene mutations, fever and the use of cocaine or some psychotropic drugs may contribute to the emergence of clinical symptoms of BS. Our patient did not have a history of fever or use of any medication. BS is diagnosed by a combination of typical ECG findings and a presentation suggestive of ventricular arrhythmia. The most common clinical signs are associated with life-threatening ventricular arrhythmias. Approximately 1/3 of the patients of BS sudden cardiac arrest may be the first complaint. Again, some patients may be admitted to ED with syncope (10). The patient we present is a patient who was admitted with syncope and was diagnosed with BS. The most important prognostic factor in a patient diagnosed with BS is a history of ventricular tachyarrhythmia or syncope. Other less important prognostic factors are atrial fibrillation, male gender, and family history of sudden cardiac death. The patient we presented had no previous history of syncope and no family history of sudden cardiac arrest. In the management of BS, ICD implantation is among the treatment options to terminate a ventricular tachyarrhythmia, especially if associated with syncope, rather than antiarrhythmic drug therapy (11). This treatment is the safest, highly effective and mainstream treatment especially in the appropriate patient population decided by further tests. The presented patient may also be an ICD candidate and this was being prepared at the time of writing the report. In the management of Brugada Syndrome, it is necessary to make the decision of ICD implantation by evaluating the risk of ventricular tachyarrhythmia. The drug therapy recommended for patients who refuse ICD treatment or who are not eligible for this treatment for various reasons is quinidine or amiodarone. Since BS is an autosomal dominant disease, first-degree relatives of the patient should be offered

Cardiology outpatient control with 12-lead ECG. We also informed the relatives of the patient in this regard and directed them to the Cardiology outpatient clinic.

In conclusion, BS is a condition closely related to life-threatening ventricular arrhythmias. In almost 1/3 of the patients with BS, the first clinical symptom may be sudden cardiac arrest. In the lucky group remaining, the main complaint is syncope. ECG should be seen in patients who are admitted to ED with the complaint of syncope and this ECG should also be evaluated in terms of the characteristic features of BS.

## REFERENCES

1. Brugada P, Brugada J. Right bundle branch block, persistent ST segment elevation and sudden cardiac death: a distinct clinical and electrocardiographic syndrome. A multicenter report. *J Am Coll Cardiol* 1992;20:1391-6.
2. Brugada J, Brugada P. What to do in patients with no structural heart disease and sudden arrhythmic death? *Am J Cardiol* 1996;78:69-75.
3. Alings M, Wilde A. "Brugada" syndrome: clinical data and suggested pathophysiological mechanism. *Circulation* 1999;99:666-73.
4. Miyasaka Y, Tsuji H, Yamada K, Tokunaga S, Saito D, Imuro Y, et al. Prevalence and mortality of the Brugada-type electrocardiogram in one city in Japan. *J Am Coll Cardiol* 2001;38:771-4.
5. Matsuo K, Akahoshi M, Nakashima E, Seto S, Yano K. Clinical characteristics of subjects with the Brugada-type electrocardiogram. *J Cardiovasc Electrophysiol* 2004;15:653-7.
6. Patel SS, Anees S, Ferrick KJ. Prevalence of a Brugada pattern electrocardiogram in an urban population in the United States. *Pacing Clin Electrophysiol* 2009;32:704-8.
7. Sacher F, Arsac F, Wilton SB, Derval N, Denis A, de Guillebon M, et al. Syncope in Brugada syndrome patients: prevalence, characteristics, and outcome. *Heart Rhythm* 2012;9:1272-9.
8. Benito B, Sarkozy A, Mont L, Henkens S, Berruezo A, Tamborero D, et al. Gender differences in clinical manifestations of Brugada syndrome. *J Am Coll Cardiol* 2008;52:1567-73.
9. Brugada J, Brugada R, Brugada P. Determinants of sudden cardiac death in individuals with the electrocardiographic pattern of Brugada syndrome and no previous cardiac arrest. *Circulation* 2003;108:3092-6.
10. Rodríguez-Mañero M, Namdar M, Sarkozy A, Casado-Arroyo R, Ricciardi D, de Asmundis C, et al. Prevalence, clinical characteristics and management of atrial fibrillation in patients with Brugada syndrome. *Am J Cardiol* 2013;111:362-7.
11. Priori SG, Wilde AA, Horie M, Cho Y, Behr ER, Berul C, et al. HRS/EHRA/APHRS expert consensus statement on the diagnosis and management of patients with inherited primary arrhythmia syndromes: document endorsed by HRS, EHRA, and APHRS in May 2013 and by ACCF, AHA, PACES, and AEPC in June 2013. *Heart Rhythm* 2013;10:1932-63.