

## MENTAL NERVE INJURY CAUSED BY GUTTA-PERCHA OVEREXTENSION: A CASE REPORT GÜTAPERKA TAŞMASININ NEDEN OLDUĞU MENTAL SİNİR YARALANMASI: BİR OLGU SUNUMU

### ABSTRACT

Paresthesia can be seen due to inferior alveolar nerve damage. Rarely, this nerve injury can occur before, during or after endodontic treatment. Endodontics-related causes of paresthesia are periapical infections, local anesthesia, chemical and mechanical irritations that occurs during root canal irrigation, shaping and filling procedures. Endodontic-related paresthesia is mostly seen in lower molar teeth and surgical treatment approach is followed. This case report aimed to present diagnosis and non-surgical treatment of mental nerve paresthesia caused by gutta-percha overextension from the apex of right second premolar with the usage of cone-beam computed tomography (CBCT). Case: 40-year-old woman had pain and numbness in her right lower lip and chin which occurred two days later following endodontic therapy for her mandibular right second premolar. The gutta-percha was removed from the root canal in one piece and the patient's complaints were gone. One-year follow-up was uneventful. CBCT can be considered as an effective diagnostic tool when inferior alveolar nerve paraesthesia due to endodontic treatment complication is suspected. Non-surgical retreatment procedures could be beneficial in cases of paraesthesia caused by gutta-percha extrusion.

**Key Words:** Overextension, Mental Nerve Injury, Endodontics, Iatrogenic Injury, Case Report

### ÖZ

Inferior alveolar sinir hasarına bağlı olarak parestezi görülebilir. Nadiren, bu sinir hasarı endodontik tedavi öncesinde, sırasında veya sonrasında ortaya çıkabilir. Endodonti kaynaklı parestezi nedenleri; periapikal enfeksiyonlar, lokal anestezi, kök kanal yıkama, şekillendirme ve dolgu işlemleri sırasında ortaya çıkan kimyasal ve mekanik iritasyonlardır. Endodonti kaynaklı parestezi en çok alt molar dişlerde görülür ve cerrahi tedavi yaklaşımı izlenir. Bu olgu sunumunda, sağ ikinci premolar apeksinden güta-perka ekstrüzyonuna bağlı gelişen mental sinir parestезisinin konik ışınli bilgisayarlı tomografi (CBCT) ile tanı ve cerrahi dışı tedavisinin sunulması amaçlanmıştır. 40 yaşındaki kadının sağ alt dudağında ve çenesinde mandibular sağ ikinci küçük azının endodontik tedavisinden iki gün sonra ağrı ve uyuşma meydana gelmiştir. Güta-perka tek parça halinde kök kanalından çıkarılmış ve hastanın şikayetleri ortadan kalkmıştır. Bir yıllık takipte hastanın şikayeti bulunmamaktadır. CBCT, endodontik tedavi komplikasyonuna bağlı inferior alveolar sinir parestезisinden şüphelenildiğinde etkili bir tanı aracı olarak düşünülebilir. Güta-perka ekstrüzyonunun neden olduğu parestezi vakalarında cerrahi olmayan retreatment prosedürleri faydalı olabilir.

**Anahtar Kelimeler:** Taşkınpreperasyon, Mental Sinir Hasarı, Endodonti, İatrojenik Yaralanma, Olgu Sunumu

Gözde Akbal DİNÇER<sup>1</sup>

ORCID: 0000-0001-5188-334X

Deniz ERDOĞAN<sup>2</sup>

ORCID: 0000-0001-2345-6789

Ali TÜRKYILMAZ<sup>2</sup>

ORCID: 0000-0003-0641-0062

Ali ERDEMİR<sup>2</sup>

ORCID: 0000-0003-1140-3887

1 Okan University, Faculty of Dentistry, Department of Endodontics, Istanbul, Turkey

2 Kirikkale University, Faculty of Dentistry, Department of Endodontics, Kirikkale, Turkey



Geliş tarihi / Received: 20.01.2021

Kabul tarihi / Accepted: 16.04.2021

DOI: xx.xxxxx/jids.2019.xxx

**İletişim Adresi/Corresponding Adress:**

Gozde Akbal Dincer

Okan University, Faculty of Dentistry, Department of Endodontics, Istanbul, Turkey,

E-posta/e-mail: gozdeakbal1@gmail.com

## INTRODUCTION

The fundamental principles of root canal treatment are eradication of infected tissues and bacteria, sufficient root canal preparation and filling. In principle, the filling material should be kept within the boundary of root canal without extending to periapical tissues or other adjacent structures. Although periradicular tissues generally well tolerate minor extrusion of endodontic filling materials, materials beyond the apical foramen may cause clinical manifestations (1).

Neuronal injury may cause paresthesia in oral cavity. Paresthesia is described as a burning or prickling sensation, pain, feeling warm or cold (2). There are a number of systemic and local factors that may lead to orofacial paresthesia (3). Multiple sclerosis, sarcoidosis and metastasis are examples of systemic factors, while traumatic injuries, impacted teeth, implantology, orthognathic surgery, and endodontic treatment are local factors (4). Endodontics-related causes of paresthesia are; periapical infections, local anesthesia, chemical and mechanical irritations that occurs during root canal irrigation, shaping and filling procedures (4).

Endodontics-related paresthesia affects inferior alveolar nerve (IAN) and the mental nerve (MN) mostly (5). IAN is one of the numerous divisions of trigeminal nerve's mandibular branch. MN, a branch of the IAN, exit from the mandible through the mental foramen and maintains sensation to the anterior aspects of the chin and lower lip, besides the buccal gingivae of the mandibular anterior and premolar teeth (6). Paresthesia cases associated with the lower second molars have been reported mostly, however cases related to the premolars and the first molars have also been declared (7).

This case report aimed to present diagnosis and non-surgical treatment of mental nerve paresthesia caused by gutta-percha overextension from the apex of right second premolar with the usage of cone-beam computed tomography (CBCT).

## CASE REPORT

A 40-year-old woman was applied to department of endodontics regarding pain and numbness in her right lower lip and chin which occurred two days later following endodontic therapy for her mandibular right second premolar. In medical and familial stories, association with this condition could not be detected. In extraoral and intraoral examination, there was no symptom other than paresthesia, pain and excessive sensitivity to percussion in mandibular right second

premolar. When periapical film of the previous root canal treatment was examined, it was seen that gutta-percha was at the radiological apex (Figure 1)

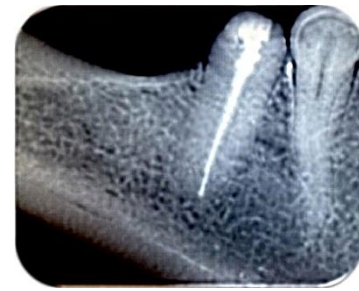


Figure 1: Periapical image

However symptoms, the history of prior root canal treatment and intimate relationship of apex with the mandibular canal have brought to mind the inadvertent extrusion of gutta-percha to the mandibular canal. Due to the severity of patient's complaints and two-dimensional periapical film was not adequate to display the essential information, CBCT was taken as an alternative radiographic examination revealed that radiopaque root canal filling material in the periapical area of the mandibular right second premolar was extended from the apex (Figure 2 and 3).

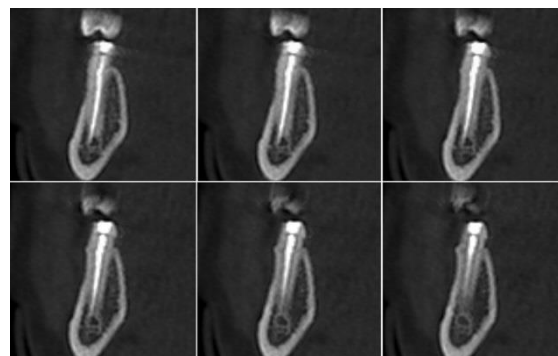


Figure 2: Coronal section

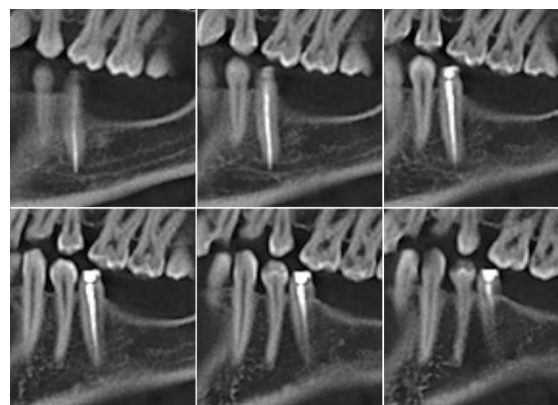


Figure 3: Sagittal section

After negotiating treatment options with the patient, it was decided to do retreatment to remove the gutta-percha from the root canal before surgical methods.

## DISCUSSION

reported in the literature. Endodontics-related nerve damage accounts for 10% of total nerve injuries (8).

In a published article, it was determined that periapical lesion, radicular cyst, overinstrumentation, paste and gutta percha overfill, root canal irrigant and sealer extrusion were the causes of endodontics-related paresthesia (9). Although paresthesia cases resulting from endodontic treatment of lower molars have been more common (10-15), cases of paresthesia related to lower premolar teeth have been published less frequently (9,16,17). In a retrospective study which cases of paresthesia related to treatment of mandibular premolars were examined, it was stated that the percentage was 0.96% (8/832) (7). In this case report, as a result of gutta-percha which was overextended from the right second premolar's apex, paraesthesia occurred in the patient.

In a study investigating the development and symptoms of nerve injuries after endodontic treatment, while 53.6% of patients reported immediate post-treatment symptoms, in 36.2% of patients there was a 24–48 h asymptomatic period (18). The patient in this case reported the symptoms started as soon as the effect of anesthesia had passed after endodontic treatment, as reported by most patients in the study.

Conventional imaging techniques may not aid to make certain diagnosis of extrusion into the nerve by demonstrating the communication of the filling material with the alveolar nerves. The most important reason for this is that these techniques present a three-dimensional object in two dimensions (19). As a result, the required information cannot be obtained in some cases, for example in challenging situations where the relationship between the mandibular nerves and the end point of filling material is desired to be learned. In similar cases CBCT was found to provide superior diagnostic accuracy (19). In this case report as periapical film was not adequate to display essential information, CBCT was taken.

In the treatment of endodontics-related paresthesia cases has not a single protocol. Neurotoxicity of chemical materials and compression caused by the extruded material are responsible for the nerve injury (17). In both cases the cause must be eliminated. If the overextended material is a substance that cannot be removed orthogradically from the canal, such as canal paste and sealer, a surgical approach is required (17). In this case, since the gutta-percha is a solid substance, it was attempted to be removed with more conservative method in one piece through the canal.

In the researches, it was already determined that the

Mandibular anesthesia was performed before the procedure, since the tooth was sensitive to percussion. After isolation was achieved with rubber-dam, the restorative material was removed and endodontic access cavity was prepared. To prevent the extended gutta-percha to move further apically, gaps were formed circumferentially between the gutta-percha and the root canal wall with #20 K-files. H files were used in the gaps for removing the gutta-percha. Following removal of the master gutta-percha, retreatment procedures were performed using Protaper Universal retreatment instruments (D1, D2, D3) (Dentsply Maillefer, Ballaigues, Switzerland). The working length was determined by CBCT measurements, confirmed by apex locator (Root ZX mini, J Morita Corp, Tokyo, Japan) and periapical radiographs. To create an apical stop, canal preparation was performed to F5 Protaper Universal file (Dentsply Maillefer, Ballaigues, Switzerland). After gentle irrigation with 2.5% NaOCl and 17% EDTA, the canal was dried with paper points and dressed with calcium hydroxide (Metapaste; Meta Biomed, Chungbuk, South Korea). The access cavity was closed with a sterile cotton pellet and temporary filling material.

Two weeks later, at the second appointment, the patient stated that there was no numbness three days later after the first visit and the tooth was asymptomatic. No sensitivity to percussion was detected in the tooth. In this way, temporary filling material was removed, root canal was irrigated with 17% EDTA to remove calcium hydroxide. After gentle irrigation with 2.5% NaOCl and 17% EDTA, the root canal was dried with paper points and the tooth was filled with cold lateral condensation technique using tapered gutta-percha (Dentsply Maillefer, Ballaigues, Switzerland) and sealer (2Seal VDW, München, Germany). Access cavity was restored with light-cured composite resin (GC Gradia Direct, Tokyo, Japan) (Figure 4). Six months and one year follow-ups were uneventful.

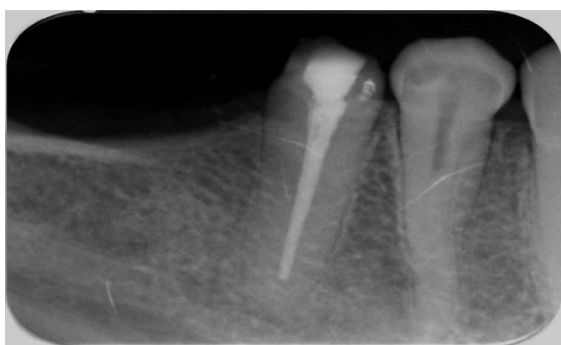

Figure 4: Periapical image

Cases of endodontics-related paresthesia have been

symptoms were eliminated by removing the overextended filling material (20). However, as the time from the incident to the treatment increases, the possibility of healing decreases as the injury to the nerve also increases mechanically and chemically (21). In this case treatment was performed early and the patient's symptoms disappeared completely.

## CONCLUSION

CBCT can be contemplated as an influential radiographic diagnostic tool when suspected of inferior alveolar nerve or mental foramen paraesthesia due to endodontic treatment complication. It seems logical that if the cause of injury is nerve compression then removing the cause as early as possible could be beneficial. This may be achieved by cautious retreatment procedures; if failed, surgery could be only solution.

## KEY FINDINGS

- CBCT can be contemplated as an influential radiographic diagnostic tool when suspected of inferior alveolar nerve paraesthesia due to endodontic treatment complication.
- The cause of injury is nerve compression, cautious retreatment procedures could be beneficial

## ACKNOWLEDGEMENT

N/A

## DISCLOSURE

Financial grants and funding were nil. No interest to disclose. This article does not contain any studies with human or animal subjects performed by any of the authors.

## REFERENCES

1. Gambarini G, Plotino G, Grande NM, *et al.* Differential diagnosis of endodontic-related inferior alveolar nerve paraesthesia with cone beam computed tomography: a case report. *Int Endod J* 2011;44:176-81.
2. Kruse A, Hellmich N, Zhou H, *et al.* Neurological deficit of the facial nerve after root canal treatment. *Oral Surg Oral Med Oral Pathol Oral Radiol Endod.* 2009; 108: 46–8.
3. Morse DR. Endodontic-related inferior alveolar nerve and mental foramen paraesthesia. *Compend Contin Educ Dent.* 1997; 18: 963–68.

4. Mohammadi Z. Endodontics-Related Paresthesia of the Mental and Inferior Alveolar Nerves: An Updated Review. *J Can Dent Assoc.* 2010; 76: 117.
5. Cohenca N, Rotstein I. Mental nerve paraesthesia associated with a non-vital tooth. *Endod Dent Traumatol.* 1996; 12: 298-300.
6. Chong BS, Gohil K *et al.* Anatomical relationship between mental foramen, mandibular teeth and risk of nerve injury with endodontic treatment. *Clin Oral Invest.* 2017; 21: 381-87.
7. Knowles KI, Jergenson MA, Howard JH. Paresthesia associated with endodontic treatment of mandibular premolars. *J Endod.* 2003; 29: 768–70.
8. Renton T, Yilmaz Z. Profiling of patients presenting with post traumatic neuropathy of the trigeminal nerve. *J Orofac Pain.* 2011; 25: 333–44.
9. Ahonen M, Tjäderhane L. Endodontic-related paraesthesia: a case report and literature review. *J Endod.* 2011; 37: 1460-464.
10. Andrabi, Syed Mukhtar-Un-Nisar, Alam S, Zia A, Khan MH, Kumar Ashok. Mental nerve paraesthesia secondary to initiation of endodontic therapy: a case report. *Restor Dent Endod.* 2014; 39: 215-19.
11. Biglioli F, Kutanovaite O, Autelitano L, *et al.* Surgical treatment of painful inferior alveolar nerve injuries following endodontic treatment: a consecutive case series of seven patients. *J Oral Maxillofac Surg.* 2017;21:461-66.
12. Blanas N, Kienle F, Sandor G. Inferior alveolar nerve injury caused by thermoplastic gutta-percha overextension. *J Can Dent Assoc.* 2004; 70: 384-87.
13. Escoda-Francoli J, Canalda-Sahli C, Soler A, Figueiredo R, Escoda CG. Inferior alveolar nerve damage because of overextended endodontic material: a problem of sealer cement biocompatibility? *J Endod.* 2007; 33: 1484-489.
14. González-Martín M, Torres-Lagares, Perez JLG, Egea JJ. Inferior alveolar nerve paraesthesia after overfilling of endodontic sealer into the mandibular canal. *J Endod.* 2010; 36: 1419-421.
15. López-López J, Estrugo-Devesa A, Salas EJ, Egea JJ. Inferior alveolar nerve injury resulting from overextension of an endodontic sealer: non-surgical management using the GABA analogue pregabalin. *Int Endod J.* 2012; 45: 98-104.

- 16.** PovedaR, Bagán JV et al. Mental nerve paresthesia associated with endodonticpaste within the mandibular canal: report of a case. *Oral Surg Oral Med Oral Pathol Oral Radiol Endod.* 2006; 102: 46-49.
- 17.** Scarano A, Di Carlo F et al. Injury of the inferior alveolar nerve after overfilling of the root canal with endodontic cement: a case report. *Oral Surg Oral Med Oral Pathol Oral Radiol Endod.* 2007; 104: 56-59.
- 18.** Devine M, Modgill O et al. Mandibular division trigeminal nerve injuries following primary endodontic treatment. A case series. *Aust Endod J.* 2017; 43: 56-65.
- 19.** Patel S, Dawood A et al. The detection and management of root resorption lesions using intraoral radiography and cone beam computed tomography – an in vivo investigation. *Int Endod J.* 2009; 42: 831–838.
- 20.** Alves FR, Coutinho MS et al. Endodontic-related facial paresthesia: systematic review. *J Can Dent Assoc.* 2014; 80: 13.
- 21.** Koseoglu BG, Tanrikulu S et al. Anesthesia following overfilling of a root canal sealer into the mandibular canal: a case report. *Oral Surg Oral Med Oral Pathol Oral Radiol Endod.* 2006; 101: 803-806.