

Early enteral nutrition with L-glutamine improves anastomotic healing in rats administered hyperthermic intraperitoneal chemotherapy with cisplatin and 5-FU

Hüseyin Alakuş¹, Mustafa Göksu², Sıraç Erten³

¹Department of Surgical Oncology, Adiyaman University Faculty of Medicine, Adiyaman, Turkey

²Department of General Surgery, Adiyaman University Faculty of Medicine, Adiyaman, Turkey

³Department of Pathology, Adiyaman University Training and Research Hospital, Adiyaman, Turkey

ORCID ID of the author(s)

HA: 0000-0003-2650-7208
MG: 0000-0002-1807-6957
SE: 0000-0002-6993-1378

Corresponding Author

Mustafa Göksu
Adiyaman University Training and Research Hospital, Department of General Surgery, Adiyaman, 02100 Turkey
E-mail: drmustafagoksu@gmail.com

Ethics Committee Approval

This study was conducted at Adiyaman University Experimental Animal Application and Research Center (Adiyaman, Turkey) after obtaining the approval of the Experimental Animals Local Ethics Committee of the university (Referance No: 2019/019).

All procedures in this study involving human participants were performed in accordance with the 1964 Helsinki Declaration and its later amendments.

Conflict of Interest

No conflict of interest was declared by the authors.

Financial Disclosure

The authors declared that this study has received no financial support.

Published

2021 September 18

Copyright © 2021 The Author(s)

Published by JOSAM

This is an open access article distributed under the terms of the Creative Commons Attribution-NonCommercial-NoDerivatives License 4.0 (CC BY-NC-ND 4.0) where it is permissible to download, share, remix, transform, and buildup the work provided it is properly cited. The work cannot be used commercially without permission from the journal.



Abstract

Background/Aim: One of the most significant aspects of intestinal surgery is anastomotic wound healing. After intestinal surgery, the most serious complication is gastrointestinal leakage, which is associated with a high rate of morbidity and mortality. The rate of morbidity and mortality can be reduced by increasing the mechanical resistance of the anastomosis. Glutamine improves impaired wound healing through effects on the healing process. This study investigated the effects of early enteral glutamine supplementation on colonic anastomosis healing in rats treated with hyperthermic intraperitoneal chemotherapy (HIPEC) with cisplatin and fluorouracil (5-FU).

Methods: Twenty-four rats were divided into three groups. Group 1 underwent colonic anastomosis and intraabdominal hyperthermic saline administration, Group 2 underwent colonic anastomosis and HIPEC, and Group 3 underwent colonic anastomosis and HIPEC and postoperative administration of glutamine solution via an orogastric tube for 7 days. On day 7, all rats were sacrificed and anastomotic bursting pressure (ABP) was evaluated. Tissue specimens were taken to examine tissue hydroxyproline levels and histopathological changes in the anastomotic line.

Results: The ABP was significantly greater in Group 2 than in Groups 1 and 3 ($P=0.001$ and $P=0.046$, respectively). The tissue hydroxyproline level was higher in Group 1 and Group 3 than in Group 2 ($P=0.001$ and $P=0.043$, respectively). The histopathological findings in Group 3 were better than those in Group 2. The histopathological findings were observed to improve in the early enteral nutrition with Glutamine group.

Conclusions: The findings of this study indicate that early enteral glutamine supplementation facilitates colonic anastomosis healing following HIPEC with cisplatin and 5-FU, by increasing the ABP and tissue concentrations of hydroxyproline and decreasing the inflammatory response.

Keywords: Glutamine, Colonic anastomosis, Bursting pressure, Wound Healing, Hyperthermic Intraperitoneal Chemotherapy

Introduction

Peritoneal carcinomatosis (PC) is a clinical condition caused by the dissemination of cancer cells originating from the peritoneal surface or often internal organs to the abdominal cavity and is associated with poor prognosis and reduced survival. The cancer spreads to the intestines, peritoneum, mesentery, and other visceral organs, leading to malnutrition, ileus and death [1, 2]. In selected patients with PC, the combination of cytoreductive surgery (CRS) with hyperthermic chemotherapy (HIPEC) administered to the peritoneal cavity is an effective approach for clinically managing this disease [3]. Gastrointestinal leakage occurs in approximately 5–34% of patients treated with CRS and HIPEC and is also a cause of severe morbidity and mortality [4-6]. Previous studies demonstrated the adverse effects of HIPEC treatment on anastomosis by impairing wound healing [7, 8].

Glutamine is the most abundant free amino acid in plasma and is stored mainly in the lungs and skeletal muscles [9]. Oral glutamine administration improves wound healing through its role in wound healing processes such as collagen synthesis, wound contraction, and epithelization, and increases the anastomotic bursting pressure (ABP) of colorectal anastomoses [10, 11].

To the best of our knowledge, no studies evaluated the effects of early enteral nutritional support with glutamine on anastomosis in HIPEC patients. Therefore, we investigated the effects of early enteral glutamine supplementation on colonic anastomosis recovery in rats treated with HIPEC with cisplatin combined with fluorouracil (5-FU).

Materials and methods

This study was conducted at Adiyaman University Experimental Animal Application and Research Center (Adiyaman, Turkey) after obtaining the approval of the Experimental Animals Local Ethics Committee of the university (Reference No: 2019/019). All animal experiments were performed according to the World Medical Association Code of Ethics (Helsinki Declaration). The study used Twenty-four Wistar-Albino rats weighing 360–401 g. The rats were kept in groups of eight in controllable, specifically designed cages with free access to food and water under appropriate temperature and light and dark conditions. None of the animals were administered antibiotics.

Study groups and procedure

For the number of laboratory animals to be used in the study, a power analysis was carried out using G * Power 3.1.94 package program. When the effect size used in the program and expressed by Cohen was 0.69, a total of 24 rats (8 in each group) were included in the study [12]. The statistical power of the test was set at 80% with a significance level of $P < 0.05$. The animals were divided into three groups, as follows: Group 1, control: Transection of the left colon followed by end-to-end anastomosis and hyperthermic administration (41°C) of saline. Group 2, cisplatin + 5-FU: Left colon transection followed by end-to-end anastomosis and hyperthermic administration of 2 mg/kg cisplatin and 5 mg/kg 5-FU for 45 min. Group 3, cisplatin + 5-FU and early enteral nutrition with glutamine: Left colon

transection followed by end-to-end anastomosis and hyperthermic administration of 2 mg/kg cisplatin and 5 mg/kg 5-FU for 45 min. Following surgery, 0.4 g/kg/day L-glutamine dissolved in 5 mL water was administered via an orogastric tube for 7 days. The rats were administered intramuscular anesthetic agents of 5 mg/kg Rompun (xylazine, Bayer, İstanbul, Turkey) and 50 mg/kg Ketalar (ketamine hydrochloride, Park Devis, İstanbul, Turkey). The abdominal surface of the rat was cleaned, and 10% povidone-iodine was used to ensure antisepsis of the surgical site. A 4 cm midline laparotomy incision was made. At ~3 cm above the peritoneal reflection, the left colon was defined and transected. Then, an end-to-end anastomosis was performed with eight sutures using 6-0 propylene (Prolene; Ethicon, NJ, USA) in a single-layer interrupted fashion. In Groups 2 and 3, HIPEC was implemented using an open method with 40 mL saline solution (5 mg/kg) heated to 41°C , and the abdomen was closed. The temperature of the solution was measured with a thermometer probe in the abdomen. When the intra-abdominal temperature fell below 40°C , the HIPEC fluid was aspirated and 41°C HIPEC solution was added again. An intermittent massage was conducted to distribute the chemotherapy agent. After 45 min, the abdomen was opened, and the washing solution was removed. Then the abdomen was sutured and closed. All operations were carried out using sterile surgical methods by the same surgeon. In Group 3, following surgery, 0.4 g/kg/day L-glutamine dissolved in 5 mL water was administered via an orogastric tube for 7 days. A combination of cisplatin and 5-FU as chemotherapeutic agents was used for the HIPEC procedure, as cisplatin exerts cytotoxic effects with increased temperature independently of the cell proliferation stage and 5-FU exerts its effect independently of the cell proliferation stage. Such a combination is frequently used in clinical practice. The rats were placed in their cages following surgery and subcutaneously administered 5 mL saline. All groups started feeding at the 6th postoperative hour. Groups 1 and 2 were fed standard food and water, while Group 3 was also fed glutamine daily via an orogastric tube for enteral nutrition.

ABP

All rats underwent a re-laparotomy on postoperative day 7. ABP was measured using a pressure transmitter (Transpac IV; Abbott Laboratories, Rockville, MD, USA) and a monitor (BM5; Bionet Patient Monitor, Seoul, Korea). A 2F feeding catheter was placed in the rectum. The colon was tied with 2-0 silk in a manner that included the catheter 3 cm below the anastomosis. The proximal section of the anastomosis was blocked using a clamp to establish a closed loop. Saline was delivered to the colon via the catheter inserted in the rectum at a rate of 2 mL/min using an infusion pump, and the pressure was monitored. The last measured value on the ABP monitor was registered as the ABP [13]. Upon the recording of ABP values, the colonic segment was resected and separated into two equal pieces: One was placed in a 10% formalin solution for histopathological analysis and the other was kept at -70°C for hydroxyproline (HYP) analysis. The rats were sacrificed by high doses of anesthetic drugs.

Histopathological analysis

The histopathological parameters of anastomotic healing were assessed using the Phillips scoring system [14]. The

colonic material that was placed in 10% formalin solution was embedded in paraffin after a 24-hour fixation. The paraffin-embedded tissues were stained with hematoxylin and eosin (H&E) and Masson's trichrome stain. The specimens were evaluated for fibroblasts, neovascularization, collagen, and inflammation, with each parameter rated on a scale from 0 to 3: 0: None; 1: Slight increase; 2: Moderate infiltration; and 3: Dense infiltration.

HYP determination

The levels of HYP were determined using the biotin double-antibody sandwich technology enzyme-linked immunosorbent assay (ELISA). From the 24 rat colonic tissue samples, 50 µg specimens were cut at equal weight and placed in phosphate-buffered saline (PBS, pH 7.4). The tissues in PBS were mixed manually for homogenization and centrifuged at 3000 rpm for 20 min. The supernatants were filtered and analyzed. The specimens and kits (Rat Hydroxyproline ELISA Kit, Rel Assay Diagnostic; MEGA TIP group, Gaziantep, Turkey) were stored outside until they reached room temperature. For each specimen to be studied, two wells were prepared (one for the standard and one as an empty well for the study). Chromogen solutions and stop solution were added to the empty wells, and 50 µL biotin antibody-integrated standard and 50 µL streptavidin horseradish peroxidase (HRP) were added to the standard wells. Then 40 µL sample was added to the sample wells, followed by the addition of 10 µL anti-HYP antibody and 50 µL streptavidin-HRP. Subsequently, the microplate was kept in an incubator (Nüve incubator; Nüve, Ankara, Turkey) at 37°C for 60 min. Then, 50 µL chromogen solution was added to each well. The plate was incubated in the dark for 15 min to allow color development followed by the addition of 50 µL stop solution. The plates were evaluated in an automated ELISA analyzer (Rel Reader, Rel Assay Diagnostic; MEGA TIP group) at a wavelength of 450 nm.

Statistical analysis

The statistical analyses were performed using the SPSS (version 25.0; SPSS, Chicago, IL, USA) software package. Statistical data were evaluated using average parameter values (ABP, tissue concentrations of HYP, and histopathological scores). Between-group variables were assessed with one-way analysis of variance (ANOVA) and X^2 , and between-group differences were analyzed using Tukey's honest significant test and Tamhane's post-hoc test. $P < 0.05$ was considered statistically significant.

Results

There were no mortalities throughout the study. No complications such as surgical site infection or wound dehiscence were observed.

ABP

The mean ABPs were 145.25 (25.18), 113.25 (8.12), and 133.00 (3.81) mmHg in Groups 1, 2 and 3, respectively. One-way ANOVA revealed statistical significance in the ABP values ($P=0.002$). The post-hoc analysis showed statistically significant differences in ABP between Group 1 and Group 2 ($P=0.001$), and between Group 2 and Group 3 ($P=0.046$). The difference between Group 1 and Group 3, was insignificant ($P=0.213$). These findings indicate that early enteral nutrition

with glutamine improved colonic anastomosis wound healing by improving ABP in the group undergoing HIPEC with cisplatin + 5-FU (Table 1).

Concentrations of HYP

Average concentrations of HYP in the intestinal wall were 247.10 (4.76), 237.15 (5.32), and 242.90 (2.78) µg/g in Groups 1, 2, and 3, respectively. One-way ANOVA revealed a significant difference in HYP tissue concentrations among the groups ($P=0.001$). Post-hoc analysis revealed a statistically significant difference in tissue concentrations of HYP between Groups 1 and 2 ($P=0.001$), and between Groups 2 and 3 ($P=0.043$). The difference between Group 1 and Group 3, in turn, was nonsignificant ($P=0.164$) (Table 1). These findings indicate that the HIPEC procedure is likely to repair reduced concentrations of HYP in the wound of colonic anastomosis by increasing tissue HYP concentrations through enteral nutrition with glutamine.

Table 1: Mean and standard deviation values for ABP and tissue HYP levels of groups

Groups	Group 1	Group 2	Group 3	P-value
Anastomotic Bursting Pressure (mmHg)	145.25(25.18)	113.25(8.12)	133.00(3.81)	0.002*
Tissue hydroxyproline (µg/g)	247.10(4.76)	237.15(5.32)	242.90(2.78)	0.001**

*The differences between Groups 1 and 2 and Groups 2 and 3 were significant ($P=0.001$ and $P=0.046$, respectively). The difference between Groups 1 and 3 was not significant ($P=0.273$). ** The differences between Groups 1 and 2 and Groups 2 and 3 were significant ($P=0.001$ and $P=0.043$, respectively). The difference between Groups 1 and 3 was not significant ($P=0.164$).

Histopathological findings

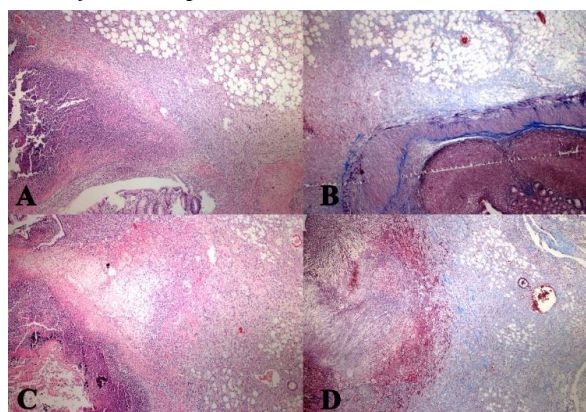
The histopathological results of the groups were defined according to the Phillips scale. One-way ANOVA indicated a significant difference in fibroblast and collagen values among the groups ($P=0.041$ and $P=0.017$, respectively) (Table 2). In terms of fibroblast values, post hoc analysis revealed a significant difference between Groups 1 and 2 ($P=0.032$). The collagen levels were significantly different between Groups 1 and 2, and between Groups 2 and 3 ($P=0.001$ and $P=0.043$, respectively). These findings suggest that enteral nutrition with glutamine had beneficial effects on colonic anastomosis recovery performed using HIPEC with cisplatin and 5-FU by increasing collagen levels (Figure 1).

Table 2: Histopathological findings of groups by Phillip's scale

Groups	Group 1	Group 2	Group 3	P-value
Fibroblast	2.75(0.46)	2.13(0.35)	2.50(0.53)	0.041*
Neovascularization	2.50(0.53)	2.13(0.35)	2.38(0.51)	0.296(NS)
Collagen	2.75(0.46)	1.75(0.46)	2.38(0.51)	0.017**
Inflammation	2.63(0.51)	2.13(0.35)	2.38(0.51)	0.128(NS)

* The difference between Groups 1 and 2 was significant ($P=0.032$). The difference between Groups 2 and 3 was significant ($P=0.250$). The difference between Groups 1 and 3 was not significant ($P=0.537$). ** The difference between Groups 1 and 2 was significant ($P=0.001$). The difference between Groups 2 and 3 was significant ($P=0.043$). The difference between Groups 1 and 3 was not significant ($P=0.286$).

Figure 1: Histopathologic appearance of the anastomotic line in the groups. A. H&E-stained anastomotic line of cisplatin+5-FU-delivered subject at 40x magnification, B. Masson's trichrome-stained anastomotic line of cisplatin+5-FU-delivered subject at 40x magnification, C. H&E-stained anastomotic line of cisplatin+5-FU-delivered and early enteral nutrition with glutamine-administered subject at 40x magnification, D. Masson's trichrome-stained anastomotic line of cisplatin+5-FU-delivered and early enteral nutrition with glutamine-administered subject at 40x magnification



Discussion

CRS is an aggressive local treatment carried out ahead of perioperative HIPEC [15]. Despite the increased survival in patients with PC, a prominent increase is seen in morbidity and mortality with mortality resulting mainly from sepsis and respiratory complications [16-18]. The most reported (5–34%) complications are intraabdominal sepsis, anastomotic leakage and intestinal fistulas, the latter of which is the most common and requires CRC and HIPEC treatment [18-21]. Intestinal fistulas occur as a result of anastomotic leakage or intestinal perforations. In a previous study examining complications of CRS and HIPEC, a fistula was identified in the anastomotic and suture lines in 17 of 203 patients [6]. Verwaal et al. observed intestinal fistulas and intraabdominal sepsis at a rate of 17.6% and 15.6%, respectively [18]. It is worth noting that more anastomoses are required following CRS and HIPEC compared to other gastrointestinal surgeries. Thus, to minimize postoperative fistula rates, some surgeons perform a diverting ostomy proximal to the colonic and rectal anastomoses [6]. After the treatment of patients is completed, another issue is ostomy closure. A previous study reported that 71% of colostomies could be closed, and a re-colostomy was performed in 14% of the closed colostomies due to emerging complications [16]. Makrin et al. investigated the effects of chemotherapy and hyperthermia on colorectal anastomosis, and found that the ABP fell in the hyperthermia groups compared to the control group on day 10 [22]. The authors observed that the ABP dropped the most in the cisplatin group. HIPEC had particularly adverse effects on colon ABP during the early postoperative period (up to day 10). The negative effects of HIPEC may cause anastomotic leakage and postoperative morbidity. Therefore, they suggest that avoiding unnecessary anastomosis is essential for patient and procedure selection. Pelz et al. demonstrated the detrimental effects of a chemotherapeutic (Mitomycin) on anastomotic healing [23]. In a study by Aarts et al., anastomosis of the ileum and colon was performed, followed by HIPEC with mitomycin C. The authors observed a decrease in wound strength of colonic anastomosis in the HIPEC group after cytoreduction [24].

Glutamine is the body's most available free amino acid and plays a critical role in nitrogen transport and acid-base equilibrium. Therefore, glutamine is one of the most studied nutrients and the starting point of metabolic support studies [25]. It is necessary for the rapid division of enterocytes, lymphocytes, and fibroblasts, and is also involved in antioxidant defense mechanisms by affecting glutathione synthesis [26]. Under physiological conditions, enough glutamine is produced to maintain the body's glutamine storage requirements (especially of the skeletal muscles) and to meet the demands of glutamine-consuming tissues [27]. In case of stress such as injury, sepsis and inflammation, glutamine consumption is increased in the gastrointestinal system, immunological cells, inflammatory tissue, and kidneys. Under severe stress, the intracellular and plasma glutamine levels decrease by 50% and 30%, respectively [9]. In this case, nitrogen balance and immunosuppression can be improved with glutamine supplementation [28]. Oral glutamine administration is reportedly effective in relieving oxidative stress and the proinflammatory responses induced by endotoxemia [29]. Goswami et al. [10] studied the impact of oral glutamine on

wound healing in rats and found that glutamine had a positive effect on wound healing by affecting various wound healing stages such as collagen synthesis, wound contraction, and epithelialization. Sapidis et al. [11] studied the preoperative administration of glutamine and symbiosis, which increased the mechanical strength of the anastomosis. Thus, they claimed that it decreases the rupture of anastomotic line and bacterial translocation. Da Costa et al. reported that perioperative orally glutamine supplementation increased both the mechanical strength of the anastomosis and the percentage of mature collagen in the anastomosis line on postoperative days 3 and 8 [30]. Gökpinar et al. [31] investigated the effects of early and late enteral nutrition with glutamine on anastomotic healing, and found that in the postoperative period, early administration of total enteral nutrition significantly increased anastomotic resistance and collagen synthesis. In this study, enteral nutrition with glutamine led to an improvement in ABP and tissue concentrations of HYP following HIPEC treatment with cisplatin and 5-FU. These findings are consistent with the previous publications in literature.

Earlier experimental studies used one chemotherapeutic agent (e.g., 5-FU, cisplatin, paclitaxel, mitomycin-c); however, two chemotherapeutic agents are currently included in the HIPEC regimen after CRS in clinical practice. These agents include drugs that exert increased effects with hyperthermia, independently of cell proliferation (e.g., cisplatin, mitomycin-c, doxorubicin); and those that are not associated with hyperthermia, independently of cell proliferation (e.g., 5-FU and paclitaxel). This the first study to investigate the effects of early enteral glutamine supplementation on colonic anastomotic healing in patients treated with HIPEC with cisplatin and 5-FU.

This study had some limitations. First, experiments were performed on laboratory animals, so future studies of a similar nature are needed prior to the study findings being included in clinical practice. Second, although this procedure is performed on a selected patient group with good performance in clinical practice, most patients are malnourished and the duration of surgery is long for cytoreduction, necessitating one or several anastomoses thereafter. The rats used in our study had no malnutrition or peritoneal disease. Third, colonic anastomosis was performed after transection without colonic resection. When assessing complications due to surgery, 30 postoperative days should be taken into account. We completed this study on day 7. Finally, in clinical practice, HIPEC treatment is combined with early postoperative intraperitoneal chemotherapy (EPIC), which generally begins on the first postoperative day and continues for 5 days. EPIC was not used in this study. We believe that such limitations should be taken into consideration in prospective experimental studies.

Conclusion

Enteral nutrition with glutamine after HIPEC positively affected anastomotic wound healing by increasing the number of fibroblasts, collagen deposits, tissue HYP levels in the anastomosis area, and the anastomosis's mechanical resistance. Thus, we believe that early enteral glutamine supplementation after HIPEC can reduce postoperative morbidity and mortality by preventing anastomotic leaks.

References

- Carmignani CP, Sugarbaker TA, Bromley CM, Sugarbaker PH. Intraperitoneal cancer dissemination: mechanisms of the patterns of spread. *Cancer Metastasis Rev.* 2003;22(4):465-72. doi: 10.1023/a:1023791229361. PubMed PMID: 12884919.
- Chua TC, Yan TD, Saxena A, Morris DL. Should the treatment of peritoneal carcinomatosis by cytoreductive surgery and hyperthermic intraperitoneal chemotherapy still be regarded as a highly morbid procedure?: a systematic review of morbidity and mortality. *Ann Surg.* 2009;249(6):900-7. doi: 10.1097/SLA.0b013e3181a45d86. PubMed PMID: 19474692.
- Sugarbaker PH, Jablonski KA. Prognostic features of 51 colorectal and 130 appendiceal cancer patients with peritoneal carcinomatosis treated by cytoreductive surgery and intraperitoneal chemotherapy. *Ann Surg.* 1995;221(2):124-32. doi: 10.1097/0000658-199502000-00002. PubMed PMID: 7857141; PubMed Central PMCID: PMCPCMC1234945.
- Elias D, Gilly F, Boutitie F, Quenet F, Bereder JM, Mansvelt B, et al. Peritoneal colorectal carcinomatosis treated with surgery and perioperative intraperitoneal chemotherapy: retrospective analysis of 523 patients from a multicentric French study. *J Clin Oncol.* 2010;28(1):63-8. doi: 10.1200/JCO.2009.23.9285. PubMed PMID: 19917863.
- Glehen O, Gilly FN, Boutitie F, Bereder JM, Quenet F, Sideris L, et al. Toward curative treatment of peritoneal carcinomatosis from nonovarian origin by cytoreductive surgery combined with perioperative intraperitoneal chemotherapy: a multi-institutional study of 1,290 patients. *Cancer.* 2010;116(24):5608-18. doi: 10.1002/cncr.25356. PubMed PMID: 20737573.
- Younan R, Kusamura S, Baratti D, Oliva GD, Costanzo P, Favaro M, et al. Bowel complications in 203 cases of peritoneal surface malignancies treated with peritonectomy and closed-technique intraperitoneal hyperthermic perfusion. *Ann Surg Oncol.* 2005;12(11):910-8. doi: 10.1245/ASO.2005.11.030. PubMed PMID: 16177862.
- Aghayeva A, Benlice C, Bilgin IA, Atukeren P, Dogusoy G, Demir F, et al. The effects of hyperthermic intraperitoneal chemoperfusion on colonic anastomosis: an experimental study in a rat model. *Tumori.* 2017;103(3):307-13. doi: 10.5301/tj.5000610. PubMed PMID: 28291907.
- Lopez-Lopez V, Lynn PB, Gil J, Garcia-Salom M, Gil E, Gonzalez A, et al. Effect of Paclitaxel-based Hyperthermic Intraperitoneal Chemotherapy (HIPEC) on colonic anastomosis in a rat model. *Clin Transl Oncol.* 2019;21(4):505-11. doi: 10.1007/s12094-018-1948-7. PubMed PMID: 30229392.
- Kovacevic Z, McGivan JD. Mitochondrial metabolism of glutamine and glutamate and its physiological significance. *Physiol Rev.* 1983;63(2):547-605. doi: 10.1152/physrev.1983.63.2.547. PubMed PMID: 6132422.
- Goswami S, Kandhare A, Zanwar AA, Hegde MV, Bodhankar SL, Shinde S, et al. Oral L-glutamine administration attenuated cutaneous wound healing in Wistar rats. *Int Wound J.* 2016;13(1):116-24. doi: 10.1111/iwj.12246. PubMed PMID: 24690128.
- Sapdis N, Tziouvaras C, Ioannidis O, Kalaitzidou I, Botsios D. The effect of glutamine and synbiotics on the healing of colonic anastomosis. *Rev Esp Enferm Dig.* 2014;106(4):255-62. PubMed PMID: 25075656.
- Cohen J. A power primer. *Psychol Bull.* 1992;112(1):155-9. doi: 10.1037//0033-2909.112.1.155. PubMed PMID: 19565683.
- Erdem E, Dinc S, Erdem D, Ustun H, Caydere M, Alagol H. Effects of intraperitoneal chemotherapy and GM-CSF on anastomotic healing: an experimental study in rats. *J Surg Res.* 2002;108(1):1-6. doi: 10.1006/jsre.2002.6425. PubMed PMID: 12443708.
- Phillips JD, Kim CS, Fonkalsrud EW, Zeng H, Dindar H. Effects of chronic corticosteroids and vitamin A on the healing of intestinal anastomoses. *Am J Surg.* 1992;163(1):71-7. doi: 10.1016/0002-9610(92)90255-p. PubMed PMID: 1733376.
- Jahne J. Cytoreduction including total gastrectomy for pseudomyxoma peritonei (Br J Surg 2002; 89: 208-12). *Br J Surg.* 2002;89(7):938-9; discussion 9. doi: 10.1046/j.1365-2168.2002.02161_4.x. PubMed PMID: 12081750.
- Glehen O, Osinsky D, Cotte E, Kwiatkowski F, Freyer G, Isaac S, et al. Intraperitoneal chemohyperthermia using a closed abdominal procedure and cytoreductive surgery for the treatment of peritoneal carcinomatosis: morbidity and mortality analysis of 216 consecutive procedures. *Ann Surg Oncol.* 2003;10(8):863-9. doi: 10.1245/aso.2003.01.018. PubMed PMID: 14527903.
- Jafari MD, Halabi WJ, Stamos MJ, Nguyen VQ, Carmichael JC, Mills SD, et al. Surgical outcomes of hyperthermic intraperitoneal chemotherapy: analysis of the american college of surgeons national surgical quality improvement program. *JAMA Surg.* 2014;149(2):170-5. doi: 10.1001/jamasurg.2013.3640. PubMed PMID: 24352601.
- Verwaal VJ, van Ruth S, de Bree E, van Sloothen GW, van Tinteren H, Boot H, et al. Randomized trial of cytoreduction and hyperthermic intraperitoneal chemotherapy versus systemic chemotherapy and palliative surgery in patients with peritoneal carcinomatosis of colorectal cancer. *J Clin Oncol.* 2003;21(20):3737-43. doi: 10.1200/JCO.2003.04.187. PubMed PMID: 14551293.
- Blaj S, Nedelcut S, Mayr M, Leebmann H, Leucuta D, Glockzin G, et al. Re-operations for early postoperative complications after CRS and HIPEC: indication, timing, procedure, and outcome. *Langenbecks Arch Surg.* 2019;404(5):541-6. doi: 10.1007/s00423-019-01808-8. PubMed PMID: 31352505.
- Jaehne J. Cytoreductive procedures-strategies to reduce postoperative morbidity and management of surgical complications with special emphasis on anastomotic leaks. *J Surg Oncol.* 2009;100(4):302-5. doi: 10.1002/jso.21328. PubMed PMID: 19697435.
- Yamaguchi R, Terashima H, Yoneyama S, Tadano S, Ohkohchi N. Effects of platelet-rich plasma on intestinal anastomotic healing in rats: PRP concentration is a key factor. *J Surg Res.* 2012;173(2):258-66. doi: 10.1016/j.jss.2010.10.001. PubMed PMID: 21074782.
- Makrin V, Lev-Chelouche D, Even Sapir E, Paran H, Rabau M, Gutman M. Intraperitoneal heated chemotherapy affects healing of experimental colonic anastomosis: an animal study. *J Surg Oncol.* 2005;89(1):18-22. doi: 10.1002/jso.20161. PubMed PMID: 15612012.
- Pelz JO, Doerfer J, Decker M, Dimmler A, Hohenberger W, Meyer T. Hyperthermic intraperitoneal chemoperfusion (HIPEC) decrease wound strength of colonic anastomosis in a rat model. *Int J Colorectal Dis.* 2007;22(8):941-7. doi: 10.1007/s00384-006-0246-y. PubMed PMID: 17245567.
- Aarts F, Bleichrodt RP, de Man B, Lomme R, Boerman OC, Hendriks T. The effects of adjuvant experimental radioimmunotherapy and hyperthermic intraperitoneal chemotherapy on intestinal and abdominal healing after cytoreductive surgery for peritoneal carcinomatosis in the rat. *Ann Surg Oncol.* 2008;15(11):3299-307. doi: 10.1245/s10434-008-0070-4. PubMed PMID: 18712445.
- Ziegler TR, Bazargan N, Leader LM, Martindale RG. Glutamine and the gastrointestinal tract. *Curr Opin Clin Nutr Metab Care.* 2000;3(5):355-62. doi: 10.1097/00075197-200009000-00005. PubMed PMID: 11151079.
- Mertes N, Schulzki C, Goeters C, Winde G, Benzing S, Kuhn KS, et al. Cost containment through L-alanyl-L-glutamine supplemented total parenteral nutrition after major abdominal surgery: a prospective randomized double-blind controlled study. *Clin Nutr.* 2000;19(6):395-401. doi: 10.1054/clnu.2000.0142. PubMed PMID: 11104589.
- Kuhn KS, Schuhmann K, Stehle P, Darmaun D, Furst P. Determination of glutamine in muscle protein facilitates accurate assessment of proteolysis and de novo synthesis-derived endogenous glutamine production. *Am J Clin Nutr.* 1999;70(4):484-9. doi: 10.1093/ajcn/70.4.484. PubMed PMID: 10500016.
- Miller AL. Therapeutic considerations of L-glutamine: a review of the literature. *Altern Med Rev.* 1999;4(4):239-48. PubMed PMID: 10468648.
- Cruzat VF, Bittencourt A, Scorzazon SP, Leite JS, de Bittencourt PI, Jr., Tirapegui J. Oral free and dipeptide forms of glutamine supplementation attenuate oxidative stress and inflammation induced by endotoxemia. *Nutrition.* 2014;30(5):602-11. doi: 10.1016/j.nut.2013.10.019. PubMed PMID: 24698353.
- Da Costa MA, Campos AC, Coelho JC, de Barros AM, Matsumoto HM. Oral glutamine and the healing of colonic anastomoses in rats. *JPEN J Parenter Enteral Nutr.* 2003;27(3):182-5; discussion 5-6. doi: 10.1177/0148607103027003182. PubMed PMID: 12757111.
- Gökpinar I, Gürleyik E, Pehlivan M, Özcan Ö, Özyayın İ, Aslaner A, et al. Early enteral and glutamine enriched feeding ameliorates healing of colonic anastomosis. *Turkish Journal of Trauma and Emergency Surgery.* 2006;12(1):17-21. PubMed PMID: 16456746.

This paper has been checked for language accuracy by JOSAM editors.
The National Library of Medicine (NLM) citation style guide has been used in this paper.