

A case of multiple sclerosis diagnosed with tuberculosis during teriflunomide therapy

Rabia Gökçen Gözübatık-Çelik, Musa Öztürk

Department of Neurology, Bakirkoy Training and Research Hospital for Psychiatry and Neurological Disorders, University of Health Sciences, Istanbul, Turkey

ORCID ID of the author(s)

RGÇ: 0000-0002-1598-5944
MÖ: 0000-0001-9652-384X

Abstract

A case of pulmonary tuberculosis (TB) in a patient with multiple sclerosis (MS) receiving teriflunomide is described. A 59-year-old woman with MS started interferon beta-1a treatment in 2009. Due to side effects, her physician switched her to glatiramer acetate. Over the last three years, she opted not to continue the glatiramer acetate. At the end of 2017, her symptoms reappeared, and her radiological and clinical examination showed disease progression. Teriflunomide (14 mg/day) treatment was started, and in the 15th month of teriflunomide use, a rash on the skin, coughing, night sweating fits, weakness and back pain developed. She was diagnosed with pulmonary TB based on pulmonary examination. Her purified protein derivative (PPD) score was 22. Anti-TB therapy was initiated immediately. At last visit in January 2020, TB was discovered. Her blood tests were within normal limits. Her expanded disability status score (EDSS) score was 2.5. Subcutaneous glatiramer acetate was re-initiated. A rare case of pulmonary TB under teriflunomide use is described in this case. Teriflunomide therapy should be considered in cases in which latent TB may be re-activated.

Keywords: Pulmonary tuberculosis, Multiple sclerosis, Teriflunomide

Corresponding Author

Rabia Gökçen Gözübatık-Çelik
Department of Neurology, Bakirkoy Training and Research Hospital for Psychiatry and Neurological Disorders, University of Health Sciences, Istanbul, Turkey
E-mail: gokcen3@hotmail.com

Informed Consent

The authors stated that the written consent was obtained from the patient presented with images in the study.

Conflict of Interest

No conflict of interest was declared by the authors.

Financial Disclosure

The authors declared that this study has received no financial support.

Previous Presentation

This case was presented at the 11. Clinical Neuroimmunology Symposium. (19-21 Nov.2020, Istanbul, Turkey)

Published

2022 April 24

Copyright © 2022 The Author(s)

Published by JOSAM

This is an open access article distributed under the terms of the Creative Commons Attribution-Non Commercial-NoDerivatives License 4.0 (CC BY-NC-ND 4.0) where it is permissible to download, share, remix, transform, and build upon the work provided it is properly cited. The work cannot be used commercially without permission from the journal.



Introduction

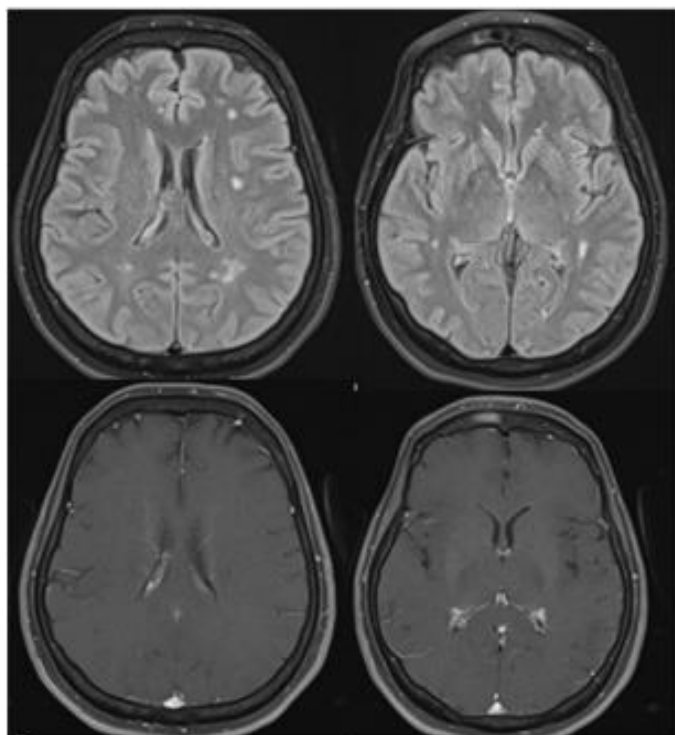
Tuberculosis (TB) is an infectious disease that is triggered by respiratory transmission of the bacterium, *Mycobacterium tuberculosis*, which may spread via the lympho-hematogenic pathway into all organs. While TB's incidence is decreasing, it can still be fatal due to latent infection in immunocompromised people. Teriflunomide is an anti-inflammatory immunomodulatory/immunosuppressive medication that is classified as safe and effective in multiple sclerosis (MS) patients [1]. The case of pulmonary TB in a patient with MS receiving teriflunomide is described.

Case presentation

The necessary permission was obtained from the patient to share her information.

A 59-year-old female patient presented to our hospital for the first time in 2009, and interferon beta 1a treatment was started after a diagnosis of MS was obtained. Due to allergic responses, treatment-related issues, and flu-like effects, her drugs were changed more regularly without any causing any problems. However, the patient had not received medical care and had not received glatiramer acetate for almost three years at her own discretion. At the end of 2017, the patient approached our clinic for a short walking distance test. Radiological and clinical analyses revealed disease progression (Figure 1). Her expanded disability status score (EDSS) score was 2.5. Teriflunomide (14 mg/day) was ordered for the patient since she requested oral medication. A skin rash, coughing, night sweats, fatigue, and back pain during the 15th month of teriflunomide treatment developed. Thorax computed tomography (CT) results in combination with a pulmonary examination identified pulmonary TB. Her purified protein derivative (PPD) score was 22 (normal range: 0-15). Her blood tests were within normal limits. No additional risk factors for tuberculosis were found. She immediately began therapy with ethambutol 1000 mg/day, pyrazinamide 1000 mg/day, isoniazid 300 mg/day, and rifampicin 600 mg/day. Those treatments ended after the recommended time. She was free of TB at her last visit in January 2020, and her blood tests were within the normal limits. Her EDSS score was 2.5. Subcutaneous glatiramer acetate was then reinitiated.

Figure 1: Multiple demyelinating lesions of the patient. The first row shows axial FLAIR, and the second row shows the corresponding contrast-enhanced axial T1-weighted images



Discussion

Teriflunomide presents clear, reliable, and achievable protection and tolerability profiles as reported in the literature, and no evidence of an elevated risk of any infection in placebo-

controlled trials has been found (Teriflunomide versus placebo: 52.7% versus 53.4% or serious infection 2.7% versus 2.2%). This drug also presents a risk for causing severe opportunistic infections in 0.2% of patients. Lymphopenia and neutropenia were confirmed to occur in the first three months of diagnosis, but this prevalence did not reach 15% [1].

Teriflunomide causes a decrease in T-cell activation by altering integrin activity and intracellular calcium signals leading to a shift in the immune cytokine profile to anti-inflammatory T-helper 2. It may also affect components of the innate immune system by modifying the role of adhesion molecules, neutrophils, and macrophages and causing an increase in interleukin-10 (IL-10) secretion by macrophages and microglia [2]. The IL-10 cytokine family has a significant function in TB. IL-10 and -26 suppress antimycobacterial immunity, creating a suitable environment for TB survival [3].

As a treatment for multiple sclerosis (MS), immunomodulators and immunosuppressive therapies are commonly used, but long-term follow-up is important, particularly in terms of side effects, such as activation or reactivation of latent infection. TB cases under interferon-beta-1a among other therapies have been reported in the literature [4]. Distinct mechanisms that control gene expression during TB infection have been found. However, the mechanism by which *Mycobacterium tuberculosis* causes development of interferon-stimulated genes in human macrophages is currently unknown [5]. A case of TB-related meningitis has also been documented under fingolimod therapy, which is one of the new oral treatments; however, the main mechanism for meningitis development needs to be clarified. The underlying mechanism can be explained by fingolimod-induced effects on the lymph nodes affecting T- and B-cells and by causing a reduction in the number of lymphocytes in the peripheral blood. The loss of peripheral lymphocytes impairs immune function and triggers serious infection, such as varicella-zoster virus [6].

Conclusion

Immunosuppression primarily occurs due to lymphopenia/neutropenia-induced opportunistic infections. However, infection can also be caused by different pathways, such as interleukin pathways, without influencing the number of cells. Therefore, it is necessary to evaluate patients undergoing these treatments in detail, particularly for TB in clinically suspicious cases. It should be emphasized that patients who use different immunosuppressive-immunomodulatory therapies should be followed more closely in terms of opportunistic infection development.

References

- Comi G, Freedman MS, Kappos L, Olsson TP, Miller AE, Wolinsky JS, et al. Pooled safety and tolerability data from four placebo-controlled teriflunomide studies and extensions. *Mult Scler Relat Disord*. 2016;5:97-104. doi: 10.1016/j.msard.2015.11.006.
- Oh J, O'Connor PW. An update of teriflunomide for treatment of multiple sclerosis. *Ther Clin Risk Manag*. 2013;9:177-90. doi: 10.2147/TCRM.S30947.
- Abdalla AE, Lambert N, Duan X, Xie J. Interleukin-10 Family and Tuberculosis: An Old Story Renewed. *Int J Biol Sci*. 2016;27:12(6):710-7. doi: 10.7150/ijbs.13881.
- Sirbu CA, Dantes E, Plesa CF, Axelerad AD, Ghinescu MC. Active Pulmonary Tuberculosis Triggered by Interferon Beta-1b Therapy of Multiple Sclerosis: Four Case Reports and a Literature Review. *Medicina*. 2020;56:1-7. doi: 10.3390/medicina560402025.
- Zhou X, Yang J, Zhang Z, Zhang L, Zhu B, Lie L, et al. Different Signaling Pathways Define Different Interferon-Stimulated Gene Expression during Mycobacteria Infection in Macrophages. *Int J Mol Sci*. 2019;20:1-14. doi: 10.3390/ijms20030663.
- Köseoğlu M, Gözübatık-Çelik RG, Kürtüncü M. A case report with tuberculous meningitis during fingolimod treatment. 2020;46:102450. doi: 10.1016/j.msard.2020.102450.

The National Library of Medicine (NLM) citation style guide has been used in this paper.