

Results of applying autologous multipotent mesenchymal stromal stem cells in liver cirrhosis treatment

Karaciğer sirozu tedavisinde otolog multipotent mezenkimal stromal kök hücresi uygulanması ve sonuçları

B.A. AGAYEV¹, R.M. AGAYEV¹, A.G. POPANDOPULO², R.E. JAFARLI¹

¹Azerbaijan Medical University, Baku, Azerbaijan

²Biostem International Biotechnology Center, V.K.Gusak Institute of Emergency and Reconstructive Surgery (NAMS), Donetsk, Ukraine

Background and Aims: Increase in the number of liver cirrhosis, lack of the sufficient number of donors, high rates of post-operative complications, mortality rates, as well as material and technical shortcomings make search of effective and favorable treatment methods actual. From this point of view, clinical effects of stem cell transplantation captured our attention. The aim of this study is to evaluate the influence of autologous multipotent mesenchymal stromal stem cell transplantation on the morphofunctional state of liver during liver cirrhosis. **Materials and Methods:** For this purpose; experiments were conducted on 49 white male rats (Wistar), 150-180 g weight, minimum of 3 months old. Because they have minimal immunological mismatch in comparison with allogeneic cells, autologous multipotent mesenchymal stromal stem cells were used for the experiments. Liver cirrhosis was modeled in all the experimental animals. To carry out comparative assessment of the effectiveness of the transplantation methods of autologous multipotent mesenchymal stromal stem cell, animals were divided into 2 groups. The first group contained 23 rats with autologous multipotent mesenchymal stromal stem cell implanted through the portal vein; the second group (24 rats) contained animals with autologous multipotent mesenchymal stromal stem cell implanted into the main liver artery. Comparative study of the effectiveness of treatment was carried out based on the morphofunctional state of the liver. **Results:** The analysis of histomorphologic and biochemical examination results showed higher effectiveness of transarterial transplantation of autologous multipotent mesenchymal stromal stem cell into the liver as compared to the intraportal method. It was confirmed by more active regeneration of liver parenchyma, as well as more rapid restoration of functional tests of the liver. **Conclusion:** Obtained results prove that application of stem cells will be an alternative treatment for organ transplantation in the treatment of liver cirrhosis in the immediate future.

Key words: Liver cirrhosis, autologous multipotent mesenchymal stromal stem cell transplantation

INTRODUCTION

A significant increase in liver cirrhosis (LC) has been observed in recent population studies compared to other diseases (1,2). Liver cirrhosis is characterized by a chronic and progressive disease course that results in high mortality rates (3,4). Medicamentous treatment is generally

Giriş ve Amaç: Karaciğer sirozu sayısındaki artış, yeterli sayıda donör olmaması, post-operatif komplikasyon oranlarının yüksekliği, mortalite oranları yanı sıra malzeme ve teknik yetersizlikler etkili ve uygun tedavi yöntemleri aranmasını gerekli kılmaktadır. Bu açıdan bakıldığında, kök hücre nakli ve klinik etkileri bizim dikkatimizi çekmiştir. Bu çalışmanın amacı, karaciğer sirozu sırasında karaciğerin morfo-fonksiyonel durumuna otolog multipotent mezenkimal stromal kök hücre nakli etkisini değerlendirmektir. **Gereç ve Yöntem:** Bu deney için 49 beyaz, 150-180 g ağırlıkta, en az 3 aylık ve üzeri (Wistar) fare kullanılmıştır. Allojenik hücreler ile karşılaştırıldığında çok küçük bir immünolojik uyumsuzluk olması nedeniyle otolog multipotent mezenkimal stromal kök hücreler bu deneyler için kullanılmıştır. Deney hayvanlarının hepsinde karaciğer sirozu modellenmiştir. Otolog multipotent mezenkimal stromal kök hücre nakli yöntemlerinin etkinliğini karşılaştırmalı bir değerlendirme yapmak için, hayvanlar 2 gruba ayrıldı. Birinci grup portal ven yoluyla otolog multipotent mezenkimal stromal kök hücre implante 23 sıçandan oluşurken; ikinci grup (24 fare), ana karaciğer arteri içine otolog multipotent mezenkimal stromal kök hücre implante edilen hayvanları içermektedir. Tedavinin etkinliği karaciğerin morfo-fonksiyonel durumu temelinde karşılaştırmalı olarak değerlendirilmiştir. **Bulgular:** Histomorfolojik ve biyokimyasal muayene sonuçlarının analizi karaciğere transarteriyel otolog multipotent mezenkimal stromal kök hücre transplantasyonunun intraportal metoda göre daha etkili olduğunu göstermiştir. Bu, II. grup farelerde karaciğer parenkiminin daha etkin şekilde rejenerasyonu, hem de karaciğer fonksiyonlarının daha esnek restorasyonu ile kendini göstermiştir. **Sonuç:** Elde edilen sonuçlar karaciğer sirozu tedavisinde kök hücre uygulamasının yakın gelecekte organ nakli için alternatif bir tedavi olacağını kanıtlamaktadır.

Anahtar kelimeler: Karaciğer sirozu, otolog multipotent mezenkimal stromal kök hücre nakli

used in order to decrease the influence of etiopathogenic factors, increase the regenerative functions of the liver parenchyma and correct metabolic changes occurring in the organism (1). Despite some positive results, current methods used for the correction of LC are limited, and

Correspondence: Rasim JAFARLI
Department of Surgical Disease Azerbaijan Medical University
City of Baku, Republic of Azerbaijan
E-mail: dr-jafarli@mail.ru

Manuscript Received: 01.12.2014 • Accepted: 12.12.2014

in most cases, result in progression of the disease to the decompensation stage (3). According to the literature, patients in the compensation stage have a survival prognosis of 10 years, while prognosis for survival of patients that have reached the decompensation stage is, at most, 2 years (4).

There are many surgical treatments proposed, (5) with liver transplantation currently considered the best treatment choice (1). However, Western statistics show that the number of patients who require a liver transplant increases each year, up to 15% annually (2), but the lack of donors, high rates of post-operative complications, mortality rates, and complicated logistical requirements lends to the argument that new treatment options are needed (5).

One area of increasing interest is cell transplantation (7) with stem cells holding a special place (8). Researchers, who have performed both basic and clinical research, have discovered that stem cells transplantation can be helpful in the stimulation of the regeneration processes in damaged parenchymal tissues (9). Others report of positive clinical results assert that stem cell transplantation might one day be used as an alternative to organ transplantation (10-13). In the light of the unmet need, recent studies and interest in stem cell transplantation, it is pertinent to study the effectiveness of various autogenous stem cell transplantation methods on the morphofunctional state of liver due to cirrhotic changes.

The aim of this study is to evaluate the influence of autologous multipotent mesenchymal stromal stem cell (AMMSSC) transplantation on the morphofunctional state of liver during LC.

MATERIALS and METHODS

Research was based on a collaboration between "Bios-tem" international biotechnology center of the "University of Emergency and Recovery Surgery named after V.K.Gusak" Donetsk, Ukraine and the Scientific Research Center of "Azerbaijan State Medical University".

Experiments were conducted on 49 white male rats (Wistar), 150-180 weight, minimum of 3 months old. All the experiments were performed in compliance with the "European Convention for the Protection of Vertebrate Animals used for Experimental and other Scientific Purposes" (12).

Obtaining autologous multipotent mesenchymal stromal stem cells

AMMSSCs were used for the experiments because these have minimal immunological mismatch in comparison

with allogeneic cells. Before any signs of LC or portal hypertension model formation were present, AMMSSCs were obtained from the femur bone of the amputated lower extremity of tested rats. Ketamine in dosage of 90 mg/kg was used as an animal anesthetic.

Following amputation, the mortality rate among the rats was 4.1% (2 rats- due to the pain component and post-operative bleeding). After the amputation of the lower extremity, the diaphysis cavity was aseptically cleaned with Dulbecco's phosphate buffered saline by puncturing the knee joint and distal diaphysis of femur bone. The obtained suspension was mixed with Hens solution ("Biolot", Russia) in a ratio of 1:1.25. In 5 ml test tubes filled with Histoplaque 1077 (Sigma, USA), bone marrow was added layer by layer (in ratio 1:1) and centrifuged for 30-40 minutes at 1800-2000 revolutions per minute at room temperature. Created interphase ring of the nuclear component of bone marrow was washed with Hens solution and centrifuged for 8-10 minutes at 800-1000 revolutions per minute. The washing procedure was repeated 3 times. Occurring sediment that contained DMEM/F12 (Sigma, USA), 20% of ETS ("Biolot", Russia), was mixed in mitogenic environment and poured in a plastic flask (Nuvlon, USA) with 1-2x10⁵ kl/sm² density and 75 sm² area. It was then placed into CO₂-incubator (37 C; 5% CO₂). 3 days after replacement of DMEM/F12 environment, containing 10% ETS, 2mM L- Glutamine and 10⁻⁴M 2-merkapttoetanol (Sigma, USA), with IMDM environment, non-adhesive (hemopoetic) cells were extracted, and the obtained MMS Cells were cultivated for 42 days. It was obligatory to follow sterilization procedures in order to avoid possible bacterial and viral contaminations (12,13). Obtained cells were frozen and held in cryo- containers for approximately 52±3.6 days. During further transplantations, AMSS Cells were unfrozen right before the operation and transplantation was then performed.

Modeling of LC

Fifteen days after lower extremity amputation, LC in experimental rats was achieved by subcutaneous appliance of CCL4 (it was calculated as 0.3 ml per 100 gr animal weight) twice per week, subcutaneous for 12 weeks. All the animals were kept in vivarium environment where they had free access to food and water. LC in experimental rats was diagnosed according to the presence of biochemical [serum alanine aminotransferase (ALT), aspartate aminotransferase (AST), lactic dehydrogenase (LDH) Albumin], morphological (connective tissue, formation of septical and false portions accompanied with fibrosis, dystrophy and hepatocellular necrosis) and ultrasound signs.

At the stage of modeling of LC, mortality rate among observed animals constituted 8.5% (4 of 47 rats).

Transplantation of AMSSC

Currently, many scientists who work on in the field of AMSSC transplantation propose different pathways of implantation. We decided to investigate AMSSC implantation through intraportal and intra-arterial (main liver artery) pathways. In order to find out the effectiveness of AMSSC transplantation methods during our comparative study, experimental animals were divided into 2 groups: the first group contained 23 rats with AMSSC implanted through the portal vein; the second group (24 rats) contained animals with AMSSC implanted into the main liver artery.

Before the transplantation, all animals were sedated with 90 mg/kg Ketamine and 90 mg/kg xylazine. AMSSC was injected into the testing animal's main liver artery or portal vein by means of 0.4x8 mm insulin syringe during laparotomy with a single 1 ml dose in count of 2.0×10^6 cells per 100 gram of animal mass.

Mortality rates during transplantation was observed in 2 (8.7%) of the intra-portal rats; and 2 (8.3%) in intra-arterial rats; injections were calculated as 8.5%. In 3 cases, mortality was explained by perioperative bleeding that occurred in the injection area (1 rat (4.2%)) during intra-arterial injection; and 2 rats (8.7%) during intra-portal injection). In a case (4.3%) from the first testing group, dissection was performed to determine the reason for mortality and was found to have resulted from portal vein thrombosis. It is to be noted that in all other cases during both intra-portal and intra-arterial injections to stop perioperative bleedings, haemostatic sponges were used.

Histomorphological studies

Modelisation of LC and dynamics of the research were performed to identify effectiveness of AMSSC as a treatment option for LC. A biopsy was performed transcutaneous with ultrasonography assistance under local anesthetics before the transplantation (LC was already present) and 8 weeks after the treatment with stem cells. Biopsy samples were taken from V and VI liver segments.

To perform light microscopy, biomaterial was kept in 10% neutral formaldehyde during 24 hours. Afterwards, it was washed under running water for 2-3 hours, then dehydrated with alcohol, and finally paraffin was added accordingly to the standard method. 4-5 μm paraffin cuts were defatted, heated and were covered with a thin layer of egg white and glycerin for a good fixation. Sam-

ples were then glued to the sample glasses using a wet method. Cell samples were colored with hematoxylin and eosin to estimate cell morphology, to estimate lipids we used Sudan -S, and for visualization of the fibrotic process - paraffin sections stained by Van Gieson; samples were studied under optic light microscope. Liver fibrosis was determined through the ratio of the volume of the connective tissue in the parenchyma to the studied volume of the visual field. Calculation was performed on specimens stained by Van Gieson method, which is a specific method for the detection of connective tissue. In this case, on the medication, nuclei are visualized black, and connective tissue fibers - red.

The analysis was performed by light microscopic analysis with 400x microscope magnification. Calculation was performed by ocular measuring grid by G.G. Avtandilov (Figure 1).

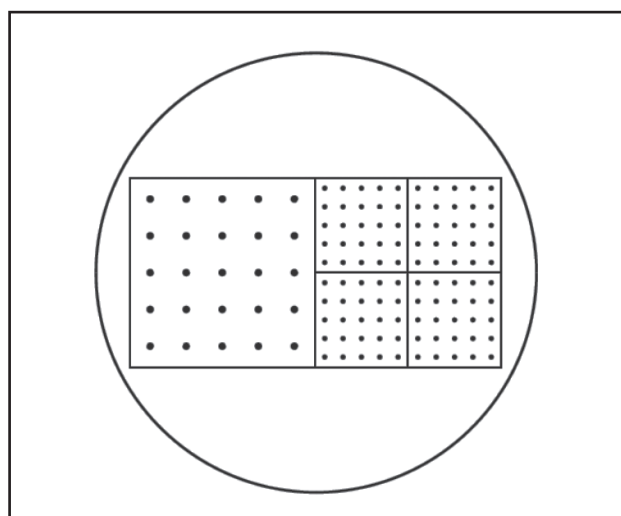


Figure 1. Ocular measuring grid (Avtandilov G.G., 1990)

The grid shown on the figure is designed for cytohistotereometric studies. It consists of a square, with 25 uniformly arranged points used in the determination of the quantification of the degree of fibrosis, i.e., the studied area of parenchyma was conditionally evaluated in quantitative measurements. It should be noted that this calculation in the dynamics of treatment of studied patients allowed us to study the replacement of the fibrodegenerated area of liver parenchyma with normal tissue on the background of transplantation into the last AMSSC.

To study the effectiveness of transplantation of AMSSC into liver in the treatment of LC, the obtained biopsates were also exposed to immunohistochemical analysis of the following parameters:

1. First of all, we assessed proliferative activity of hepato-

cytes in observed groups of animals by determination of expression of the proliferating cell nuclear antigen (PCNA) at various stages of investigations.

2. We determined activation of myofibroblasts in the observed liver parenchyma by the study of the degree of expression of alpha-smooth muscle actin (a-SMA). It shall be noted that a-SMA is a smooth muscle protein. It is a marker of myofibroblasts which is localized only in the muscular layer of vessels of the unchanged liver.

In LC, perisinusoidal cells transdifferentiate into myofibroblasts increase of which is followed by massive collagen synthesis and progress of fibrosis.

3. The degree of capillarization of sinusoids in the liver was assessed by the determination of expression of CD34. It shall be noted, that CD34 is a glycoprotein localized mainly on the external surface of membranes of endothelial cells in liver, as well as progenitor hemopoietic cells.

Most often they are determined as a marker highlighting stems cells in the circulatory bed.

In our investigations it was determined as a marker of the endothelium of liver sinusoids. It is noteworthy that endothelium of liver sinusoids is different from endothelium of other organs. It is fenestrated, it does not have a basal membrane and CD34 at all.

Determination of CD34 in the endothelium of sinusoids appears only during their capillarization. The latter form in case when in the LC specific space of Disse there form a perisinusoidal fibrosis.

Accumulation of collagen on the developing pathologic background is followed by the formation of an atypical basal membrane in the endothelium of sinusoids and leads to the defection of diffusion of matters from the blood stream into hepatocytes.

It is obvious from the above that detection of CD34 in bioplates allows to judge on the microhemodynamic defect in liver sinusoids.

Immunohistochemical staining with commercial monoclonal antibodies was carried out by means of the Novolink visualization system.

Below is the list of used monoclonal antibodies:

1. CD34 (clone QBEnd/10, Novocastra, UK, 1:75 dilution);
2. PCNA (clone PC10, Novocastra, UK, 1:100 dilution);
3. a-SMA (clone 1A4, Dako, Denmark, 1:50 dilution).

Received digital data was statistically processed with variable statistic method using X² criteria. Calculations were performed by using EXCELL (2007) program on a private computer.

RESULTS and DISCUSSION

To find out liver function properties in the experimental animals, first primary criteria rates were calculated. As mentioned previously, all of the patients underwent general clinical blood research to study the liver in the dynamics of morphofunctional state of treatment. Obvious evidences of AMMSSC transplantation are shown in the Table 1.

As we can see from the Table 1, in both cases rats that were treated with AMMSSC showed improvement in the morphofunctional condition of the liver, presented by the recovery of its protein synthesizing function.

As shown in the results of the study, treatment serum protein rates (LC experimental model) were 42.9±2.2 gr/l at the beginning of the study. During this period, albumin rates were estimated as 17,1±2,3 gr/l. These rates are shown to be lower than normal as 25.1% and 42.2% (p<0.001). Due to treatment, serum protein and albumin rates have increased in all of the following experiment groups (Figure 2).

However in our experimental groups we have experienced positive dynamics and the rates were significantly different. After 8 weeks of AMMSSC intraportal injection

Table 1. The results of biochemical examination for different stages of liver functional properties in experimental rats.

| Criteria | Before Transplantation | 8 Weeks After AMMSSC Transplantation | | Norm Rates (Control group) |
|--------------------|------------------------|--------------------------------------|---------------|----------------------------|
| | | Intraportal | Intraarterial | |
| Total protein, g/l | 42,9±2,2 | 47,2±1,5 ** | 52,7±0,96 | 57,3±2,8 |
| Albumin, g/l | 17,1±2,34 | 21,3±0,91 | 24,1±2,4* | 29,6±3,1 |
| ALT, mMol/s*l | 1,422±0,266 | 1,136 ±0,184* | 0,787±0,046 | 0,401 ±0,104 |
| AST, mMol/s*l | 1,728±0,187 | 1,176±0,112 | 0,959±0,194* | 0,602±0,172 |
| LDQ, Unit/l | 398,4±28,9 | 371,3±57,8* | 259,3±54,5 | 190,4±18,6 |

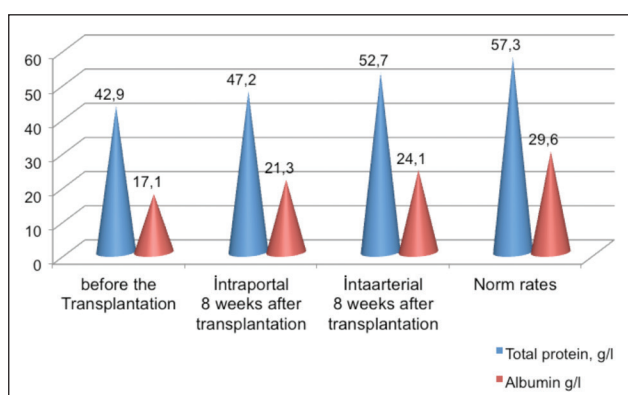


Figure 2. The results of biochemical examination for liver protein synthesis function in experimental rats.

tion treatment, one group showed an increase of criteria rates (Table 1). In comparison with first rates, current rates of serum protein and albumin increased up to 10.02% ($p < 0.05$), 24.6%. According to criteria rates mentioned above, AMSSC treatment with intra-arterial injection was shown to be more effective in comparison with those during intraportal injections. The same criteria rates, if compared after 8 weeks between the two tested groups, show a higher improvement in the II group than in the I group, which are estimated as 13.1% and 11.7% ($p < 0.05$).

Blood serum ALT and AST examinations have also shown significant differences between these groups (Figure 3, Table 1).

ALT and AST results during formation of LC in comparison to normal rates (control groups) have shown a 3.5 and 2.9 time increase ($p < 0.05$).

In the testing rat groups 8 weeks after AMSSC transplantation, a decrease in the above mentioned criteria rates was observed. As the results of the study, in 8 weeks

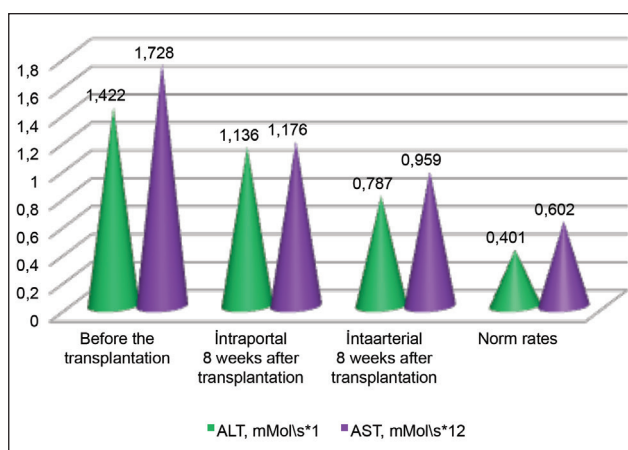


Figure 3. Change of ALT and AST in animals in dynamics of treatment.

the II group of rats treated with AMSSC showed a significant decrease in ALT and AST rates in relation to the control values. During the following period of time, rates were estimated as ALT-0,787±0,057, AST-0,959±0,174 mMol/l In comparison with the same rates of I group, it was shown to be 30.2% and 18.5% decreased.

During the study, before treatment, all tested animal groups had their LDH levels significantly increased [in comparison with average rates a 2.1 times increase was observed ($p < 0.05$)]. Before the treatment started, LDH rates were shown to be 398,4±28,2 Unit/l [norm rates (control groups.) - 190,4±18,6 Units/l].

In the treatment stages using AMSSC transplantation methods it has shown assistance in LDH level normalization. However, AMSSC treatment performed by intra-arterial injection (common hepatic artery) had more significant positive dynamics. During the 8th week of treatment, II group of testing animals demonstrated lower LDH rates than those in the I group, estimated as 30.2% (Figure 4).

According to liver function tests mentioned above, intraportal transplantation demonstrated lower results than those during intra-arterial AMSSC transplantation treatment.

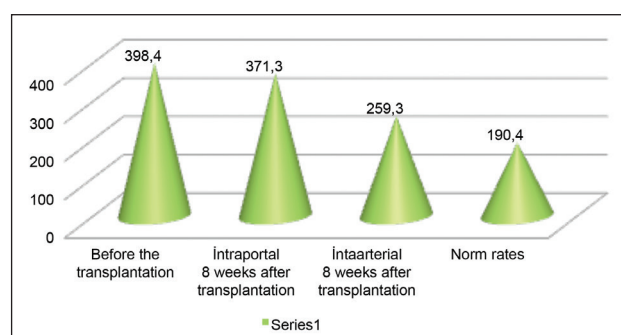


Figure 4. LDH level change in the dynamics of treatment.

Results of histomorphological researches

During the process of making the LC model, histomorphological biopsy materials from the liver showed typical changes in parenchyma tissues (Figure 5A). If liver structure is normally seen as a radial placement of hepatocytes around central veins, during LC formation in histological cuts we can observe replacement of the organ with connective tissue, decompensation, round cells infiltration and the presence of a false portion structure. Hepatocytes differed by their polymorphic signs; among normal cells different nuclears in dystrophic and necrotizing stages was observed. Binuclear cells were rarely

seen. Gathering of neutrophils and lymphocytes were observed around the differed hepatocytes. Many disrupted nuclei were noted.

Fibrosed portal and periportal tracts divided the liver into false portions, swollen endothelial bile capillaries divided lymphatic infiltration of periportal tract.

Histomorphological changes listed above matched with the results of other scientists working on stem cells treatment for LC treatment (5,8,12).

After 8 weeks of AMMSSC treatment, histomorphological biopsy sample examination results demonstrated a decrease of inflammatory- necrotic processes in the parenchyma (Figure 5B and 5C). Among the decrease in hepatocyte necrosis, single subcapsule regeneration areas were

observed. Changes listed above support the presence of reparative and regenerative processes. Even though false portions still remain, more hepatocytes with tinctorial features were observed among the formation of binuclei hepatocytes and enlarged nuclear hepatocytes with light-colored cytoplasm, chromatin and nucleoluses. Also decrease in inflammatory-necrotic processes was observed. Binuclei hepatocytes and enlarged nucleus hepatocytes were found diffusely located in liver parenchyma.

From the resulted listed above it is obvious that different methods of AMMSSC transplantation stimulate regeneration in liver parenchyma. However using intra-arterial injection of AMMSSC during LC leads to obvious intensive regenerative reactions, especially in perivascular area of the liver parenchyma (Figure 5D). II testing group was

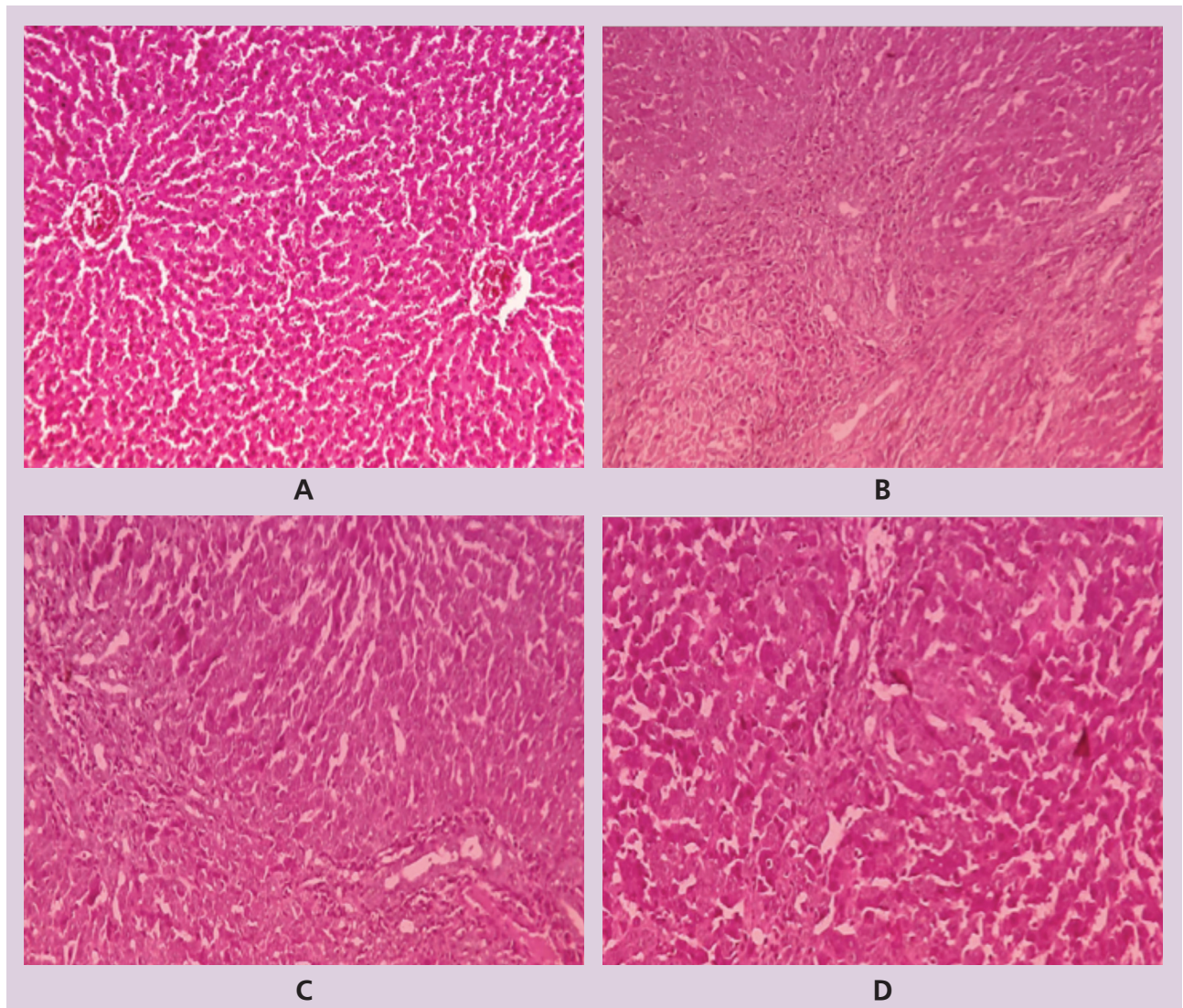


Figure 5. Normal liver cuts of experimental rats {A}, during experimental LC {B}, 8th week after AMMSSC (Pic. C- intraportal, D- intraarterial injections). Coloring with hematoxylin and eosin. Enlargment x 250.

found to increase reparative functions and decrease fibrotic intensity, which was proved during morphological examination.

The investigations showed that at the 8th week of treatment of rats exposed to AMSSC transplantation, the degree of hepatic fibrosis decreased to 0.09 ± 0.02 ($p < 0.05$) as compared to pretreatment results (0.14 ± 0.03). Eight weeks after the AMSSCs transplantation into the liver through the common hepatic artery the degree of hepatic fibrosis decreased to 0.023 ± 0.02 as compared to initial data. The results were significantly different from similar results of animals of the 1st group. This situation also shows advantages of intra-arterial transplantation of AMSSC. 8 weeks after AMSSC transplantation typical sinusoidal capillarization among II group of testing rats was observed at a lower rate compared to the I group. During this time period, intraportal AMSSC transplantation demonstrated more intensive proliferative activity; in comparison with the I group of testing rats it was observed to be 20% higher ($p < 0.01$). Eight weeks after intra-arterial AMSSC transplantation, hepatocyte count was 10% higher, in relation to the control values (normal rates).

After AMSSC transplantation, mortality rate among the test animals was 20.9% (9 of 43 rats), 3 rats (12.5%) died after intraarterial AMSSC transplantation, 6 (26.1%) died after intraportal injection. The animals died within 8 weeks of the observation period (Table 2).

Results of histomorphological testing, along with liver functional condition treatment dynamics in an LC rat

Table 2. Rate of mortality among observed animals (n=49) at different stages of the study

| Stage of Investigation | | Number of Died Animals |
|--|-----------------------|------------------------|
| Amputation of lower extremities | | 4,1%, 2 of 49 rats |
| Modeling of LC | | 8,5%, 4 of 47 rats |
| Intraoperation transplantation of AMSSC | 1 st group | 9,5%, 2 of 21 rats |
| | 2 nd group | 9,1%, 2 of 22 rats |
| Rate of mortality on the 8 th week after the transplantation of AMSSC | 1 st group | 31,6%, 6 of 19 rats |
| | 2 nd group | 15%, 3 of 20 rats |

model, demonstrated the advantage of intra-arterial AMSSC transplantation over intraportal transplantation; intra-arterial AMSSC transplantation perivascular area latters in liver parenchyma increase their life function, and factors for multiplying and proliferation are also seen to be increased. In our opinion morphofunctional changes in venous channel occur due to high interval index in the portal vein during LC as well as decrease of liver artery resistance index. Changes mentioned above demonstrated a decrease of connective tissue, which was characterized as due to paracrine features influenced by transplanted AMSSC.

This study shows the possibility of using stem cell methods as an alternative to organ transplantation in the near future, its perspectives, and serves as proof that further research in this direction are still topical.

REFERENCES

- Brown RS Jr. Live donors in liver transplantation. *Gastroenterology* 2008;134:1802-13.
- Kamel IR, Raptopoulos V, Pomfret EA, et al. Living adult right lobe liver transplantation: imaging before surgery with multidetector multiphase CT. *AJR Am J Roentgenol* 2000;175:1141-3.
- Salama H, Zekri A, Zern M. Efficacy of autologous stem cell transplantation in 57 patients with end stage chronic liver disease. *Cell Trans-plant* 2010;19:1475-86.
- Terai S, Ishikawa T, Omori K, et al. Improved liver function in liver cirrhosis patients after autologous bone marrow cell infusion therapy. *Stem Cell* 2006;24:2292-8.
- Lee SJ, Kim KH, Park KK. Mechanisms of fibrogenesis in liver cirrhosis: The molecular aspects of epithelial-mesenchymal transition. *World J Hepatol* 2014;6:207-16.
- Terai S, Ishikawa T, Omori K, et al. Improved liver function in patients with liver cirrhosis after autologous bone marrow cell infusion therapy. *Stem Cells* 2006; 24; 2292-8.
- Filomeno P, Dayan V, Touriño C. Stem cell research and clinical development in tendon repair. *Muscles Ligaments Tendons J.* 2012;2:204-11.
- Li T, Zhu J, Ma K, et al. Autologous bone marrow-derived mesenchymal stem cell transplantation promotes liver regeneration after portal vein embolization in cirrhotic rats. *J Surg Res* 2013;184:1161-73.
- Yuan SF, Jiang T, Sun LH, et al. Use of bone mesenchymal stem cells to treat rats with acute liver failure. *Genet Mol Res* 2014;13:6962-80.
- Phinney D, Prockop D. Concise review: mesenchymal stem/multipotent stromal cells: the state of transdifferentiation and modes of tissue repair-current views. *Stem Cells* 2007; 25:2896-902.
- Zhan YT, Wei L, Chen HS, et al. Differentiation of bone marrow stem cells in rat hepatic fibrogenesis environment. *Zhonghua Gan Zang Bing Za Zhi* 2003;11:673-5.
- Sun L, Fan X, Zhang L, et al. Bone mesenchymal stem cell transplantation via four routes for treatment of acute liver failure in rats. *Int J Mol Med* 2014;34:987-96.
- Lin G1, Huang YC, Shindel A, et al. Labeling and tracking of mesenchymal stem cells with edu. *Cytoterapy* 2009;11:864-73.