

Histopathological changes in the rat liver exposed to chronic thinner inhalation

Kronik tiner inhalasyonuna maruz bırakılan sıçanların karaciğerinin histopatolojik değerlendirilmesi

Ahmet Burak TOROS¹, Bülent YAŞAR², Leyla ÖZEL³, Güray KILIÇ⁴

Department of ¹Gastroenterology, Liv Ulus Hospital, İstanbul

Departments of ²Gastroenterology, ³General Surgery and ⁴Pathology, Haydarpaşa Numune Education and Research Hospital, İstanbul

Background and Aims: Organic solvents are liquid substances commonly used in everyday life. These solvents exist in paint (as a thinner), polishes and adhesives. People are exposed to volatile solvents through inhalation, skin contact or oral ingestion. Thinner is used as a narcotic, especially among young people of low socioeconomic level. Thinner abuse has become a growing health issue in our country. The aim of this study was to determine the histopathological changes in a rat liver exposed to chronic thinner inhalation. **Materials and Methods:** This is a randomized trial conducted at the animal care facility of Haydarpaşa Numune Education and Research Hospital. Forty male Albino-Wistar rats were used throughout the study. Three groups of rats inhaled thinner in a glass cage for 1, 3 or 5 weeks, respectively. Ten rats that inhaled only room air served as the control group. **Results:** Focal necrosis, granuloma, piecemeal necrosis, and portal inflammation were established in the liver, and these histopathological changes became more prominent as the exposure period extended. There was no significant difference between groups regarding bile duct damage. **Conclusions:** On the basis of histopathological evaluations, it was shown that exposure to chronic thinner inhalation causes detectable damage to the liver, which becomes more prominent as the exposure period prolongs.

Keywords: Drug users, inhalation, liver, thinner

INTRODUCTION

Organic solvents are liquid substances commonly used in everyday life at home and in industrial workplaces. These solvents are found primarily in paint (as thinner), polishes, adhesives, typewriter correction fluids, and dry cleaner solutions (1-3).

Cellulosic thinner is a mixture of solvents comprising hydrocarbons, esters, glycol esters, ketones, and alcohol, and is used to decrease the viscosity of a variety of nitrocellulose-based paints and varnishes for ease of use (4).

People are exposed to volatile solvents by way of inhalation, through skin contact or oral ingestion. Many are ex-

Giriş ve Amaç: Organik çözücüler günlük yaşamda sık kullanılan sıvı maddelerdir. Bu çözücüler tiner, cila ve yapıştırıcı olarak boyalarda bulunur. İnsanlar uçucu çözücülere inhalasyon, cilt teması veya oral olarak maruz kalır. Tiner özellikle toplumun düşük sosyoekonomik grubundaki gençler tarafından narkotik olarak kullanılır. Tiner kötüye kullanımı ülkemizde büyüyen bir sağlık sorunu haline gelmiştir. Bu çalışmanın amacı kronik tiner inhalasyonuna maruz kalan sıçan karaciğerindeki histopatolojik değişiklikleri belirlemek ve tinerin sıçan karaciğerinde yarattığı toksik etkileri, uçucu madde bağımlılarına bir uyarı olarak ortaya koymaktır. **Gereç ve Yöntem:** Bu, Haydarpaşa Numune Eğitim ve Araştırma Hastanesi hayvan bakım tesisinde gerçekleştirilen randomize bir çalışmadır. Çalışmada 40 Wistar albino sıçan kullanıldı. Üç grup sıçan sırayla 1,3 ve 5 hafta boyunca cam bir kafeste tiner soludu. On sıçan kontrol grubu olarak sadece oda havası soludu. **Bulgular:** Karaciğerde fokal nekroz, granülom, güve yeniği nekrozu ve portal inflamasyon saptandı ve maruziyet süresi uzadıkça bu histopatolojik değişiklikler daha belirgin hale geldi. Safra kanalı hasarı bakımından gruplar arasında önemli fark yoktu. **Sonuç:** Histopatolojik değerlendirmelere dayanarak, kronik tiner inhalasyonunun karaciğerde maruziyet süresi uzadıkça daha belirgin hale gelen saptanabilir hasara yol açtığı gösterilmiştir.

Anahtar sözcükler: İlaç kullanıcıları, inhalasyon, karaciğer, tiner

posed to inhalation of thinner in industrial areas (1,5,6). Intoxication due to volatile substance inhalation presents itself at first with euphoria, enhanced energy, and disinhibition, followed by relaxation, dizziness, visual and verbal hallucinations, fatigue, and somnolence. In addition, coughing, sneezing, increase in salivation, skin erythema, nausea, vomiting, photophobia, disorientation, diplopia, ataxia, speech disorders, decrease in reflexes, and nystagmus can be seen during its use. Chronic use causes permanent damage to the central nervous system, heart, liver, lungs, and kidneys (1,7-12).

Adress for correspondence: Ahmet Burak TOROS
Emek Mah. Ordu Cad. Kent Life Sitesi A1-3 Blok Daire 30 Sancaktepe 34785
İstanbul, Türkiye • Fax: +90 216 999 05 82
E-mail: aburaktoros@yahoo.com

Geliş Tarihi: 10.06.2013 • **Kabul Tarihi:** 15.08.2013

Thinner abuse has become a growing health issue in our country (13). The aim of this study was to determine the histopathological changes in the rat liver exposed to chronic thinner inhalation and to present its toxic effects on the liver of rats to serve as an example for human thinner addicts.

MATERIALS and METHODS

In this study, the histological changes in the liver due to thinner inhalation were examined in an animal model. Forty male Albino-Wistar rats weighing between 110-160 g were used in the study. Approval was obtained from the Animal Ethics Committee of Haydarpaşa Numune Education and Research Hospital. All rats were fed with standard diet and water. Except during the thinner inhalation periods, the rats were kept in an environment at $22\pm 2^{\circ}\text{C}$, with a 12-hour light/dark cycle. A closed glass cage measuring 50x34x20 cm was used during the period of thinner inhalation. A cellulosic thinner used in industry, containing 63% toluene, 13% acetone, 10% isobutyl acetate, 7,5% isobutanol, and 6,5% butyl glycol was chosen for the study. It was decided to expose the rats to thinner for 20 minutes until loss of the standing up reflex (14).

The rats were randomized into three groups according to thinner inhalation periods as Group 1: 1 week (n=5), Group 2: 3 weeks (n=9), Group 3: 5 weeks (n=10), and control group (n=10).

Thinner inhalation was administered twice-daily for 5 weeks (09:00 am and 15:00 pm). At the end of their inhalation periods, rats were anesthetized with ketamine HCl injected intraperitoneally (100 mg/kg for operation and 200 mg/kg for euthanasia) in accordance with the guidelines, and they were sacrificed according to the weeks of exposure per group (1st, 3rd and 5th weeks); the control group was sacrificed at the end of the 5th week. Then, the livers were dissected.

The tissue samples taken from the liver were fixed with tamponaded formaldehyde. Following the routine procedure, 5-micron slices were obtained from the paraffin blocks. All slides were stained with hematoxylin-eosin. Liver samples were stained with periodic acid Schiff (PAS), PAS diastase, Masson trichrome, and reticulin. The slides were evaluated with Olympus BX50 light microscope (Olympus Co Ltd, Japan) under 4, 10, and 40 magnifications.

All the microscopic slides were examined by the same pathologist, who was double-blinded to the study parameters. The liver slides were evaluated according to the following criteria (which are the standard parameters for

assessing hepatic injury caused by any damaging effect): 1) parenchymal damage-focal necrosis and hydropic degeneration, 2) granuloma, 3) piecemeal necrosis (periportal necrosis), 4) portal inflammation, and 5) bile duct damage.

Liver bile duct damage and granuloma were evaluated as present or absent.

The statistical analysis of this study was done with Graph-Pad Prisma V.3 packet program. The qualitative data were evaluated with χ^2 test.

RESULTS

As a means of determining the histopathological changes in rats exposed to thinner inhalation, groups were exposed to 5 ml of thinner according to the inhalation periods. At the beginning of thinner inhalation, it was observed that the rats gathered at the farthest point possible away from the thinner container in the glass cage. After the first 5 minutes, an increase in movement, tendency to stand on their hind legs, and deeper and accelerated respiration were observed. Between 10-15 minutes, difficulty in walking was observed, and after 15 minutes, the rats could barely stand but continued trying by holding the cage walls, until they just fell over. At approximately 20 minutes, the standing reflex was lost, there was no response to external stimulation, and the rats were observed to lie motionless in the cage. Two of the rats were removed from the cage. Those left inside the cage died after 5 minutes, while the ones outside returned to normal after approximately 30 minutes; they were observed to consume a significant amount of water.

Fur loss and hemorrhage around the nostrils were noticed, beginning at the 1st week of this experimental study. After 3 weeks, the rats began to lose weight. Increases in respiration rate and defecation amount were observed during the experiment. An aggressive increase was observed even in periods during which they were not exposed to thinner inhalation.

A comparison of the parameters obtained from the light microscope evaluation of the liver slides of the control group and the rats sacrificed at weeks 1, 3, and 5 is given in Table 1. According to these results, there was a statistically significant difference in the distribution of focal necrosis ($\chi^2 = 24,67$, $p=0,001$) (Figure 1) between Groups 2 and 3. Group 3 was in the worst condition.

There was a statistically significant difference regarding granuloma development in the liver due to thinner inhalation ($\chi^2=22,93$, $p=0,001$) between Groups 2 and 3 (Table 2).

Table 1. Summary of histopathological data

		Control n	1 st Week n	3 rd Week n	5 th Week n	
Focal necrosis	Absent	2	0	5	0	$\chi^2=24,67$
	Focal	4	4	3	0	
	Diffuse	4	1	1	10	p<0,001
Hydropic degeneration	Absent	0	0	1	2	$\chi^2=7,06$
	Focal	4	1	2	0	
	Diffuse	6	4	6	8	p>0,05
Granuloma	Present	2	0	0	8	$\chi^2=22,93$
	Absent	8	5	10	2	P<0,001
Piecemeal necrosis	Absent	6	5	8	3	$\chi^2=12,86$
	Focal	2	0	0	1	
	Diffuse	2	0	1	6	P<0,05
Portal inflammation	Absent	4	5	5	0	$\chi^2=17,28$
	Focal	4	0	3	4	
	Diffuse	2	0	1	6	P<0,05
Bile duct damage	Present	1	0	2	4	$\chi^2=4,3$
	Absent	9	5	7	6	p>0,05

Table 2. Distribution of the median values of focal necrosis, hydropic degeneration, piecemeal necrosis, and portal inflammation and the 25-75% percentile values

		Control	1 st Week	3 rd Week	5 th Week
Focal necrosis	Median	1,0	1,0	0	2
	25%	0,75	1,0	0	2
	75%	2,0	1,5	1	2
Hydropic degeneration	Median	2	2	2	2
	25%	1	1,5	1	1,5
	75%	2	2	2	2
Piecemeal necrosis	Median	0	0	0	2
	25%	0	0	0	0
	75%	1,25	0	0	2
Portal inflammation	Median	1	0	0	2
	25%	0	0	0	1
	75%	1,25	0	1	2

Absent: 0, Focal: 1, Diffuse: 2

Development of piecemeal necrosis was also statistically significant for Groups 2 and 3 ($\chi^2=12,86$, $p=0,05$) (Figure 2).

There was a statistically significant difference regarding portal inflammation ($\chi^2 = 17,28$, $p=0,05$) (Figure 3) between Groups 1 and 3 and between Groups 2 and 3. There was no statistically significant difference between the inhalation groups regarding bile duct damage.

No fibrosis was detected in any of the samples with Masson-trichrome staining.

DISCUSSION

Industrial thinner is composed of 63% toluene, which causes the side effects (1). The Occupational Safety and Health Administration recommends an exposure limit of 150 ppm (averaged over a normal 8-hour workday) to

ensure that workers can be exposed without adverse effects. When toluene concentration exceeds 2000 ppm, there is risk of death (16). Repeated inhalation of toxic concentrations of thinner induces a wide range of responses in the liver, depending on the concentration and duration of exposure. There are studies reporting hepatic, renal, cardiovascular, and hemopoietic system damage in thinner addicts (1,7,17,18).

Carabez et al. exposed a group of rats to thinner inhalation in a periodic manner for 14 weeks. When the livers of the sacrificed rats were evaluated by electron microscope, changes such as extreme glycogen deposition in hepatocytes, increase in lipid droplets in the cytoplasm, deposition of fibrous-collagen-like material, enlarged Golgi complexes, and increase in lysosome numbers were established (19).

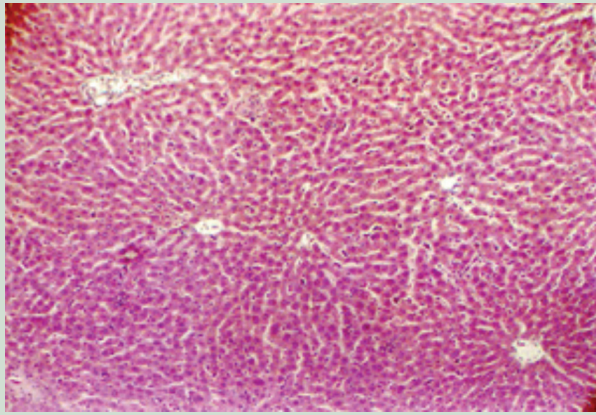


Figure 1. Focal necrosis in rat liver.

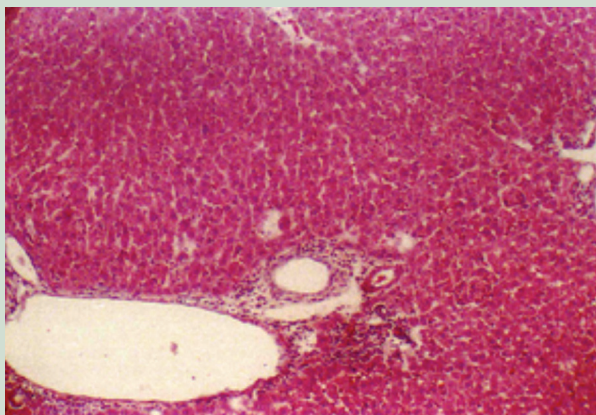


Figure 2. Portal inflammation and piecemeal necrosis in rat liver.

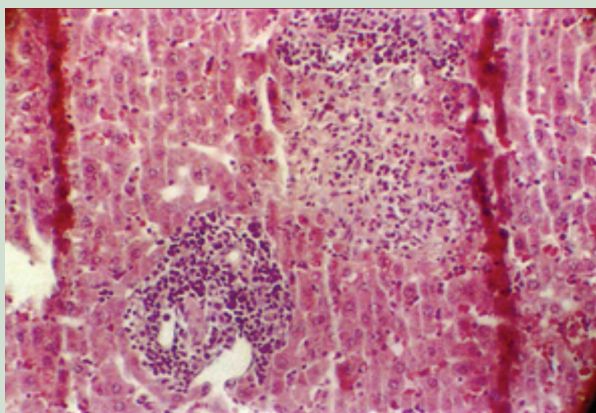


Figure 3. Granuloma and portal inflammation in rat liver.

Hydrochlorofluorocarbons (HCFC) are found in some thinners. In an experimental study conducted by Frame *et al.*, male rats were grouped and exposed to HCFC – 225 cb in concentrations of 500, 1000 and 13000 ppm (6 hours per day for 2 weeks). Pathologic evaluation revealed hepatocellular hypertrophy in all groups. Hypertrophy was diffuse, and these hepatocytes showed granular, eosino-

philic cytoplasmic swelling and had enlarged, hyperchromic nuclei. As the dose increased, the hypertrophy in hepatic cells became more prominent, and the liver was much heavier. The peroxisome number had increased in the livers of all exposed groups. At the 14th day of the termination of the experiment, hepatic changes had all resolved in rats dissected at the time (20).

According to a study published in Norway, the main form of exposure to toluene is via inhalation. Toluene is mostly metabolized in the liver and is excreted as hippuric acid in the urine. It is catabolized mainly by oxidation. This pathway takes place in the endoplasmic reticulum of the hepatic parenchymal cells, over the cytochrome P-450 system (21).

In exposure through inhalation, a dose-dependent, reversible weight increase in the liver has been reported. There is no increase in the liver enzymes except for alkaline phosphatase.

Acute unintentional inhalation of paint thinner fumes resulted in serious multi-organ toxicity and death (11).

In our study, we evaluated the histopathological changes in the liver of rats exposed to thinner inhalation for certain periods and dissected at 1, 3 and 5 weeks. The results were compared with the rats in the control group, which were not exposed to thinner and were sacrificed at the end of 5 weeks. Many studies can be found with the same experimental setting, investigating exposure to controlled thinner inhalation in rats by dissection. However, most of these studies were focused on the effect of controlled thinner inhalation upon the central nervous system and were mostly directed by neurologists.

The livers of the experimental animals were evaluated histopathologically for parenchymal damage (focal necrosis, hydropic degeneration), granuloma, piecemeal necrosis (periportal necrosis), portal inflammation, and bile duct damage, and the results were analyzed statistically. There was a statistically significant difference regarding focal necrosis between Groups 2 and 3. Group 3 rats were in the worst condition. Similarly, a statistically significant difference was found regarding granuloma, piecemeal necrosis, and periportal inflammation between Groups 2 and 3. A statistically significant difference was also found regarding portal inflammation between Groups 2 and 3. There was no statistically significant difference regarding hydropic degeneration.

In summary, it has been proven that thinner inhalation causes detectable damage in the liver of experimental animals, in parallel to the experimental results and reported cases. These findings are in accordance with the term “toxic hepatitis”.

Toxic hepatitis is a serious problem during drug development and in the use of many established drugs. For example, acetaminophen overdose is currently the most frequent cause of acute liver failure in the United States and Great Britain. Evaluation of the mechanisms of drug-induced liver injury indicates that mitochondria are critical targets for drug toxicity, either directly or indirectly through the formation of reactive metabolites. Together, these events trigger necrotic cell death (22).

As the inhalation period extends, the damage becomes more prominent. Nevertheless, the fact that the lesions were also seen in the control group as well (though to a minimum extent) is a little confusing. A possible explanation is that infection with a probable agent found in the same environment was passed to the other animals.

It is obvious from the results of our study and many others that the use of thinner as a narcotic is quite harmful and causes histopathologically detectable liver damage, which becomes more prominent as the exposure period is prolonged. In order to better establish the real damage to the liver caused by thinner, there is a need for more

clinical and experimental studies performed in more sterilized settings for longer periods.

In countries with low socioeconomic conditions, thinner is the drug of abuse for many young people, owing to the high cost, inaccessibility and illegality of other drugs. It is widely used in industry, and people are exposed to thinner through inhalation, skin contact or oral intake. This solvent is mainly composed of toluene, which is responsible for the damage to the central nervous system, respiratory tract and hepatobiliary system when inhaled.

In our study, we observed the development of focal necrosis, granuloma, piecemeal necrosis, and portal inflammation in the liver, and these lesions became more remarkable as the exposure time extended. There was no significant difference between groups regarding bile duct damage.

In order to prevent the use of thinner as a narcotic, society should be informed about its harmful effects and more effective banning measures should be taken. For those who are occupationally exposed to thinner, preventive measures should be taken in the workplace.

REFERENCES

1. Flanagan RJ, Ruprah M, Meredith TJ, Ramsey JD. An introduction to the clinical toxicology of volatile substances. *Drug Saf* 1990; 5: 359-83.
2. Vural N. Toksikoloji. 2. baskı. Ankara: Ankara Üniversitesi Basımevi, 1996; 453-80.
3. Bayrakçı B, Şahin M, Özen M, Ünal Ş. Thinner ingestion causes hyperthermia. *Türkiye Klinikleri J Med Sci* 2009; 29: 416-9.
4. Tiner-Selülozik. Türk Standartları Enstitüsü. TS 9720/Ocak 1992.
5. Ramsey J, Anderson R, Bloor K, Flanagan RJ. An introduction to the practice, prevalence and chemical toxicology of volatile substance abuse. *Human Toxicol* 1989; 8: 261-9.
6. Debasish B, Om PJ, Jaspreet S, Suresh K, Surendra KM. Inhalant abuse by adolescents: a new challenge for Indian physicians. *Indian J Med Sci* 2004; 58: 245-9.
7. Meadows R, Verghese A. Medical complications of glue sniffing. *South Med J* 1996; 89: 455-62.
8. Ulakoğlu EZ, Saygı A, Gümüştaş MK, et al. Alterations in superoxide dismutase activities, lipid peroxidation and glutathione levels in thinner inhaled rat lungs: relationship between histopathologic properties. *Pharmacol Res* 1998; 38: 209-14.
9. Akinobu T, Hideyuki S, Yoshiaki I, et al. A 27-year-old man who died of acute liver failure probably due to trichloroethylene abuse. *J Gastroenterol* 2008; 43: 239-42.
10. Vural M, Ogel K. Dilated cardiomyopathy associated with toluene abuse. *Cardiology* 2006; 105: 158-61.
11. Zaidi SA, Shaw AN, Patel MN, et al. Multi-organ toxicity and death following acute unintentional inhalation of paint thinner fumes. *Clin Toxicol* 2007; 45: 287-9.
12. Cobanoglu B, Ozercan IH, Ozercan MR, Yalcin O. The effect of inhaling thinner and/or cigarette smoke on rat kidneys. *Inhal Toxicol* 2007; 19: 303-8.
13. Mazlum C, Ahmet T, Meral E. Substance abuse, conduct disorder and crime: assessment in a juvenile detention house in Istanbul, Turkey. *Psychiatry Clin Neurosci* 2005; 59: 151-4.
14. Bolukbasi S, Habesoglu TE, Habesoglu M, et al. Histopathological changes of rat larynx mucosa with exposure to chronic thinner inhalation. *Otolaryngol Head Neck Surg* 2009; 141: 75-80.
15. Ishak K, Baptista A, Bianchi L, et al. Histological grading and staging of chronic hepatitis. *J Hepatol* 1995; 22: 696-9.
16. Martin KA. Toluene toxicity. Toledo (Ohio): Department of Emergency, The Toledo Hospital, e Medicine Specialties; 2001: 1-13.
17. Yamada K. Influence of lacquer thinner and some organic solvents on reproductive and accessory organs in male rat. *Biol Pharm Bull* 1993; 16: 425-7.
18. Estrada JG, Segura AR, Garzon P. Cerebral cortex and body growth development of progeny of rats exposed to thinner and turpentine inhalation. *Gen Pharmac* 1988; 19: 467-70.
19. Carabez A, Sandoval F, Palma L. Ultrastructural changes of tissues produced by inhalation of thinner in rats. *Microsc Res Tech* 1998; 40: 56-62.
20. Frame SR, Carakostas MC, Warheit DB. Inhalation toxicity of an isomeric mixture of hydrochlorofluorocarbon (HCFC) in male rats. *Fund App Toxicol* 1992; 18: 590-5.
21. Ostergaard G. 125 Toluene. The Nordic expert group for criteria documentation of health risks from chemicals 2000; 19: 1-33.
22. Jaeschke H, McGill MR, Ramachandran A. Oxidant stress, mitochondria, and cell death mechanisms in drug-induced liver injury: lessons learned from acetaminophen hepatotoxicity. *Drug Metab Rev* 2012; 44: 88-106. Epub 2012 Jan 10.