

Has the role of diagnostic laparoscopy in a single gastroenterology unit changed over 20 years?

Gastroenterolojide yirmi yılda tanısal laparoskopinin rolü değişti mi?

Fatih ERMIŞ¹, Ahmet UYANIKOĞLU², Filiz AKYÜZ³, Kadir DEMİR³, Fatih BEŞİŞİK³, Sabahattin KAYMAKOĞLU³

Department of ¹Internal Medicine, Division of Gastroenterology, Düzce University School of Medicine, Düzce

Department of ²Internal Medicine, Division of Gastroenterology, Harran University School of Medicine, Şanlıurfa

Department of ³Gastroenterology, Istanbul University School of Medicine, İstanbul

Background and Aims: The use of diagnostic laparoscopy seems to have markedly reduced since the advent of major developments in noninvasive imaging modalities. We aimed to investigate the role of diagnostic laparoscopy in our gastroenterology unit. **Materials and Methods:** Reports of 1484 laparoscopy patients seen in the Gastroenterology Department of Istanbul University, Istanbul Faculty of Medicine between 1989 and 2010 were evaluated retrospectively. Laparoscopy was performed using the Storz laparoscope under local anesthesia. **Results:** Patients with ascites were evaluated in two different groups according to serum-ascites albumin gradient values as >1.1 g/dL and <1.1 g/dL. Diagnoses of 93 (6,3%) patients were revised after the laparoscopic examination. Although diagnostic laparoscopy for evaluation of exudative ascites and peritoneal disease has decreased in the last quarter, the decrease was relatively less when compared with that for transudative ascites. **Conclusions:** Diagnostic laparoscopy is still the preferred method both for the diagnosis of peritoneal tuberculosis and to rule out other diseases such as malignancy.

Key words: Diagnostic laparoscopy, gastroenterology, tuberculosis, exudative ascites, malignancy

Giriş ve Amaç: Girişimsel olmayan görüntüleme metotlarındaki gelişmeler sonrasında tanısal laparoskopinin kullanımı azalmıştır. Biz de gastroenteroloji ünitemizde tanısal laparoskopi olgularını inceledik. **Gereç ve Yöntem:** 1989-2010 yılları arasında İstanbul Tıp Fakültesi Gastroenteroloji Bilim Dalı'nda laparoskopik işleme giren 1484 hastanın raporları retrospektif olarak değerlendirildi. Laparoskopi işlemi lokal anestezi altında Storz marka laparoskopi cihazı ile yapıldı. **Bulgular:** Asitli hastalar serum-asit albumin farklarına göre $> 1,1$ g/dL ve $< 1,1$ g/dL olacak şekilde iki gruba ayrılarak incelendi. Toplamda 93 (%6,3) hastanın tanısı laparoskopik inceleme sonrası değişti. Son beş yılda eksuda asit ve peritoneal hastalık için yapılan tanısal laparoskopi sayısı azalmış olsa da bu azalma transuda asitlerle karşılaştırıldığında azalma oranının daha düşük olduğu görülmektedir. **Sonuç:** Tanısal laparoskopinin halen peritoneal tüberküloz tanısını koymada ve diğer malign hastalıkların ayırıcı tanısında tercih edilen bir yöntemdir.

Anahtar kelimeler: Tanısal laparoskopi, gastroenteroloji, tüberküloz, eksuda asit, malignite

INTRODUCTION

Diagnostic laparoscopy has been in use in gastroenterology units since the early 20th century. The use of diagnostic laparoscopy seems to have markedly reduced with the advent of major developments in noninvasive imaging modalities like ultrasonography, computed tomography and magnetic resonance imaging. Although the efficacy and safety of diagnostic laparoscopy have been well established, it is still an invasive procedure (1,2). Since the first laparoscopic cholecystectomy was carried out in the mid-1980s (3,4), surgeons and gynecologists have evalu-

ated and standardized laparoscopic techniques in a wide range of indications in the operating room (5). To date, surgical procedures have mainly focused on therapeutic applications, whereas in internal medicine, laparoscopy has been primarily regarded as a diagnostic tool. Now, a decreasing number of gastroenterologists practice diagnostic laparoscopic examinations. Few reports have been written in the last decade about the usefulness of diagnostic laparoscopy in gastroenterology. Therefore, we reviewed our diagnostic laparoscopy cases in the last

Address for correspondence: Fatih ERMIŞ

Department of Internal Medicine, Division of Gastroenterology, Düzce Medical Faculty, Düzce University, Düzce, Turkey • Phone: +90 380 514 88 30
Fax: +90 380 542 13 02 • E-mail: fatihermis2@hotmail.com

Geliş Tarihi: 04.01.2013 • **Kabul Tarihi:** 22.04.2013

20 years and tried to establish the role of this procedure in a single gastroenterology unit in the era of advanced imaging techniques.

MATERIALS AND METHODS

We retrospectively evaluated reports of 1484 laparoscopy patients seen in the Gastroenterology Department of Istanbul University, Istanbul Faculty of Medicine between 1989 and 2010. After the clinical symptoms and signs were noted, biochemical tests were performed on samples of serum and ascitic fluid. The serum/ascites albumin gradient (SAAG) was calculated. Laparoscopy was performed using the Storz laparoscope under local anesthesia. Room air was used as an insufflating gas after sterilization by filtration.

RESULTS

Nine hundred and fourteen patients (61,6%) were male, and the mean age was 45.4±15.1 (range, 16-83) years. Laparoscopy was successfully completed in 1480 patients; in 4 (0,003%) patients, it could not be completed

due to severe peritoneal adhesions. There was no mortality related with the procedure. Complications were noted in only 4 patients (0,003%), as biopsy site bleeding (n: 2), intestinal perforation (n: 1), and splenic injury (n: 1).

Eighty-six patients had no ascites during the physical examination and/or ultrasonographic examination. These included 35 precirrhotic, 25 cirrhotic, 9 hemangioma, 6 metastatic liver tumor, 7 hepatocellular carcinoma (HCC), 2 peritoneal tuberculosis, 1 peritoneal carcinomatosa, and 1 lymphoma cases. A total of 1394 patients with ascites were evaluated in two different groups according to SAAG values as >1.1 g/dL and <1.1 g/dL. Detailed information is given in Table 1.

Diagnoses of 93 (6,3%) patients were revised after the laparoscopic examination. In patients with chronic liver disease with suspicion of cirrhosis, the diagnosis in 62 patients was changed from precirrhotic chronic liver disease to cirrhosis after laparoscopic examination. In 31 patients with ascites of unknown origin and peritoneal disease, the initial diagnosis was changed or a less probable diagnosis was confirmed after laparoscopic examination (Table 2).

Table 1. Distribution of diagnoses according to SAAG after laparoscopy

Portal hypertensive ascites (n=1089)	Non-portal hypertensive (exudative) ascites (n=305)
*Cirrhosis 884	*Peritoneal tuberculosis 152
*Precirrhotic chronic liver disease 136	*Peritonitis carcinomatosa 94
*Metastatic liver disease 37	*HCC 33
*HCC 15	*Cirrhosis 9
*Budd–Chiari syndrome 9	*Cirrhosis and peritoneal tuberculosis 6
*Peritoneal tuberculosis 6	*Precirrhotic chronic liver disease 5
*Peritonitis carcinomatosa 2	*Mesothelioma 3
	*Metastatic liver disease 2
	*Peritonitis carcinomatosa and peritoneal tuberculosis 1

SAAG: Serum / ascites albumin gradient, HCC: Hepatocellular carcinoma

Table 2. Changes in diagnosis after laparoscopic examination

Initial diagnosis	Final diagnosis	n
Precirrhotic chronic liver disease	Cirrhosis	62
Peritoneal tuberculosis	Peritonitis carcinomatosa	10
Cirrhosis	Peritoneal tuberculosis	6
Peritonitis carcinomatosa	Peritoneal tuberculosis	5
Metastatic liver tumor	Hemangioma	3
Cirrhosis	Peritonitis carcinomatosa	2
Peritonitis carcinomatosa	Mesothelioma	2
Peritoneal tuberculosis	Mesothelioma	1
Cirrhosis	Cirrhosis and peritoneal tuberculosis	1
Cirrhosis and peritoneal tuberculosis	Peritonitis carcinomatosa	1

DISCUSSION

The use of diagnostic laparoscopy has reduced distinctly today since many gastroenterologists prefer less invasive procedures, such as the modern imaging modalities. In our institution, over 100 diagnostic laparoscopic examinations were performed each year during the first five-year period (1989-1993), but the number of diagnostic laparoscopy examinations has decreased to 10 per year in the last eight-year period (2003-2010). Diagnostic laparoscopy was performed for the differential diagnosis in patients with ascites and thrombocytopenia ($100.000/\text{mm}^3$) in the first years. However, in recent years, since the platelet count for a safe liver biopsy was adopted as $>50.000/\text{mm}^3$ and the transjugular biopsy route was used, diagnostic laparoscopy was performed usually for exudative ascites.

The use of diagnostic laparoscopy for the evaluation of exudative ascites and peritoneal disease decreased in the last quarter; however, the decrease was relatively less when compared with that for transudative ascites (Figure 1). This may be due to the relatively constant number of cases with peritoneal tuberculosis. Tuberculosis continues to be an endemic disease in Turkey. Tuberculosis can involve any part of the gastrointestinal tract, which is the sixth most frequent site of extrapulmonary involvement (6). In most cases of extrapulmonary tuberculosis, the samples are paucibacillary (7). Acid-fast bacillus staining of ascites fluid is positive in only 3% of peritoneal tuberculosis patients, and the sensitivity of polymerase chain reaction (PCR) decreases to 40% in smear-negative specimens. Laparoscopy remains the most reliable, safest and quickest method for the diagnosis of peritoneal tuberculosis, especially when the adenosine deaminase

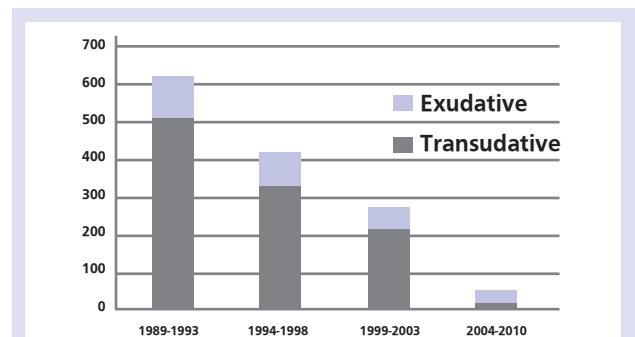


Figure 1. Number of laparoscopies performed by years with respect to SAAG

SAAG: Serum / ascites albumin gradient

(ADA) test is not available. Especially in cirrhotic patients with low protein ascites, false-negative results for ADA are quite common as well. Therefore, diagnostic laparoscopy with peritoneal biopsy for histopathological examination is the preferred method both for the diagnosis of peritoneal tuberculosis and to rule out other diseases such as malignancy (8-10).

In conclusion, laparoscopy still appears to yield information in selected patients who have a disease that can pose significant diagnostic and treatment dilemmas. However, caution and common sense must be exercised during the procedure, as any careless maneuver can lead to a catastrophic consequence, especially in a cirrhotic patient.

Acknowledgement: The authors have no financial disclosures to declare and no conflicts of interest to report.

REFERENCES

- Herrera JL, Brewer TG, Peura DH. Diagnostic laparoscopy: a prospective review of 100 cases. *Am J Gastroenterol* 1989; 84: 1051-4.
- Yoon YJ, Ahn SH, Park JY, et al. What is the role of diagnostic laparoscopy in a gastroenterology unit? *J Gastroenterol* 2007; 42: 881-6.
- Mühe E. Die erste cholecystektomie durch das laparoskop. *Lagenbecks Arch Klin Chir* 1986; 396: 804.
- Schneider AR, Eickhoff A, Arnold JC, Riemann JF. Diagnostic laparoscopy. *Endoscopy* 2001; 33: 55-9.
- Boyd WP Jr, Nord HJ. Diagnostic laparoscopy. *Endoscopy* 2000; 32: 153-8.
- Apaydin B, Paksoy M, Bilir M, Zengin K, Saribeyoglu K, Taskin M. Value of diagnostic laparoscopy in tuberculous peritonitis. *Eur J Surg* 1999; 165: 158-63.
- Brodie D, Schluger NW. The diagnosis of tuberculosis. *Clin Chest Med* 2005; 26: 247-71.
- Sanai FM, Bzeizi KI. Systemic review: tuberculous peritonitis-presenting features, diagnostic strategies and treatment. *Aliment Pharmacol Ther* 2005; 22: 685-700.
- Rao YG, Pande GK, Sahni P, Chattopadhyay TK. Gastrointestinal tuberculosis management guidelines, based on a large experience and a review of the literature. *Can J Surg* 2004; 47: 364-8.
- Demir K, Okten A, Kaymakoglu S, et al. Tuberculous peritonitis-reports of 26 cases, detailing diagnostic and therapeutic problems. *Eur J Gastroenterol Hepatol* 2001; 13: 581-5.