

Extrahepatic manifestations of chronic viral hepatitis: possible associated complications must not be forgotten in daily clinical practice

Kronik viral hepatitlerde ekstrahepatik bulgular: Günlük klinik pratikte unutulmaması gereken bir nokta

Fatih ERMIŞ¹, Ahmet UYANIKOĞLU², Filiz AKYÜZ³, Kadir DEMİR³, Sabahattin KAYMAKOĞLU³

Department of ¹Internal Medicine, Division of Gastroenterology, Düzce University School of Medicine, Düzce

Department of ²Internal Medicine, Division of Gastroenterology, Harran University School of Medicine, Şanlıurfa

Department of ³Gastroenterology, Istanbul University School of Medicine, Istanbul

Background and Aims: Hepatitis viruses induce not only chronic liver diseases but also the impairment of other organs and tissues as extrahepatic manifestations. It is necessary to consider possible complications associated with extrahepatic diseases in the treatment. **Materials and Methods:** We retrospectively evaluated the demographic features of 52 (2%) patients who had clinically symptomatic extrahepatic manifestations from among 2870 chronic viral hepatitis patients in the Gastroenterology Department of the Istanbul Medical Faculty between 1997 and 2010. **Results:** Twenty-seven of the 52 patients (52%) had hepatitis C, 24 (46%) hepatitis B, and 1 (2%) both hepatitis B and C. Of these, 25 (48%) were males, and the mean age was 51±13 (range, 18 to 78) years. Thirty-two patients (61%) were cirrhotic, while 20 (39%) were in the precirrhotic stage. **Conclusions:** Extrahepatic involvement is generally overlooked, and clinicians should be more sensitive to the diagnoses of these manifestations.

Giriş ve Amaç: Hepatit etkeni virüsler kronik karaciğer hastalıklarına yol açmanın yanısıra ekstrahepatik bulgular olarak adlandırılan diğer organ ve dokularda da bozukluklara neden olabilirler. Tedavide ekstrahepatik tutulumları da gözardı etmemek gereklidir. **Gereç ve Yöntem:** İstanbul Tıp Fakültesi Gastroenteroloji Bilim Dalı'nda 1997-2010 yılları arasında takipli toplam 2870 hastada klinik olarak semptomatik ekstrahepatik tutulumu olan 52 hastanın (%2) demografik özellikleri retrospektif olarak değerlendirildi. **Bulgular:** Elli iki hastadan 27'si (%52) hepatit C, 24'ü (%46) hepatit B ve 1 (%2) hasta da hem hepatit B hem de hepatit C idi. Bunlardan 25'i (%48) erkekti, ortalama yaş 51±13 (18-78) yıldı. Otuz iki hasta (%61) sirotik evrede, 20 hasta (%39) ise presirotik evrede idi. **Sonuç:** Ekstrahepatik tutulumlar genellikle atlanmaktadır. Klinisyenler ekstrahepatik bulguların tanısında daha duyarlı olmalıdırlar.

Keywords: Chronic hepatitis, extrahepatic manifestations

Anahtar kelimeler: Kronik hepatit, ekstrahepatik bulgular

INTRODUCTION

Hepatitis viruses induce not only chronic liver diseases but also the impairment of other organs and tissues as extrahepatic manifestations. The consideration of possible complications associated with extrahepatic diseases is of vital importance in the treatment. Numerous extrahepatic manifestations have been reported in patients with both acute and chronic forms of viral hepatitis (1). Pascual et al. (2) first suggested an association between viral hepatitis and extrahepatic syndromes in 1990, when they described two patients with hepatitis C virus (HCV) infection and mixed cryoglobulinemia.

MATERIALS AND METHODS

We retrospectively evaluated the demographic features of 52 (2%) patients who had clinically symptomatic extrahepatic manifestations from among 2870 chronic viral hepatitis patients in the Gastroenterology Department of the Istanbul Medical Faculty between 1997 and 2010.

RESULTS

Twenty-seven of the 52 patients (52%) had hepatitis C, 24 (46%) hepatitis B, and 1 (2%) both hepatitis B and C.

Address for correspondence: Fatih ERMIŞ

Department of Internal Medicine, Division of Gastroenterology, Düzce

Medical Faculty, Düzce University, Düzce, Turkey

Phone: + 90 380 514 88 30 • Fax: + 90 380 542 13 02

Geliş Tarihi: 29.08.2012 • **Kabul Tarihi:** 10.09.2012

Of these, 25 (48%) were males, and the mean age was 51 ± 13 (range, 18 to 78) years. Thirty-two patients were cirrhotic, while 20 were in the precirrhotic stage.

Mixed cryoglobulinemia was shown in 14 hepatitis C patients and in only 2 hepatitis B patients. Renal involvement was observed in 11 hepatitis B patients: renal biopsy was consistent with membranous glomerulonephritis in 7 and membranoproliferative glomerulonephritis in 4 of them. Membranoproliferative glomerulonephritis was also shown in 3 hepatitis C patients. Hypothyroidism due to Hashimoto's thyroiditis was shown in 3 patients (1 HBV, 2 HCV). Dermatological involvement was shown in 6 patients (1 HBV, 5 HCV): lichen planus was seen in 4, erythema nodosum in 1 and leukocytoclastic vasculitis in 1. Polyarteritis nodosa was observed in 1 hepatitis B patient. Hematologic disorders were shown in a total of 7 patients: 3 of them were hemolytic anemia, 2 immunothrombocytopenia, 1 Waldenström's macroglobulinemia, and 1 antiphospholipid syndrome (4 HBV, 3 HCV). With respect to the site of malignancies, non-Hodgkin's lymphoma was shown in 3, thymoma in 3, primary hepatic B cell lymphoma in 1, and Kaposi's sarcoma in 1 (5 HBV, 3 HCV). Four patients (8%) had more than one extrahepatic manifestation. Extrahepatic manifestations in both types of hepatitis are shown as percentage in Figure 1.

DISCUSSION

No clear-cut predictors for the development of extrahepatic manifestations in viral hepatitis have been identified, but suggested factors are long-term infection and advanced liver disease as cirrhosis (3). Thirty-two of the 52 patients (61%) who had extrahepatic manifestations were in the cirrhotic stage. As reported by Kayali et al. (4), we also report a high prevalence of cirrhosis in patients with extrahepatic manifestations.

Although extrahepatic manifestations do exist with all hepatitis viruses, they are more commonly associated with chronic HCV infection. Fewer reports are available in HBV infection (5, 6). However, in our study, extrahepatic manifestations were nearly equal in both groups, except for mixed cryoglobulinemia. This could be related to the high incidence of hepatitis B in our population, as approximately 60% of the study patients had hepatitis B. Although the hepatitis B vaccination program begins early in newborns, hepatitis B is still the most common hepatitis agent in Turkey.

The extrahepatic manifestation rate was lower in the present group than in previous studies in the literature (7). This difference could originate from the fact that we only considered the clinically symptomatic extrahepatic manifestations and not all the biological extrahepatic

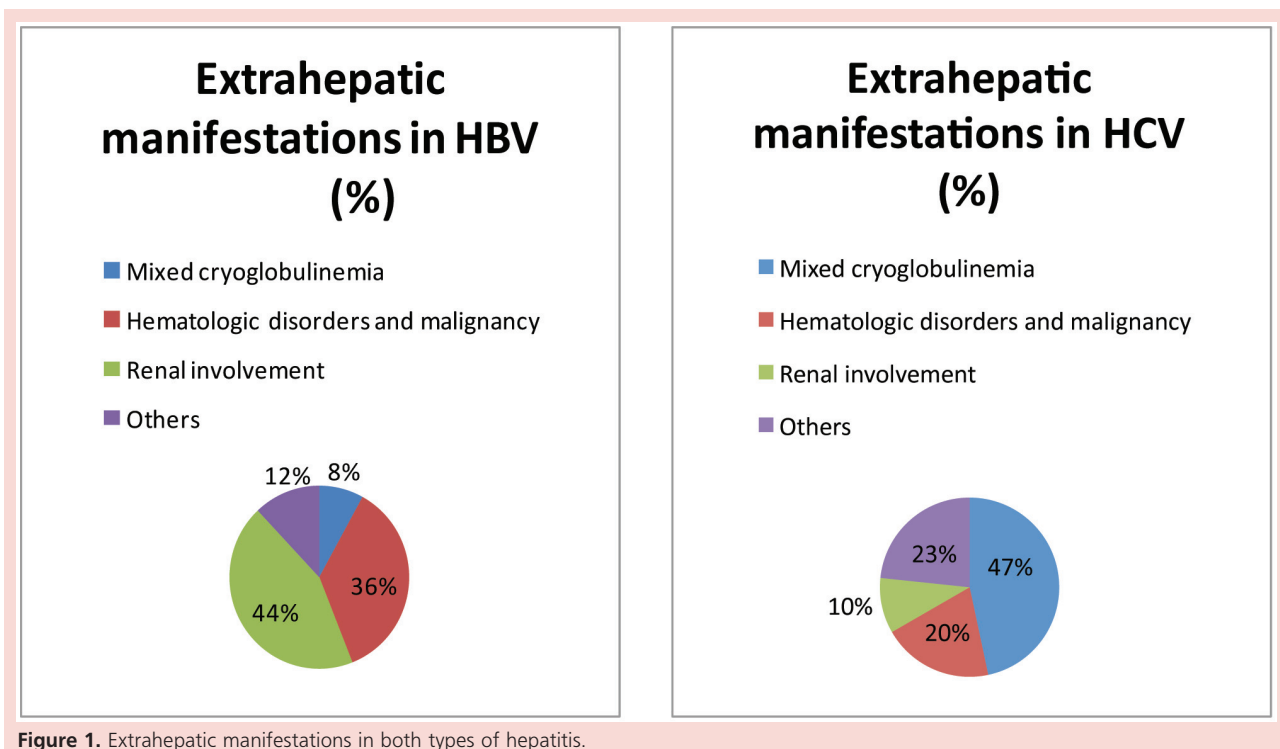


Figure 1. Extrahepatic manifestations in both types of hepatitis.

manifestations like immunologic abnormalities. For example, mixed cryoglobulinemia can be detected in up to half of the patients with HCV infection, but in 90% of cases it causes no symptoms and requires no specific treatment (3); only 2–3% suffer symptoms of cryoglobulinemia including arthralgia, weakness, purpura, arterial hypertension, renal impairment, peripheral neuropathy, and systemic vasculitis (5).

Mixed cryoglobulinemia was the most frequent extrahepatic manifestation in our study group, followed by renal and dermatological involvement. Mixed cryoglobulinemia and dermatological involvement were seen more com-

monly in hepatitis C, whereas membranous glomerulonephritis was encountered more frequently in patients with hepatitis B. Extrahepatic lesions undoubtedly increase the percentage of detriment to health. It is necessary to consider possible complications associated with extrahepatic diseases in the treatment of patients infected with viral hepatitis. Extrahepatic involvement is generally overlooked, and clinicians should be more sensitive to the diagnoses of these manifestations.

Acknowledgement: *The authors have no financial disclosures to declare and no conflicts of interest to report.*

REFERENCES

1. Trepo C, Guillemin L. Polyarteritis nodosa and extrahepatic manifestations of HBV infection: the case against autoimmune intervention in pathogenesis. *J Autoimmun* 2001;16:269-74.
2. Pascual M, Perrin L, Giostra E, et al. Hepatitis C virus in patients with cryoglobulinemia type II [letter]. *J Infect Dis* 1990;162:569-70.
3. Ali A, Zein NN. Hepatitis C infection: a systemic disease with extrahepatic manifestations. *Cleve Clin J Med* 2005;72:1005-19.
4. Kayali Z, Buckwold VE, Zimmerman B, et al. Hepatitis C, cryoglobulinemia, and cirrhosis: a meta-analysis. *Hepatology* 2002;36:978-85.
5. Cacoub P, Poynard T, Ghillani P, et al. Extrahepatic manifestations of chronic hepatitis C. MULTIVIRC Group. Multidepartment Virus C. *Arthritis Rheum* 1999;42:2204-12.
6. Agnello V, De Rosa FG. Extrahepatic disease manifestations of HCV infection: some current issues. *J Hepatol* 2004;40:341-52.
7. Cacoub P, Saadoun D, Bourlière M, et al. Hepatitis B virus genotypes and extrahepatic manifestations. *J Hepatol* 2005;43:764-70.