

## Irbesartan-induced autoimmune hepatitis

Irbesartan'ın indüklediği otoimmün hepatit

Sezgin VATANSEVER, Mahmut ARABUL, Mustafa ÇELİK, Fatih CANTÜRK, Altay KANDEMİR, Emrah ALPER, Belkis ÜNSAL

Department of Gastroenterology, Atatürk Training and Research Hospital, Izmir

Several cases of angiotensin II antagonist-induced hepatotoxicity have been reported in the literature. A class warning for hepatotoxicity for these compounds should probably be considered. We report a patient who developed autoimmune-type hepatitis, whose liver function tests showed hepatocellular-type liver injury shortly after starting therapy with irbesartan, one of the angiotensin II antagonists. Serological and biochemical studies and ultrasonography ruled out viral hepatitis, metabolic diseases and extrahepatic biliary obstruction, respectively. Serologic tests for anti-nuclear antibodies were positive. In percutaneous liver biopsy, pathologic signs showed especially acute hepatitis with centrilobular necrosis in the perivenular area and also marked cholestatic features. Irbesartan was withdrawn, and the patient's jaundice resolved slowly over a period of several weeks but recurred two months later. Steroid therapy was started, resulting in progressive improvement in symptoms and laboratory data. In this patient, steroid therapy was continued up to one year. Upon cessation of steroid therapy, there was recurrence eight months later, and steroid therapy was restarted.

Literatürde anjiyotensin II reseptör blokerlerinin indüklediği hepatotoksisite ile ilgili birkaç vaka rapor edilmiştir. Bu bileşikler için hepatotoksisite açısından, A sınıfı uyarı muhtemelen düşünülmelidir. Biz bir anjiyotensin-II reseptör blokörü olan irbesartan başlandıktan kısa süre sonra hepatoselüler tipte hasar gelişip, karaciğer fonksiyon testleri bozulan otoimmün hepatit vakasını rapor ettik. Serolojik, biyokimyasal ve ultrasonografi ile viral hepatit, metabolik hastalıklar ve ekstrahepatik biliyer hastalıklar dışlandı. Serolojik testlerden ANA (+) idi. Karaciğer biyopsisinde, perivenüler alanda ve özellikle kolestatik tipte akut hepatiti düşündüren sentrilobüler nekroz izlendi. Irbesartan kesildikten sonra birkaç hafta içerisinde sarılık geriledi fakat 2 ay sonra rekürrens oldu. Steroid tedavi 1 mg/kg/günden (60 mg prednisolon) başlandı. Steroid başlandıktan kısa bir süre sonra klinik ve laboratuvar iyileşme izlendi. 4 hafta içerisinde 8 mg'a azaltıldı. Hastada ilacın indüklediği otoimmün hepatit düşünüldüğünden biyopsi yapılmaksızın steroid tedavisi 1 yıl sonra kesildi.

**Key words:** Irbesartan, autoimmune hepatitis

**Anahtar kelimeler:** Irbesartan, otoimmün hepatitis

### INTRODUCTION

Irbesartan, a-benzylimidazole-5-acetic acid derivative, is one of the new, recently marketed, orally active angiotensin II antagonists (AT<sub>1</sub>RA) indicated for control of essential hypertension and heart failure (1,2). This class of drugs interrupts the renin-angiotensin system via selective blockade of the angiotensin II subtype 1 receptor, which is responsible for the pressure-related effects of angiotensin (1,2). In comparative trials, irbesartan has been tolerated well, exhibiting an adverse-event profile similar to that seen with placebo (2). Several cases of cholestatic jaundice and one case of autoimmune cholestatic jaundice with a protracted course associated with irbesartan have been reported in the literature (3-5).

### CASE REPORT

A 65-year-old woman was admitted to our hospital with progressive jaundice, fatigue, and malaise. She had ne-

ver experienced similar symptoms or signs previously. Two months before, she had been prescribed irbesartan (300 mg/day) for essential hypertension. She reported drinking no alcohol, and denied the use of any other drugs or herbal medicine, or of having drug allergies. Her examination was remarkable only for the presence of marked jaundice of the sclera and skin. Laboratory results were as follows: aspartate aminotransferase (AST) 927 U/L (normal <37 U/L); alanine aminotransferase (ALT) 1200 U/L (normal <40 U/L); alkaline phosphatase (ALP) 161 U/L (normal: 40-150 U/L); gamma-glutamyl transferase (GGT) 105 U/L (normal: 9-36 U/L); total bilirubin 4.2 mg/dl (direct bilirubin 17.8 mg/dl); and globulin 4.2 g/dl (normal: 1.2-3.1 g/dl). Serum immune globulin G level was slightly elevated (1.1-fold increased). Serum albumin, transferrin saturation and ceruloplasmin level, mean corpuscular volume, prothrombin time, and leukocyte, eosinophil and platelet counts were all within

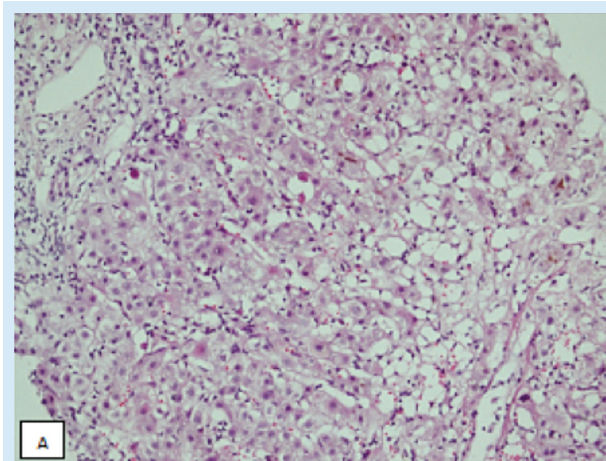
**Address for correspondence:** Mahmut ARABUL  
Izmir Atatürk Training and Research Hospital,  
Department of Gastroenterology, Izmir, Turkey  
Phone: +90 232 244 44 44 • E-mail: mahmutarabul@gmail.com

**Manuscript received:** 01.12.2011 • **Accepted:** 29.12.2011

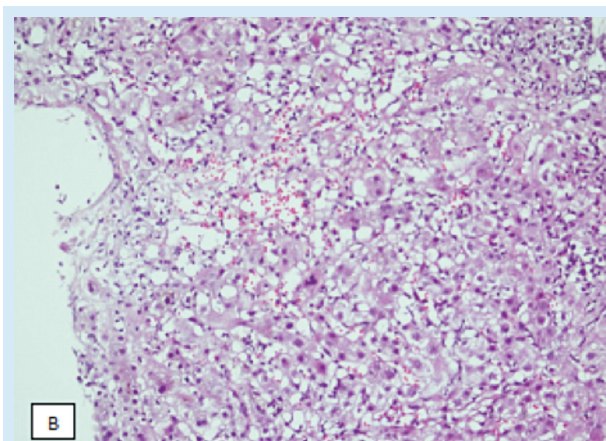
normal ranges. Results of tests for known viral hepatitis markers, including HAV IgM, anti-HBc IgM-IgG, HBsAg, anti-HCV, and HBV-DNA and HCV-RNA by polymerase chain reaction (PCR), Epstein-Barr virus, and cytomegalovirus were negative. Antinuclear antibodies (ANA, 1/1000) were positive. The other autoimmune hepatitis markers including anti-smooth muscle and anti-liver-kidney microsomal antibodies were negative. Abdominal ultrasonography was normal. Irbesartan therapy was immediately discontinued. Liver biopsy performed for suspicion of drug-induced autoimmune hepatitis showed acute cholestatic hepatitis with centrilobular hepatocellular necrosis, which was not typical for autoimmune hepatitis (Figures A, B, C). Serum transaminases and bilirubin decreased and symptoms improved progressively after cessation of the irbesartan therapy. The patient was discharged on the 15th day of hospitalization without any treatment. She readmitted to our hospital for jaundice two months later. Liver function test results were similar to the first admission. We applied the 'revised scoring system for the diagnosis of autoimmune hepatitis' proposed by the International Autoimmune Hepatitis Group Report on patient characteristics, and our patient's score was consistent with probable autoimmune hepatitis. Prednisolone, 1 mg/kg (60 mg/day), was then started, resulting in progressive improvement in jaundice and laboratory data. Steroid was reduced to 8 mg after four weeks. In this patient, steroid therapy was continued up to one year. Upon cessation of steroid therapy, there was recurrence eight months later. Steroid therapy was interrupted at the end of the year because we considered drug-induced autoimmune hepatitis.

## DISCUSSION

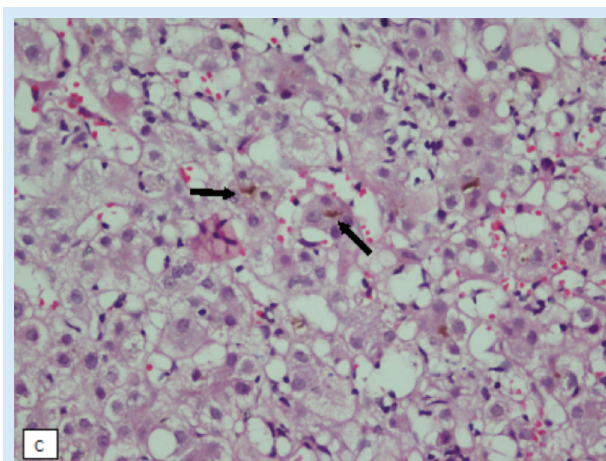
The temporal relationship between the administration of irbesartan and the onset of the liver abnormalities, predominance of cholestasis with patchy hepatocellular necrosis in the perivenular (central-lobular) region, as well as the elimination of alternative explanations strongly supported the diagnosis of drug-induced liver injury implicating irbesartan in this case of hepatocellular-type hepatitis (6). Causality assessment by the Council for International Organization of Medical Science yielded a score of 10 points for irbesartan (7,8). There was no history of drug use other than irbesartan causing similar liver injury in this patient. Moreover, the short latency period suggested an immuno-allergic mechanism of injury (9). The persistence of jaundice for several weeks and slow improvement in biochemical abnormalities lasting for more than one year, which met the accepted criteria for chro-



**Figure A.** Needle liver biopsy specimen showing lobular disarray. Hepatocellular swelling, acidophilic degeneration, inflammatory infiltration with hepatocyte drop out and perivenular necrosis. (H.E.x100).



**Figure B.** Central confluent necrosis. Hepatocytes have been lost around central vein and replaced by inflammatory inflammation. (H.E.x100).



**Figure C.** Canalicular cholestasis (arrows) (H.E.x200).

nic cholestasis (10), after withdrawal of the drug were also observed in the other reported cases of irbesartan-associated hepatotoxicity (3,4).

Cholestatic hepatitis is a common expression of hepatotoxicity associated with several drugs, including nonselective angiotensin-converting enzyme (ACE) inhibitors such as captopril or enalapril (11). Hepatic injury has also been reported in the other selective AT1RAs such as losartan (12,13) and candesartan (14,15).

In our patient, although liver histology was consistent with cholestatic hepatitis rather than autoimmune hepatitis, several pieces of information strongly suggested an autoimmune pathogenesis of the liver injury, such as: absence of eosinophilia in the liver histology, high titer of ANA (1/1000), recurrence of hepatitis with jaundice after irbesartan withdrawal, rapid response to prednisolone, and complete resolution and no recurrence after prolonged course of immunosuppressive therapy. The recurrent hepatitis attack is also a feature of autoimmune hepatitis, and 10% of autoimmune hepatitis patients present with acute hepatitic attacks (16,17). It is also known that minimal to moderate autoimmune hepatitis may have no pathognomonic histologic feature (18-20). Moreover, if the 'simplified criteria of autoimmune hepatitis' proposed by the International Autoimmune Hepatitis Group Report were applied to our patient, the score obtained was consistent with 'probable autoimmune hepatitis' (21).

A liver disease resembling autoimmune hepatitis has been reported after administration of several drugs, such

as tienilic acid, dihydralazine, minocycline, methyldopa, diclofenac, nitrofurantoin, phenprocoumon, ornidazole, and atorvastatin (22-24). This form of drug-related liver damage defined as 'drug-induced, immune-mediated, liver disease', nearly always disappeared when the drug was removed (25,26). The mechanism of the triggering of immune-mediated liver injury by a drug has not been elucidated. It has been hypothesized that the reactive metabolite of the drug can act as a hapten, covalently binding liver protein, which acts as carrier (27). The hapten-carrier complex is then processed by Kupffer cells and small peptides are released. The immune system can thus be activated against a 'self' peptide, leading to autoimmunity (27). Genetic predisposition and other unknown factors are also needed to explain why immune-mediated, drug-induced, liver disease is relatively rare despite widespread use of some drugs that are known to form reactive metabolites and why macromolecular complexes never trigger immune-mediated hepatitis (5).

Although drugs are considered potential triggers of idiopathic autoimmune hepatitis, at present, no drug has been clearly identified to cause autoimmune hepatitis, and current opinion is that drug-induced, immune-mediated hepatitis hardly ever results in self-perpetuating liver disease (22,26).

However, our result, which is similar with the result found in a prior report (5), seems to indicate that irbesartan can trigger self-perpetuating liver damage and border between drug-induced, immune-mediated liver injury, and 'idiopathic' autoimmune hepatitis may be very subtle.

## REFERENCES

- Bunnier M, Brunner RH. Angiotensin II receptor antagonist. *Lancet* 2000; 355: 637-45.
- Markhan A, Spencer CM, Jarvis B. Irbesartan. An updated review of its use in cardiovascular disorders. *Drugs* 2000;59:1187-206.
- Harirah R, Stoner E, Jader S, Preston DM. Prolonged cholestasis associated with irbesartan. *BMJ* 2000;321:547.
- Andrade RJ, Lucena MI, Fernandez MC, et al. Cholestatic hepatitis related to use of irbesartan: a case report and a literature review of angiotensin II antagonist-associated hepatotoxicity. *Eur J Gastroenterol Hepatol* 2002;14:887-90.
- Annicchiarico BE, Siciliano M. Could irbesartan trigger autoimmune cholestatic hepatitis? *Eur J Gastroenterol Hepatol* 2005;17:247-8.
- Benichou C. Criteria of drug-induced liver disorders. Report of an international consensus meeting. *J Hepatol* 1990;11:272.
- Danan G, Benichou C. Causality assessment of adverse reaction to drugs – I. A novel method based on the conclusion of international consensus meeting: application to drug-induced liver injuries. *J Clin Epidemiol* 1993;46:1323-30.
- Lucena MI, Camargo R, Andrade RJ. Comparison of two clinical scales for causality assessment in hepatotoxicity. *Hepatology* 2001; 33:123-30.
- Larrey D. Drug-induced liver disease. *J Hepatol* 2000;32(Suppl 1): 77-8.
- Farrelly GC. Drug induced liver disease. *J Hepatol* 2000; Churchill-Livingstone;1994
- Zimmerman HJ. *Hepatotoxicity: the adverse effect of drugs and other chemicals on the liver*. Philadelphia: Lippincott Williams and Wilkins, 1999.
- Bosch X. Losartan-induced hepatotoxicity. *JAMA* 1997;278:1572.
- Andrade RJ, Lucena MI, Santalla F. Hepatic injury associated with losartan (letter). *Ann Pharmacother* 1998;32:1371.
- Vallejo I, Garcia-Morillo S, Pamies F. Acute hepatitis induced by candesartan. *Med Clin (Barc)* 2000;115:719.
- Gonzalez-Jimenez D, Varela JM, Calderon E. Candesartan and acute liver injury. *Eur J Clin Pharmacol* 2000;56:769-70.

16. Kessler WR, Cummings OW, Eckert G, et al. Fulminant hepatic failure as the initial presentation of acute autoimmune hepatitis. *Clin Gastroenterol Hepatol* 2004;2:625-31.
17. Kaymakoglu S, Cakaloglu Y, Demir K, et al. Is severe cryptogenic chronic hepatitis similar to autoimmune hepatitis? *J Hepatol* 1998; 28:78-83.
18. Ishak K. Pathologic features of chronic hepatitis: a review and update. *Am J Clin Pathol* 2000;113:40-55.
19. Czaja AJ, Carpenter HA. Sensitivity, specificity, and predictability of biopsy interpretations in chronic hepatitis. *Gastroenterology* 1993; 105:1824-32.
20. Goldstein NS, Bayati N, Silverman AL, Gordon SC. Minocycline as a cause of drug-induced autoimmune hepatitis. *Am J Clin Pathol* 2000;114:591-8.
21. Hennes EM, Zeniya M, Czaja AJ, et al. Simplified criteria for the diagnosis of autoimmune hepatitis. *Hepatology* 2008;48:169-76.
22. Krawit EL. Autoimmune hepatitis. In: Schiff ER, Sorrel MF, Maddrey WC, eds. *Disease of the liver*. 9th ed. Philadelphia: Lippincott Williams and Wilkins, 2003;1001-13.
23. Kosar Y, Sasmaz N, Oguz P. Ornidazole-induced autoimmune hepatitis. *Eur J Gastroenterol Hepatol* 2001;13:737-9.
24. Pelli N, Setti M, Ceppa P. Autoimmune hepatitis revealed by atorvastatin. *Eur J Gastroenterol Hepatol* 2003;15:921-4.
25. Obermayer-Straub P, Strassburg CP. Autoimmune hepatitis. *J Hepatol* 2000;32(Suppl 1):181-7.
26. Liu Z, Kaplowitz N. Immune-mediated drug-induced liver disease. *Clin Liver Dis* 2002;6:755-74.
27. Manns MP, Obermayer-Straub P. P450 and uridine triphosphate-glucuronosyltransferases: model autoantigen to study drug-induced, virus-induced, and autoimmune liver disease. *Hepatology* 1997;26:1054-66.