

Anejaculation due to Sacral Tarlov Cyst: A Case Report

Sakral Tarlov Kistine Bağlı Anejakülasyon: Olgu Sunumu

Ozge YILMAZ KÜSBECİ¹, Emre TÜZEL², Cem GÜLER³, Aylin YÜCEL⁴

¹ AKU School of Medicine Department of Neurology, Afyonkarahisar

² AKU School of Medicine Department of Urology, Afyonkarahisar

³ BÜ School of Medicine Department of Urology

⁴ BÜ School of Medicine Department of Radiology

ÖZET: Persistent or recurrent difficulty, delay in, or absence of attaining orgasm following sufficient sexual stimulation was defined as inhibited ejaculation or anejaculation that causes personal distress. Efferent innervation of ejaculation is somatic through the parasympathetic sacral outflow, originates at S2-S4. Anejaculation has neurogenic and nonneurogenic causes. Tarlov cysts occur on the extradural components of sacral or coccygeal nerve roots. Large Tarlov cysts may cause symptoms related to local compression and subsequently may affect the ejaculation. This study reports a case of anejaculation due to sacral Tarlov cyst.

Key Words: Sacral Tarlov cyst, Anejaculation.

ABSTRACT: Seksüel uyariyi takiben orgazmin oluşmasında kalıcı veya gecici zorluk, gecikme ya da orgazmin gerçekleşmemesi inhibe edilmiş ejakulasyon ya da anejakülasyon olarak tanımlanır. Ejakülasyonun efferent stimülasyonu S2 – S4 den orijin alan parasempatik liflerle sağlanır. Anejakülasyonun norojenik ve norojenik olmayan sebepleri vardır. Tarlov kistleri sakral ve koksigeal sinir köklerinin ekstradural komponentlerinden orijin alır. Geniş Tarlov kistleri lokal kompresyona bağlı semptomlara neden olabilir ve ejakülasyonu etkileyebilir. Bu çalışmada sakral Tarlov kistine bağlı gelişen anejakülasyon vakası sunulmuştur.

Anahtar Kelimeler: Sakral Tarlov kisti, Anejakülasyon

INTRODUCTION

Persistent or recurrent difficulty, delay in, or absence of attaining orgasm following sufficient sexual stimulation was defined as inhibited ejaculation or anejaculation that causes personal distress [2]. Ejaculation is a complex reflex, comprising of sensory receptors and areas, afferent pathways, cerebral sensory areas, cerebral motor centers, spinal motor centers, and efferent pathways [5]. Emission, ejaculation and orgasm are three distinct events controlled by the sympathetic nerves. During emission, smooth muscle cells of male genital tract, involving testicular tubules, efferent ducts, epididymis and vasa deferentia, contract and seminal fluid is secreted from the seminal vesicles and prostate. The bladder neck then closes and to prevent retrograde ejaculation of seminal fluid into the bladder and seminal bolus in the prostatic urethra is trapped between distal urethra, closed for erection and the bladder neck. As pressure in the seminal bolus increases the sensation of ejaculatory inevitability is

experienced [3]. The ejaculatory reflex starts from the glands and urethra filled by the seminal bolus, being innervated by somatic, sympathetic and, chiefly, parasympathetic nerves [3,7]. Efferent innervation of ejaculation is somatic through the parasympathetic sacral outflow, originates at S2-S4 and runs through the pudendal nerve, causing clonic contractions of the striated male genital tract muscles [3,8].

The non-neurogenic causes of anejaculation include psychogenic inhibited ejaculation, urogenital congenital anomalies, anatomic causes such as transurethral resection of the prostate or radical prostatectomy, infective conditions like urethritis, endocrine disturbances and using medications such as alpha-methyl dopa and antidepressants. The neurogenic causes of anejaculation are diabetic autonomic neuropathy, spinal cord injury and surgical procedures which interfere with the central or peripheral control of ejaculation such as retroperitoneal lymphadenectomy [5].

The sacral perineural cyst was first described by Tarlov. These cysts occur on the extradural components of sacral or coccygeal nerve roots. In case of larger sacral perineural cysts, the cysts communicate with the subarachnoid space and therefore filled with cerebrospinal fluid that may cause symptoms

related to local compression and subsequently may affect the ejaculation [4].

CASE REPORT

A 16-year-old boy was presented with a history of primary anejaculation to the urology department. The urological examination was uneventful and hormonal profile, postejaculatory urinalysis and transrectal ultrasonography were normal. On neurological examination, muscle strength deficit was not detected. Sensory examination showed diminished sensory perception to pinprick on the soles of his feet and in the S₁₋₂ distribution. There was no sensory deficit over the perineum. Knee jerks were hyperreflexive bilaterally and ankle jerks were normoactive bilaterally. There was no history of pain. The lumbosacral MRI demonstrated a large sacral cyst arising within the thecal sac at S₁ - S₂ (figure 1). Then the patient was referred to the neurosurgery department and surgery was planned.

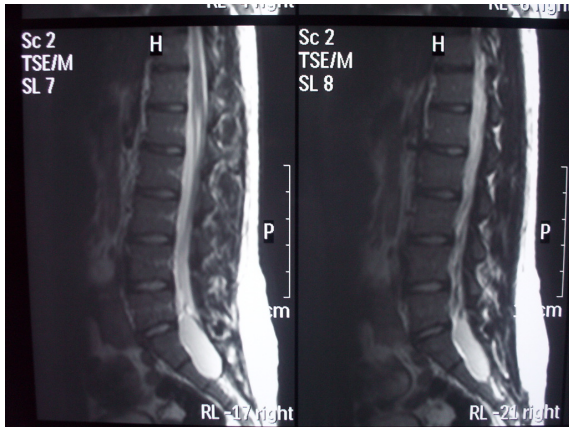


Figure 1: Tarlov cyst arising within the thecal sac at S₁ - S₂

DISCUSSION

Tarlov cysts are primarily localized to the posterior sacral or coccygeal nerve roots, most often the second and the third sacral roots. Although trauma and congenital etiology have been suggested, there is not a clear consensus on the pathogenesis of the cysts. Clinical symptoms range from radicular pain, paresthesias to urinary or bowel dysfunction and localized pain to coccygodynia. Patients may also be asymptomatic without any physical complaints or findings [1,6]. In the history of our patient we have detected isolated anejaculation, but there were no

history of pain, paresthesias, urinary or bowel dysfunctions and also there were no history of trauma, surgical operation and using medication. The urological examination was uneventful and hormonal profile was normal. Postejaculatory urinalysis and transrectal ultrasonography were normal so we excluded retrograde ejaculation and failure of emission. On neurological examination only sensory examination showed diminished sensory perception to pinprick on the soles of his feet and in the S₁₋₂ distribution and the lumbosacral MRI demonstrated a large sacral cyst arising within the thecal sac at S₁ - S₂ (figure 1).

CONCLUSION

In our case chronic pressure exerted by Tarlov cyst onto sacral roots might have led to isolated anejaculation which to our knowledge is the first case in the literature.

REFERENCES

1. Acosta FL Jr, Quinones-Hinojosa A, Schmidt MH, Weinstein PR. Diagnosis and management of sacral Tarlov cysts. Case report and review of the literature. *Neurosurg Focus*. 2003; 15:E15
2. American Psychiatry Association. Diagnostic and statistical manual of mental disorders. DSM-IV. 4th edition. Washington DC: American Psychiatric Association; 1994
3. Jannini EA, Simonelli C, Lenzi A, Sexological approach to ejaculatory dysfunction *International Journal of Andrology* 2002;25:317 – 323
4. Langdow AJ, Grundy JR, Birch NC. The clinical relevance of Tarlov cysts. *J Spinal Disord Tech*. 2005;18:29-33
5. McMahon CG, Abdo C, Incrocci L, Perelman M, Rowland D, Waldinger M, Xin ZC. Disorders of orgasm and ejaculation in men. *J Sex Med*. 2004;1:58-65
6. Nadler SF, Bartoli LM, Stitik TP, Chen B. Tarlov cysts as a rare cause of S1 radiculopathy: A case report. *Arch Phys Med Rehabil*. 2001;82:689-90
7. Yang, CC, Bradley WE Somatic innervation of the human bulbocavernosus muscle. *Clinical Neurophysiology*. 1999;110:412 – 418
8. Yavetz H, Yogev L, Hauser R, Lessing JB, Paz G & Homonnai ZT Retrograde ejaculation. *Human Reproduction*. 1994;9: 381-386

