

Accessory Tendon Variation in a Case of Hallux Rigidus

Bir Halluks Rigidus Olgusunda Aksesuar Tendon Varyasyonu

Birsen ÖZYURT¹, Taner GÜNEŞ², Bahadır ÜNGÖR¹, Mehmet ERDEM²

¹ Department of Anatomy, Gaziosmanpaşa University, Faculty of Medicine, Tokat, Turkey.

² Department of Orthopedics and Traumatology, Gaziosmanpaşa University, Faculty of Medicine, Tokat, Turkey.

ABSTRACT: Hallux rigidus is a condition caused by degenerative arthritis of the first metatarsophalangeal joint and characterized by pain and limited dorsiflexion of the great toe, but relatively unrestricted plantar flexion. In a patient who was operated for hallux rigidus it was also seen that first metatarsophalangeal joint has got an accessory tendon. In our case the accessory tendon has been inserted to medial side of the capsule of the first metatarsophalangeal joint and also to medial side of the base of the proximal phalanx of right hallux. Although in some studies coexistence of this variation with hallux valgus has been noted, coexistence of this tendon variation with hallux rigidus has not been reported before. The exact role of the accessory tendon on the biomechanics of first metatarsophalangeal joint is not clear enough and necessitates further investigation.

Key Words: Accessory tendon, variation, hallux rigidus

ÖZET: Halluks rigidus, birinci metatarsofalangeal eklemdaki dejeneratif artrit nedeniyle olduğu, ayak başparmağında sınırlı dorsifleksiyon (plantar fleksiyon göreceli olarak daha az kısıtlanmıştır) ve ağrı ile karakterize bir durumdur. Halluks rigidus nedeniyle opere edilen bir hastada aynı zamanda birinci metatarsofalangeal eklemda aksesuar bir tendonun varlığı saptandı. Vakamızdaki aksesuar tendonun hem birinci metatarsofalangeal eklem kapsülünün medialine, hem de sağ ayak başparmağı proksimal falanksın bazisinin medialine yapıldığı tespit edildi. Hallux rigidus ile bu aksesuar tendonun birlikteliği daha önce bildirilmemişken halluks valgus ile olan birlikteliğinden söz edilmektedir. Bu aksesuar tendonun birinci metatarsofalangeal eklem biyomekaniğinde oynadığı rol henüz yeterince açıklığa kavuşmamış olup ileri araştırmaları gerektirmektedir.

Anahtar Kelimeler: Aksesuar tendon, varyasyon, halluks rigidus

INTRODUCTION

An extra tendon usually originating from the extensor hallucis longus (EHL) muscle-tendon unit (or less frequently from the tibialis anterior or extensor hallucis brevis tendon) and inserting into the dorsomedial region of the first metatarsophalangeal (MTP) joint has been observed with varying frequency (between 26% and 95%) (1). This tendinous slip has been described in the literature with different names according to its pattern of insertion: extensor hallucis capsularis (EHC) when inserting into the first MTP joint capsule, extensor ossis metatarsi hallucis when inserting onto the base of the first metatarsal, extensor primi internodi hallucis when inserting onto the proximal phalanx, and accessory extensor tendon of the first MTP joint or the secondary EHL when inserting anywhere in the dorsomedial region of the

first MTP joint (1). EHC is the currently accepted term for accessory tendons of the great toe. The EHC is thought to pull the MTP capsule away from the MTP joint during dorsiflexion of the foot (1).

M. extensor hallucis longus is a muscle located in anterior compartment of the leg. It arises from the middle half of the medial surface of the fibula and from the adjacent anterior surface of the interosseous membrane. Its tendon passes deep to the superior extensor retinaculum and through the inferior extensor retinaculum and is inserted into the dorsal aspect of the base of the distal phalanx of the hallux (2). It extends the phalanges of the hallux and dorsiflexes the foot (2). In the literature it has been reported that this muscle may have a second tendon at a frequency between 35% and 80% (1,3). At a study it was also reported that it may have more than one accessory tendons at a frequency of 8.3% (3). Various sites of insertion of the extensor hallucis longus muscle were recorded other than the dorsal aspect of the base of the distal phalanx of the big toe. These were the dorsal aspect of the base of the proximal phalanx of the big toe and the capsule of the first MTP joint or a connection with the tendon of the extensor hallucis brevis (3).

Hallux rigidus is a disease characterised by pain and limitation of motion of the metatarsophalangeal joint of the great toe. Above the age of 50, the incidence is about 1/45 (4). Limitation of motion especially in the dorsiflexion is caused by the exostosis at the head of the first metatarsal bone and osteophyte at the base of the proximal phalanx. Clinical prognosis resembles osteoarthritis, since the degenerative effects cause the limitation of function. Trauma, metabolic and congenital diseases were blamed for the pathophysiology of hallux rigidus. Initially non-steroid antiinflammatory drugs and strong-based but comfortable shoes are used to suppress the synovitis and to limit the movements of the joint. In the cases that do not respond to this initial treatment surgery is applied. At the early stages decompression osteotomy and cheilectomy are the selected techniques and in the advanced stages arthrodesis and arthroplasty are the selected techniques (4).

CASE REPORT

A 55 years old female patient has been operated for hallux rigidus in the year 2005. At this patient an accessory tendon (narrower than the original tendon of extensor hallucis longus muscle) has been found as lying from the dorsal aspect of the 1. metatarsal bone to the medial aspect of the 1. metatarsophalangeal joint and inserting both to the articular capsule of that joint and also distally to the medial aspect of the base of the proximal phalanx of the right hallux. Because of the limitation of the surgical incision, the origin of the accessory tendon has not been clarified. (**Figure 1**).

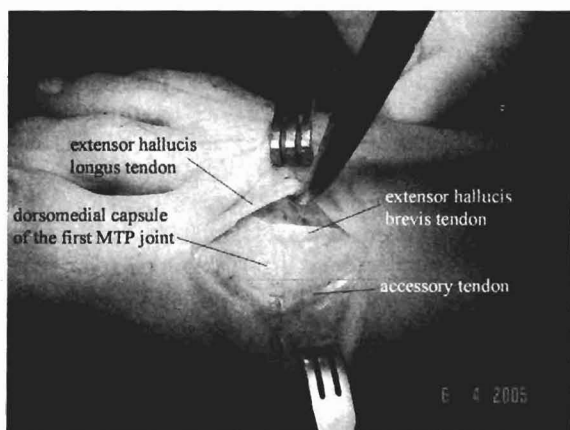


Figure 1. The view of the accessory tendon of the first MTP joint and the neighboring structures.

DISCUSSION

Boyd et al. (1) have made a study on 81 cadaver feet by dissection and they have reported that the accessory tendon named as EHC was present in 71 (88%) of the specimens (in two of the specimens there had been more than one accessory tendon). 93% of these accessory tendons have arisen from extensor hallucis longus muscle or its tendon, 3% (2 case) have arisen from the anterior tibial tendon and 1% (1 case) have arisen from the extensor hallucis brevis tendon and in 3% (2 case) the origin was indeterminate due to dissection error. The insertion of the EHC was consistent: 72 of 73 (99%) inserted into the first MTP joint capsule and one of 73 (1%) inserted into the base of the proximal phalanx (1).

Bibbo et al. (5) after their study on 32 feet of 17 cadavers have reported that 81% of feet possessed an accessory tendon to the first MTP joint. Of those feet possessing an accessory tendon to the first MTP joint, approximately 92% originated from the extensor hallucis longus muscle-tendon unit, while approximately 8% originated from the tibialis anterior muscle-tendon unit. Accessory tendons were found to be bilateral in the majority (87.5%) of specimens. Differences in sex distribution of the accessory tendon of the first MTP joint were not statistically significant. The difference in distribution of an accessory tendon to the first MTP joint in those feet that demonstrated clinical hallux valgus versus those that did not demonstrate hallux valgus was not statistically significant (5).

In our study, the origin of the accessory tendon has not been clarified but regarding the statistics of other studies we may say it has been originated from extensor hallucis longus muscle-tendon unit with a probability of about 92%.

Denk et al. (6) in their study on 47 amputated legs and 8 cadavers (totally 63 specimens) have detected by dissection that in 44 (70%) of the specimens EHL muscle had two tendons (the EHL's tendon split into a lateral and medial tendon at the level of the ankle -talocrural- joint, just beneath the inferior extensor retinaculum). While the lateral and the wider tendon has been reported to be inserted to the middle of the dorsal aspect of the base of the distal phalanx of the hallux and the medial and the thinner tendon had been inserted noticeably to the medial side of the insertion of the lateral tendon in all these 44 specimens. Additionally, on the right

foot of one of the cadavers, the extensor hallucis brevis tendon had united with the lateral tendon of the EHL and with it inserted onto the base of the distal phalanx (6).

CONCLUSION

In the search of the literature we couldn't find any report of the coexistence of hallux rigidus with the accessory tendon of the first MTP joint. Interestingly, there is no described homologue of a hallucal accessory tendon in apes or chimpanzees, thus it appears that this tendon may be unique to the human foot (5). The role of this accessory tendon on the biomechanics of the first MTP joint has not been clarified totally and necessitates further investigation. Since the accessory tendons can be used as autogenous grafts and many different kinds of surgical techniques are being used for the pathologies of great toe, the knowledge of such variations will contribute to the evaluation of potentials for radiological and surgical interventions.

REFERENCES

1. Boyd N, Brock H, Meier A, Miller R, Mlady G, Firoozbakhsh K. Extensor hallucis capsularis: frequency and identification on MRI. *Foot Ankle Int*, 2006; 27(3):181-4.
2. Williams A, Davies MS. Pelvic girdle and lower limb. In: *Gray's Anatomy (39th Ed)* London, Churchill Livingstone Medical Division of Longman UK, 2005; 1496.
3. Al-saggaf S. Variations in the insertion of the extensor hallucis longus muscle. *Folia Morphol (Warsz)*, 2003 May; 62(2):147-55.
4. Özkoç G, Hersekli MA, Akpınar S, Özalay M, Tandoğan RN. Clinical results after cheilectomy for hallux rigidus. *Joint Dis Rel Surg*, 2004; 15(1):12-14.
5. Bibbo C, Arangio G, Patel DV. The accessory extensor tendon of the first metatarsophalangeal joint. *Foot Ankle Int*, 2004 Jun; 25(6):387-90.
6. Denk CC, Oznur A, Surucu HS. Double tendons at the distal attachment of the extensor hallucis longus muscle. *Surg Radiol Anat*, 2002 Feb; 24(1):50-2.