

An Unusual Togetherness: Ileo-ileal Intussusception Due to an Ileal Lipoma and Acute Appendicitis

Sefa ERGUN, Sangar M Faroq ABDULRAHMAN,
Server Sezgin ULUDAG

Abstract

Abdominal pain is the most common reason of emergency admission in hospitals and acute abdomen is a surgical emergency condition that needs complex diagnosis and treatment. A physician must be careful at differential diagnosis of appendicitis; sometimes there is no one reason to explain the patient disturbances. Intussusception is the invagination of a proximal segment and mesentery of intestine into distal part of bowel. Intussusception can result in acute abdomen due to obstruction and is mostly seen in children aged. Adult intussusception accounts only %5-10 of all cases and is frequently caused by benign or malign tumors.

Gastrointestinal lipomas are reported as benign lesions in 1757 by Bauer. Lipomas mostly originate from adipocyte cells of the submucosa and subserosa of the intestinal wall. Lipomas smaller than 2 cm are frequently have no symptoms but larger than 2 cm diameter mostly have pain, bleeding and obstruction symptoms.

Abdominal CT is the most sensitive technique for detecting of presence and level of intussusception. Treatment of adult intussusception is always surgery. Laparoscopic surgery is an useful and succesful procedure for small intestine intussusception except cases that have contraindications for laparoscopy. In the case we determined the togetherness of intussusception due to ileal lipoma with acute appendicitis.

Keywords: Ileal lipoma, Intussusception, Appendicitis

Nadir Bir Birliktelik: İleal Lipoma Bağlı İntususepsiyon ve Akut Apendisit

Öz

Karın ağrısı hastanelerdeki acile başvuruların en sık nedenlerinden biri olup, akut batın kompleks tetkik ve tedavi gerektiren bir cerrahi acildir. Hekim akut batının bir nedeni olan apandisitini ayırıcı tanısında dikkatli olmalıdır. İntususepsiyon, bağırsağın ve mezenterinin proksimal kısmının distalinin içine girmesidir. İntususepsiyon çoğunlukla çocukluk çağında görülür ve tıkanıklığa bağlı akut batın nedeni olabilir. Erişkin intususepsiyonu tüm vakaların sadece %5-10'unu oluşturup çoğunlukla benign veya malign tümörlere bağlı oluşur. Gastrointestinal lipomlar 1757'de Bauer tarafından benign lezyonlar olarak tanımlandı. Lipomlar çoğunlukla

Istanbul University-Cerrahpasa, Cerrahpasa Medical Faculty Department of General Surgery, Fatih-Istanbul.

Corresponding author: Dr. Sefa ERGUN, Istanbul University-Cerrahpasa, Cerrahpasa Medical Faculty Department of General Surgery, Fatih-Istanbul, e-posta: sefaern@yahoo.com, Tel: 0537 893 51 48, ORCID ID: /0000-0002-0315-8044.

Received: 24 Ağustos 2020 - Accepted: 26 Eylül 2020

DOI: 10.17932/IAU.TFK.2018.008/tfk_v03i3005

bağırsak duvarının submukoza veya subserozasındaki adiposit hücrelerinden kaynaklanır. 2 cm'den küçük lipomlar genellikle semptom vermezken, 2 cm'den büyükler ağrı, kanama veya tıkanıklığa neden olabilir. Batın BT intususepsiyonun tanısı ve seviyesini tespit etmek için en duyarlı yöntemdir. Erişkin intususepsiyon tedavisi çoğunlukla cerrahidir. Laparoskopik cerrahi kontrendikasyon oluşturmadıkça ince bağırsak intususepsiyonunda kullanışlı ve başarılı tedavi yöntemidir. Bu olgu sunumunda; ileal lipoma bağırsak intususepsiyon ve akut apandisit birlikteliği olan bir hastayı değerlendirdik.

Anahtar Kelimeler: İleal lipom, İntususepsiyon, Apandisit

Introduction

Appendicitis is the most common reason for abdominal pain that needs emergency surgical treatment. Someone has a 7% risk for appendicitis over of lifetime. In appendicitis pathophysiology, mostly there is an obstruction of the appendiceal lumen because of lymphoid hyperplasia, fecaliths, some parasites, or foreign bodies. Diagnosis of appendicitis mainly consists on the patient anemnesis and physical examination (1, 2).

A physician must be careful at differential diagnosis of appendicitis and must think surgical (intestinal obstruction, cholecystitis, peptic ulcer perforation, mesenteric adenitis, meckel's diverticulitis), urological (pyelonephritis, urinary tract infection, colic pain due to stone), gynaecological (ovarian cyst rupture, ectopic pregnancy and pelvic inflammatory disease), and other medical (gastroenteritis, pneumonia, diabetic ketoacidosis, porphyria) reasons (3).

Sometimes after making differential diagnosis there is no one reason to explain the patient disturbances, we can find togetherness of some pathological diseases. In our case 56 year old woman referred to our emergency surgery unit with a abdominal pain and vomiting. After making clinical, laboratory and radiological evaluation we found acute appendicitis together with ileo-ileal intussusception due to ileal lipoma and laparoscopic appendectomy and laparoscopy-assisted ileum resection was performed. In literatures this was the first case of togetherness of ileal intussusception due to ileal lipoma and acute appendicitis. Intussusception is the invagination of a proximal segment and

mesentery of intestine into distal part of bowel (4). Mostly intussusception is seen common in childhood, 5% of all cases is in adults and it accounts only 1% of adult bowel obstructions. In adults mostly malignant or benign tumors acts as leading point of invaginated segment (5, 6).

Gastrointestinal lipomas are seen more frequent in colon than small intestine. Small lipomas have no symptoms, lesions larger than 2 cm can cause signs of obstruction or bleeding (7).

Bowel lipomas diagnosis is difficult due to lack of clinical signs and symptoms, mostly it is recognized after repeated admissions to different hospitals at different times. Ultrasonography (US) and computed tomography (CT) is useful to detect the intestinal lipomas (8).

We reported a case of laparoscopic-assited surgical management of ileal intussusception secondary to ileal lipoma together with appendicitis.

Case Report

A 56 year old woman with no previous illness was admitted to our hospital with complaining of abdominal pain and vomiting. Physical examination revealed abdominal distension, tenderness in the right lower quadrant and periumbilical area. Laboratory values were unremarkable except C-reactive protein level of 16.8 mg/L. Abdominal radiography showed small bowel air-fluid levels. Abdominal US did not provide enough information due to much air in abdomen. CT of the abdomen revealed 2 cm target-like mass, tumor with fat

density and ileo-ileal intussusception (Figure 1 a, b) and increasing on appendix diameter, edema, signs of appendicitis (Figure 1 c). Laparoscopic surgery was performed under general anesthesia. In our exploration we saw the edematous, erectile hyperemic acute appendicitis and ileo-ileal invagination at 60-70 cm proximal to ileocecum valve. Firstly we made laparoscopic appendectomy then laparotomy was performed as 4 cm in the umbilical region for an extracorporeal resection of small bowel and tumor. 10 cm of ileum including the tumor without reduction was

externalized via peritoneal cavity. We made the extracorporeal resection and a functional end-to-end anastomosis was performed.

The patient had an uneventful recovery. She began to oral fluids on day 3 and was discharged on day 5. Pathological examination of resected bowel and appendix revealed 21x30x25 mm ulcerated submucosal lipoma in the bowel and phlegmonous appendicitis.

A written informed consent is received from the patient.

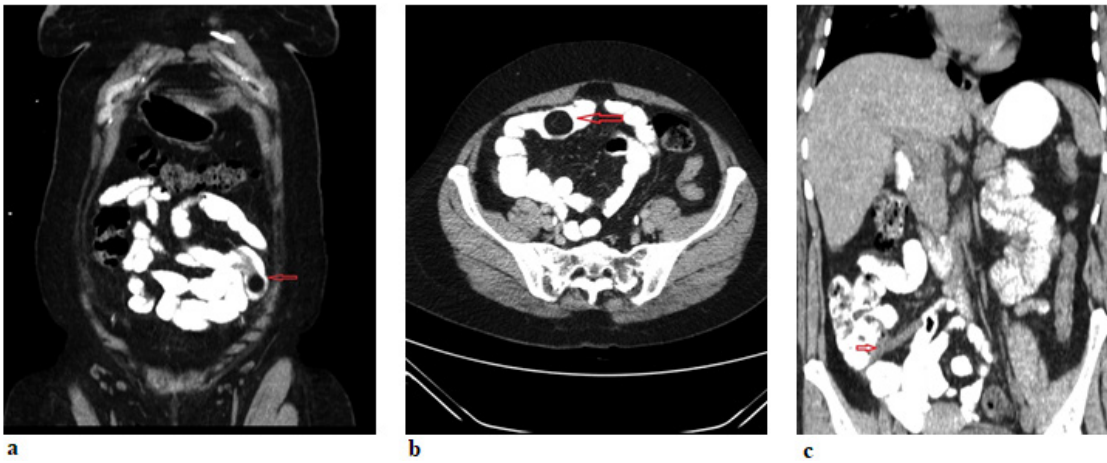


Figure 1. a) Coroner section of CT of the abdomen revealed 2 cm target-like mass, tumor with fat density and ileo-ileal intussusception. b) Axial section of CT of the abdomen that showed ileo-ileal intussusception. c) CT image of signs of appendicitis. (increasing on appendix diameter, edema)

Discussion

Abdominal pain is the most common reason of emergency admission in hospitals and acute abdomen is a surgical emergency condition that needs complex diagnosis and treatment (9). In differential diagnosis of acute abdomen appendicitis is frequently seen disease. Sometimes there can be additional factor to explain the whole cause of abdominal pathology.

Intussusception can result in acute abdomen due to obstruction and is mostly seen in children aged. Adult intussusception accounts only 5-10% of all case and is frequently caused by benign or malign tumors (5, 6). Intussusception is classified into parts as enteric, ileocolic,

ileocecal, and colonic (10). Symptoms of intussusception are abdominal pain, distension and vomiting due to obstruction, hemorrhage and diarrhea (11). Tumors of small intestine constitute nearly 1% of all gastrointestinal tumors. Primarily seen small intestine tumor is gastrointestinal tumor and second is lipomas (11, 12). Gastrointestinal lipomas are reported as benign lesions in 1757 by Bauer. Lipomas mostly originate from adipocyte cells of the submucosa and subserosa of the intestinal wall (7, 13). Location of lipomas in gastrointestinal tract is: colon (mostly in right colon) 70%, small intestine 30% (especially ileum) (14). Size of lipoma is important to cause the clinical presentation but it is not associated with the

degree of symptoms (15). Lipomas smaller than 2 cm are frequently have no symptoms but larger than 2 cm diameter mostly have pain, bleeding and obstruction symptoms (7, 16).

Due to vague abdominal symptoms detection of small intestine tumors is difficult and mostly it is done after repeated hospital admissions (10). Physical examination and history are essential point but radiologic techniques (US, CT) are very important as a complementary part. Also upper and lower gastrointestinal endoscopy, capsule endoscopy, barium enemas are useful for diagnosis.

US is non invasive and easy to do and mostly helpful for children, it seems the characteristic target 'donut' sign and psoudokidney appearance (16). In our case US was ineffective because of so much abdominal air. Abdominal CT is the most sensitive technique for detecting of presence and level of intussusception (15, 17). CT shows classic target sign or sausage shaped mass and reveals the etiology of invagination (16, 17).

Treatment of adult intussusception is always surgery to control the obstruction, bleeding and abdominal pain and prevent the complications (10, 18). There is a dilemma about reduction of invaginated segment during surgery. Some researchers think that en-bloc resection must be done because of tumor possibility and edematous loop can get injury during reduction. Other investigators advocate; reduction decreases the resected segment length of intestine to prevent the short bowel syndrome (18, 19).

We did not make reduction, we resected 10 cm of ileum and it was enough to remove the invaginated segment and tumor. But in literatures there are cases that includes; most of intestinal part is affected from intussusception and reduction was used to prevent massive resections (19, 20).

Laparoscopic surgery is an useful and successful procedure for small intestine intussusception except cases with advanced dilatation of bowels because of obstruction and have contraindications for laparoscopy (19, 21). We used laparoscopy for appendectomy and exploration, we saw the intussusception then externalized the invaginated segment for extracorporeal resection of small bowel and tumor. We made resection and a functional end-to-end anastomosis.

Conclusion

Diagnosis and management of acute abdomen is a complex issue. Like in our case there can be more than one pathology to cause it. Intussusception is uncommon in adults. CT is very important for preoperative diagnosis. Laparoscopy is an effective and succesful procedure to treatment of intussusception also useful to see the other intraabdominal pathologies.

Conflict of Interest

The authors declare no conflict of interest.

Disclosure

There were no external sources of finding for the present study.

REFERENCES

1. Liu CD, McFadden DW. Acute abdomen and appendix. *Surgery: Scientific principles and practice* 1997; 2: 1246-61.
2. Hardin DM Jr. Acute appendicitis: Review and update. *Am Fam Physician* 1999; 1: 60(7):2027-34.
3. Humes DJ, Simpson J Acute appendicitis. *BMJ* 2006; 9: 530-4.
4. Namikawa T, Hokimoto N, Okabayashi T, Kumon M, Kobayashi M, Hanazaki K. Adult ileoileal intussusception induced by an ileal lipoma diagnosed preoperatively: report of a case and review of the literature. *Surg Today* 2012; 42(7): 686-92.
5. Stubenbord WT, Thorbjarnarson B

- Intussusception in adults. *Ann Surg* 1970; 172(2): 306-10.
6. Meshikhes AW, Al-Momen SA, Al Talaq FT, Al-Jarroof AH. Adult intussusception caused by a lipoma in the small bowel: report of a case. *Surg Today* 2005; 35(2): 161-5.
 7. Dultz LA, Ullery BW, Sun HH, Huston TL, Eachempati SR, Barie PS, Shou J. Ileocecal valve lipoma with refractory hemorrhage. *JLS* 2009; 13(1): 80-3.
 8. Buckley JA, Fishman EK. CT evaluation of small bowel neoplasms: spectrum of disease. *Radiographics* 1998; 18(2): 379-92.
 9. Kamin RA, Nowicki TA, Courtney DS, Powers RD. Pearls and Pitfalls in the Emergency Department Evaluation of Abdominal Pain. *Emerg Med Clin North Am* 2003; 21: 61-72.
 10. Azar T, Berger DL. Adult intussusception. *Ann Surg* 1997; 226(2): 134-8.
 11. Yao T, Yao K, Matake H, Furukawa K, Nagae T, Motomura A. Primary small intestinal tumors (in Japanese with English abstract). *Stomach Intestine* 2001; 36: 871-81.
 12. Tsushimi T, Matsui N, Kurazumi H, Takemoto Y, Oka K, Seyama A, & Morita T. Laparoscopic resection of an ileal lipoma: Report of a case. *Surgery today* 2006; 36(11): 1007-11.
 13. Granado de la F, Granado JM, Ochoa P, Granell J. Lipoma de ciego. *Cirugía Española* 1976; 30(2):145-52.
 14. Balamoun H, Doughan S. Ileal lipoma - a rare cause of ileocolic intussusception in adults: Case report and literature review. *World J Gastrointest Surg* 2011; 3(1): 13-5.
 15. Namikawa T, Hokimoto N, Okabayashi T, Kumon M, Kobayashi M & Hanazaki K. Adult ileoileal intussusception induced by an ileal lipoma diagnosed preoperatively: report of a case and review of the literature. *Surgery today* 2012; 42(7): 686-92.
 16. Bravo AMM, Mansilla CV, Fraguas FN & Vicent, FJG. Ileocolic intussusception due to giant ileal lipoma: Review of literature and report of a case. *Int J Surg Case Rep* 2012; 3(8): 382-84.
 17. Eisen LK, Cunningham JD, Aufses AH. Intussusception in adults: institutional review. *J Am Coll Surg* 1999; 188: 390-5.
 18. Begos DG, Sandor A, Modlin IM. The diagnosis and management of adult intussusception. *T Am J Surg* 1997; 173(2): 88-94.
 19. Akagi I, Miyashita M, Hashimoto M, Makino H, Nomura T, Tajiri T. Adult intussusception caused by an intestinal lipoma: report of a case. *Journal of Nippon Medical School* 2008; 75(3): 166-70.
 20. Reijnen HA, Joosten HJ, de Boer H.H. Diagnosis and treatment of adult intussusception. *Am J Surg* 1989; 158(1): 25-8.
 21. Chekan EG, Westcott C, Low VH, Ludwig KA. Small bowel intussusception and laparoscopy. *Surg Laparosc Endosc* 1998; 8: 324-6.