

MORFOMETRİK ANALİZ KULLANILARAK INFRAORBİTAL FORAMEN LOKALİZASYONUNUN TAHMİNİ

ESTIMATION OF THE INFRAORBITAL FORAMEN LOCATION USING MORPHOMETRIC ANALYSIS

Nilgün TUNCEL ÇİNi¹, Senem TURAN ÖZDEMİR²

¹Bilecik Şeyh Edebali Üniversitesi Tıp Fakültesi, Anatomi Ana Bilim Dalı

²Bursa Uludağ Üniversitesi Tıp Fakültesi, Anatomi Ana Bilim Dalı

ÖZET

AMAÇ: Foramen infraorbitale (IOF)'nin lokalizasyonunun belirlenmesi ve çevre yapılarla olan ilişkisi birçok klinik disiplin için büyük önem taşımaktadır. Foramen supraorbitale/incisura supraorbitale (SON/SOF), IOF'nin konumunu tahmin etmek için bir işaret noktası olarak kullanılabilirliği belirtilmektedir. Bu çalışmada, IOF'nin SON/SOF ve diğer komşu anatomik yapılarla olan morfolometrik ilişkilerini kullanarak, IOF'ye müdahale için güvenli bölgeyi belirlemeyi ve IOF'nin yerini tahmin etmek için bazı regresyon formülleri üretmeyi amaçladık.

GEREÇ VE YÖNTEM: Cinsiyeti bilinmeyen 33 kuru yetişkin kafatasında IOF, foramen supraorbital kullanılarak 14 parametre ile değerlendirildi. Kemiklerin fotoğrafları çekildikten sonra Image J programı ile ölçümler gerçekleştirildi.

BULGULAR: Tüm ölçümler için ortalama değerler verildi ve taraf farkı görülmedi. Parametrelerin minimum değerleri kullanılarak IOF'ye yönelik müdahaleler için güvenli bölge belirlendi. Sağ ve sol tarafa ait ortalama değerleri kullanılarak aralarındaki korelasyonu katsayıları tespit edildi. Spearman'ın korelasyon testi sonucunda bazı değerlerin birbirleriyle yüksek korelasyon gösterdiği görüldü. IOF'nin yerini tahmin etmek için bazı regresyon formülleri oluşturuldu. En iyi formül %96 doğruluk oranı ile $IOF = 1.632 + (0.743 * SON/SOF-IMO) + (0.184 * SON/SOF-kanin\ krestal\ kemik)$ olarak belirlendi.

SONUÇ: Nörovasküler yapıları içeren IOF büyük hasar riski taşıdığından, maksillofasiyal plastik cerrahi ve diş hekimlerinin odak noktasıdır. Bu çalışmada, IOF'nin konumunu yüksek doğrulukla tahmin etmek için bazı güvenilir regresyon formülleri verildi.

ANAHTAR KELİMELER: Foramen infraorbitale, Regresyon, Foramen supraorbitale, Kafatası.

ABSTRACT

OBJECTIVE: Determining/ Identifying the localization of the infraorbital foramen (IOF) and its relationship with surrounding structures have great importance for many clinical disciplines. It is suggested that supraorbital foramen/notch (SOF/SON) can be used as a landmark to estimate the location of the IOF. In this study, using the morphometric relationships of the IOF with the SON and other neighboring anatomical structures, we aimed to determine the safe zone for the intervention of the IOF and give some regression formulas to estimate the location of the IOF.

MATERIAL AND METHODS: On the 33 dry adult skulls which are of unknown gender, IOF was evaluated using the supraorbital foramen with the 14 parameters. After the photographs of the bones were taken, measurements were made with the Image J program.

RESULTS: The mean values for all measurements were given and no side differences were seen. The safe zone for the intervention to the IOF was identified with the minimum values of the parameters. The mean values of the right and left sides were used to evaluate the correlation between parameters. As a result of Spearman's correlation test, it was observed that some values showed a high correlation with each other. Some regression formulas were created to estimate the location of the IOF. The best formula was determined as $IOF = 1.632 + (0.743 * SON/SOF\ to\ the\ IMO) + (0.184 * SON/SOF\ to\ the\ canine\ crestal\ bone)$; with 96% accuracy.

CONCLUSIONS: The IOF is a focus point of maxillofacial plastic surgery and dentistry because the neurovascular bundle of IOF has a great damage risk. In this study, we have given some reliable regression formulas to estimate the location of the IOF with the high accuracy.

KEYWORDS: Infraorbital foramen, Regression, Supraorbital foramen, Skull.

Geliş Tarihi / Received: 24.03.2021

Kabul Tarihi / Accepted: 27.08.2021

Yazışma Adresi / Correspondence: Dr. Öğr. Üyesi Nilgün TUNCEL ÇİNi

Bilecik Şeyh Edebali Üniversitesi Tıp Fakültesi, Anatomi Ana Bilim Dalı

E-mail: nntuncel@gmail.com

Orcid No (Sırasıyla): 0000-0003-1412-2634, 0000-0002-0407-3608

INTRODUCTION

The infraorbital region is a component of the midface which contains clinically crucial structures including the infraorbital foramen (IOF), the infraorbital nerve (ION) and infraorbital vessels. The IOF is situated bilaterally in the infraorbital region and located approximately 1 cm (varying from 4 to 12 mm) below the infraorbital margin (1, 2). It is an important anatomical landmark for the anesthetic interventions of the midface and paranasal sinuses. Various surgical procedures such as polypectomy, turbinectomy, and nasal bone fracture reduction can be performed with regional block anesthesia of the infraorbital nerve (ION) with low complication rates (3). The identification of the IOF is also important for the prevention of iatrogenic injury of the ION in the maxillofacial surgeries because the traumatic or iatrogenic injuries of the ION can result in hypoesthesia, paraesthesia, or anesthesia (4). For these reasons, the importance of the ION and the IOF localization is even better understood, so determining the distance of IOF to certain anatomical points will help before surgical and anesthetic interventions. Detailed knowledge of the precise anatomical location of the IOF is fundamental to ensure safe and successful regional anaesthesia and avoid the risk of damaging the neurovascular bundle (4, 5).

In the literature, there are many studies which have focused on the distances between the IOF and with the environmental soft tissue structures, bone landmarks, anatomical planes, and foramen. Among the bone landmarks, the inferior rim of the orbit is the most used as the reference landmark (6). On the other hand, there is a popular belief that supraorbital notch/foramen (SON/SOF) and IOF are on the same sagittal plane, so it is suggested that SON can be used as a landmark to estimate the location of the IOF (1, 7). Although the position of the IOF with respect to SON is still controversial and not a reliable point for the estimation of the IOF, it is still a focal point of the studies (1, 8).

In this study, we aimed to determine the safe zone for the interventions to the IOF and give some regression formulas to estimate the location of the IOF using the morphometric rela-

tionships of the IOF, SON and other neighboring anatomical structures. Thus, we believe that it will provide ease of use to surgeons by using formulas created with mathematical models.

MATERIALS AND METHODS

The study was conducted on the dry human bones belonging to the osteological collection of the Bursa Uludag University Faculty of Medicine, Anatomy Department. On the 33 dry adult skulls which are unknown gender, the infraorbital foramen was evaluated using the supraorbital foramen with the fourteen parameters (Figure 1).

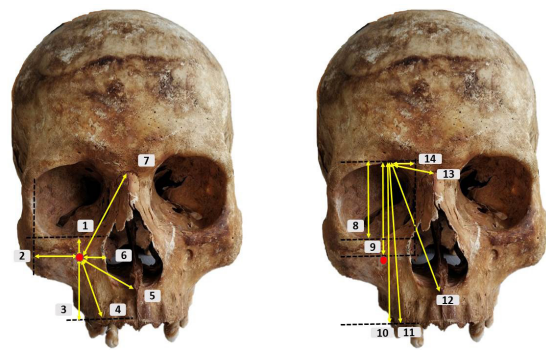


Figure 1: Landmarks and the measurements of the IOF; 1) Distance between the upper margin of the IOF and IMO; 2) Distance between the lateral margin of the IOF and LMO; 3) Distance between the inferior margin of the IOF and horizontal plane of canine crestal bone; 4) Distance between the inferior margin of the IOF and canine crestal bone; 5) Distance between the medial margin of the IOF and anterior nasal spine; 6) Distance between the medial margin of the IOF and lateral border of piriform aperture; 7) Distance between the upper margin of the IOF and nasion; 8) Distance between the medial border of the SON (or the inferior margin of the SOF) and IMO; 9) Distance between the medial border of the SON (or the inferior margin of the SOF) and upper margin of the IOF; 10) Distance between the medial border of the SON (or the inferior margin of the SOF) and horizontal plane of canine crestal bone; 11) Distance between the medial border of the SON (or the inferior margin of the SOF) and canine crestal bone; 12) Distance between the medial border of the SON (or the inferior margin of the SOF) and anterior nasal spine; 13) Distance between the medial border of the SON (or the inferior margin of the SOF) and nasion; 14) Distance between the medial border of the SON (or the inferior margin of the SOF) and medial margin of orbita
IOF: infraorbital foramen; IMO: inferior margin of orbita; LMO: lateral margin of orbita; SON: supraorbital notch; SOF: supraorbital foramen

The inferior margin of the supraorbital foramen (SOF) was used for the measurements. If it was like the shape of the notch (SON), the medial border of the SON was used. To evaluate the position of the IOF to the SON/SOF, the medial border of the SON was used if it was shaped like a notch. If it was foramen, the center of the SOF was used. The following measurements are:

1) Distance between the upper margin of the infraorbital foramen and inferior margin of orbita (IMO)

- 2) Distance between the lateral margin of the infraorbital foramen and lateral margin of orbita (LMO)
- 3) Distance between the inferior margin of the infraorbital foramen and horizontal plane of canine crestal bone
- 4) Distance between the inferior margin of the infraorbital foramen and canine crestal bone
- 5) Distance between the medial margin of the infraorbital foramen and anterior nasal spine (ANS)
- 6) Distance between the medial margin of the infraorbital foramen and lateral border of the piriform aperture
- 7) Distance between the upper margin of the infraorbital foramen and nasion
- 8) Distance between the medial border of the supraorbital foramen/notch and inferior margin of orbita
- 9) Distance between the medial border of the supraorbital foramen/notch and the upper margin of the infraorbital foramen
- 10) Distance between the medial border of the supraorbital foramen/notch and the horizontal plane of canine crestal bone
- 11) Distance between the medial border of the supraorbital foramen/notch and canine crestal bone
- 12) Distance between the medial border of the supraorbital foramen/notch and anterior nasal spine
- 13) Distance between the medial border of the supraorbital foramen/notch and the nasion
- 14) Distance between the medial border of the supraorbital foramen/notch and medial margin of orbita

The bones which have deformities or fractures are excluded from the study. The photographs of the bones were taken with the Nikon D5000 camera with the standard position using the ruler on one side to provide the calibration. The fourteen parameters were measured on the photos with the ImageJ software with the same researcher.

The safe zone for the intervention to the IOF has been determined through the minimal distances to the neighbor anatomical structures.

Through the regression formulas, we aimed to estimate the location of the IOF. For this, the supraorbital foramen has been chosen due to the thought it is used as a landmark to locate the IOF and palpate easily (1, 4, 5). Percentage values of the notch or foramen are calculated on the crania, and then the position of the infraorbital foramen to the supraorbital foramen/notch has been determined.

Ethical Committee

The authors declare that the study was performed in accordance with the ethical standards as mentioned in the 1964 Declaration of Helsinki. This study does not contain human participants or experiments on human/animals and the skulls are the donation of the cadavers and belong to the Anatomy department so there is no ethics committee decision.

Statistical Analysis

The statistical values were performed with SPSS 22.0 ($p < 0.005$) software (IBM). Simple regression is used which is a mathematical model that gives formulas to predict the variable. The adjusted R^2 is a value of that the percentage of accuracy (9). To locate the IOF with the formulas, IOF and certain neighbor structures are used.

Due to being seen no side differences, mean values of the right and left are used to evaluate the correlation between parameters. Pearson correlation test has been conducted, and some values have shown a high correlation with each other.

RESULTS

Of the total skulls, the percentage of the supraorbital shape was bilaterally foramen on 69%, and 17% was notch shape. In the percentage of 14%, it was a notch on one side and foramen on the other side. On the right side, 79% percentage, its shape was notch and 21% foramen.

On the left side, it was 69% notch-like and 11% foramen. The location of the IOF to the SON/SOF was determined also. The IOF was located laterally of the SON/SOF in the 73% for the right

and 74% for the left. It was located medially of the SON/SOF in the 24% for the right and 17% for the left. For the right side at 2% and for the left side at 1%, the SON/SOF and the IOF were the same vertical plane. The mean length for all measurements has been given, and no side differences have been seen (Table 1, The Student's t-test; $p < 0.005$ significant difference).

Table 1: The mean values of the parameters and standart deviation (mm) ($p < 0.005$; S.D. standard deviation)

| Parameter | RIGHT | | | LEFT | | | Side difference p value |
|-----------|--------|-------|-------------|--------|--------|-------------|----------------------------|
| | Mean | S.D. | Range | Mean | S.D. | Range | |
| 1 | 7.883 | 1.671 | 5.14-12.94 | 7.790 | 1.869 | 4.15-13.53 | 0.843 |
| 2 | 21.406 | 3.146 | 16.60-30.25 | 20.350 | 2.585 | 16.56-25.34 | 0.167 |
| 3 | 28.099 | 6.101 | 18.81-44.55 | 28.035 | 5.689 | 16.14-42.09 | 0.968 |
| 4 | 29.631 | 6.014 | 20.55-46.06 | 29.753 | 5.469 | 18.12-42.62 | 0.938 |
| 5 | 32.595 | 3.263 | 26.08-46.06 | 31.994 | 3.651 | 23.17-38.32 | 0.527 |
| 6 | 14.505 | 2.423 | 10.29-19.74 | 13.928 | 2.776 | 6.85-20.54 | 0.404 |
| 7 | 44.802 | 5.915 | 35.70-56.50 | 44.492 | 5.197 | 33.62-57.54 | 0.833 |
| 8 | 37.865 | 4.140 | 31.31-46.49 | 38.602 | 4.284 | 30.00-46.11 | 0.520 |
| 9 | 42.794 | 4.857 | 34.80-53.53 | 43.513 | 4.867 | 34.87-53.29 | 0.586 |
| 10 | 70.762 | 9.577 | 56.78-94.23 | 71.894 | 10.066 | 53.53-99.63 | 0.680 |
| 11 | 71.170 | 9.653 | 56.78-94.77 | 72.409 | 9.829 | 56.66-97.07 | 0.649 |
| 12 | 66.002 | 6.600 | 56.34-81.04 | 66.818 | 7.558 | 53.14-79.96 | 0.685 |
| 13 | 25.879 | 3.678 | 19.30-36.25 | 26.077 | 3.531 | 19.04-32.83 | 0.840 |
| 14 | 11.808 | 3.039 | 7.15-18.97 | 13.637 | 3.155 | 8.25-22.96 | 0.053 |

To determine the safe zone for the intervention to the IOF, the distances between the IOF and IMO, LMO, canine crestal bone, anterior nasal spine, piriform aperture, and nasion point has chosen, and minimum values have been taken into consideration. So, the mean distance between the upper margin of the IOF and IMO is 5.144 mm for the right and 4,149 mm for the left.

The mean distance between the lateral margin of the IOF and LMO is 16.600 mm for the right and 16.555 mm for the left. The mean distance between the inferior margin of the IOF and the horizontal plane of the canine crestal bone is 18.814 mm for the right, and for the left it is 16,143 mm. The mean distance between the inferior margin of the IOF and canine crestal bone is 20.554 mm for the right, and 18.122 mm for the left. The mean distance between the medial margin of the IOF and the anterior nasal spine is 26.075 mm for the right, and 23.173 mm for the left. The mean distance between the medial margin of the IOF and the lateral border of the piriform aperture is 11.292 mm for the right, and 9.853 mm for the left. The mean distance between the upper margin of the IOF and the nasion is 38.699 mm for the right, and 36.615 mm for the left (Figure 2).

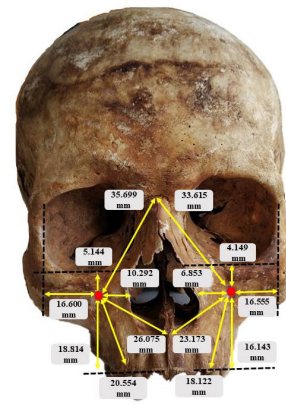


Figure 2: Safe zone for the intervention to the IOF

The distance between the inferior margin of the IOF and the horizontal plane of canine crestal bone has a high correlation with the distance between the medial border of the SON (or the inferior margin of the SOF) - the horizontal plane of the canine crestal bone ($R=0.828$) and with the distance between the medial border of the SON (or the inferior margin of the SOF) - the canine crestal bone ($R=0.809$). The distance between the medial margin of the IOF and the anterior nasal spine has a correlation with the distance between the medial margin of the IOF - the lateral border of piriform aperture ($R=0.808$) and with the distance between the upper margin of the IOF - the nasion ($R=0.809$). The distance between the medial border of the SON (or inferior margin of SOF) and the IMO has a very high correlation with the distance between the medial border of the SON (or inferior margin of SOF) - the upper margin of IOF ($R=0.949$), also with the distance between medial border of the SON (or inferior margin of SOF) - the horizontal plane of canine crestal bone ($R=0.811$), with the distance between the medial border of the SON (or the inferior margin of the SOF) - canine crestal bone ($R=0.830$), with the distance between the medial border of SON (or the inferior margin of the SOF) - the anterior nasal spine ($R=0.939$) and with the distance between the medial border of the SON (or the inferior margin of the SOF) - the nasion ($R=0.854$). As a result of these high correlation values, some regression formulas have been created to estimate the location of the IOF (Table 2). The best formula is written with the distance between the medial border of the SON (or the inferior margin of the SOF) and the inferior margin of the orbita, and it has high accura-

cy. The distance from the SON/SOF to the upper margin of the IOF= $1.632 + (0.743 * \text{SON/SOF to the IMO}) + (0.184 * \text{SON/SOF to the canine crestal bone})$; with the 96% accuracy.

Table 2: Regression formulas to estimate the location of the IOF (S.E.; standart error)

| Formulas | Adjusted R2 | S.E. |
|--|-------------|-------|
| $9 = 1.475 + (1.088 * 8)$ | 0.921 | 1.765 |
| $9 = 1.632 + (0.743 * 8) + (0.184 * 10)$ | 0.956 | 1.347 |
| $9 = 0.841 + (0.495 * 8 + (0.354 * 12))$ | 0.947 | 1.477 |
| $3 = 4.297 + (0.340 * 10)$ | 0.555 | 3.801 |
| $3 = 14.173 + (0.773 * 10) - (0.617 * 12)$ | 0.804 | 2.513 |

DISCUSSION

In the literature, the studies give so many descriptive values of the IOF and its relationship with neighboring structures. In this study beyond the descriptive values, with the regression formulas, we aimed to estimate the location of the IOF. The location of the IOF can be estimated approximately with an accuracy rate of approximately 90% and above with the formulas. Although the reliability of SON / SOF is controversial in many studies, it appears to be an important anatomical landmark for the identification of the IOF.

The supraorbital notch was located bilaterally 69% of the skulls and 14% unilaterally. On the right side it was 79% and on the left side 69%.

The supraorbital foramen was 21% on the right side, and it was 11% on the left side. Ashwini et al. (10) stated that the supraorbital notch was 69.87% and the supraorbital foramen was 28.91% on the 83 skulls. The supraorbital notch was located bilaterally in 56.2% of all the skulls and the supraorbital foramen was located in the 14.45% bilaterally. Sharma et al. (11) claimed that of all the skulls, the supraorbital foramen was 62% bilaterally, and 21% unilaterally. 17% of the skulls, it was a notch one side and foramen contralateral side. Our results are very close to these percentages.

There are a lot of studies which have focused on the distances between IOF and other anatomical structures especially, the distance between IOF to the inferior and lateral margin of orbita which is widely used as an anatomical landmark (6). Raschke et al. (12) have reported that the mean distance from IOF to the infra-

orbital rim, the piriform aperture, and the lateral rim of orbita is 8.61 ± 0.64 mm, 17.43 ± 1.19 mm, 25.93 ± 1.59 mm in males, 8.25 ± 0.54 mm, 15.69 ± 0.76 mm, 24.21 ± 1.68 mm in females respectively. They stated that there is a gender difference in the distances between the IOF-piriform aperture and IOF-lateral rim of orbita, but not the IOF-infraorbital rim. Nanayakkara et al. (4) stated that the mean distance between IOF to the infraorbital rim is 6.83 ± 1.97 mm in males and 5.52 ± 1.96 mm in females for the right. For the left, it was 7.666 ± 1.42 mm in males, and 6.38 ± 1.71 mm in females. The same study stated that the distance between IOF to the ANS is 34.25 ± 2.24 mm in males and 32.41 ± 3.56 mm in females for the right; 34.41 ± 2.00 mm in males and 33.34 ± 4.05 mm in females for the left side. The distance between IOF to the nasion is 42.70 ± 3.63 mm in males and 41.20 ± 3.00 mm in females for the right; 42.79 ± 3.36 mm in males and 41.53 ± 2.92 mm in females for the left side.

They concluded that there were side differences and left side parameters were greater than the right side, especially between the distance IOF and the infraorbital rim. No side differences have been observed in our study.

Singh (6) claimed that the mean distance between IOF and the infraorbital rim is 6.12 ± 1.8 mm on the right side and 6.19 ± 1.81 mm on the left side, and the mean distance between the IOF and the piriform aperture was 15.31 ± 1.77 mm and 15.86 ± 2.86 mm respectively, regardless of gender. Michalek et al. (13) measured this distance with ultrasound and the mean distance was 7.6 ± 1.3 mm, they also measured directly and the result was 6.7 ± 0.9 mm. Our results were close to these values.

The most used neighbor anatomical structure to locate the IOF is the infraorbital rim (6). There are also many locations to locate as well as ANS, piriform aperture and nasion and another structure. Aggarwal et al. (14) showed that the distance between IOF to the infraorbital is 6.37 ± 1.52 mm for the right, and 6.28 ± 1.25 mm for the left. The distance between IOF to the piriform aperture was 15.51 ± 1.63 mm for on the right and 14.87 ± 1.73 mm on the left. And the distance between IOF to the maxillary alveolar border is 28.38 ± 2.85 mm for the right

and 28.44 ± 2.81 mm for the left. Lee et al. (15) reported that the mean distance IOF to the inferior orbital rim on the right side is 8.49 ± 1.5 mm for the male and 8.33 ± 1.5 mm for the female. On the left side, it was 8.50 ± 1.6 mm for males, and 8.34 ± 1.8 mm for females. Varshney and Sharma (16) stated that the mean distance from IOF to the infraorbital margin is 7.65 ± 1.35 mm on the right side and 7.11 ± 1.73 mm on the left side and from the infraorbital foramen to the lower border of alveolus of the maxilla on the right 25.98 ± 1.89 mm and 25.27 ± 2.17 mm on the left. They also showed that the distance between IOF to the infraorbital rim is, 7.65 ± 1.35 mm on the right, 7.11 ± 1.73 mm on the left; IOF to the piriform aperture is 17.34 ± 1.69 mm, 17.58 ± 1.23 mm respectively. Kazkayasi et al. (17) reported that the mean distance from IOF to the nasal aperture is 17.20 ± 2.64 mm and the between IOF canine bone crest 35.00 ± 2.80 mm. There are lots of studies which give the mean values to the certain anatomical structures, and compare the gender and side differences in the literature. In our study, we give the formulas to locate the IOF mathematically. Gupta stated that IOF is in the same line as the SON on 80 percent of the skulls (8). Aziz et al. (18) claimed that the distance between SON and IOF is 43.30 ± 3.10 mm in males, and 42.20 ± 2.40 mm in females. They also stated that there were no statistically significant differences between sides or sexes. Chrcanovic et al. (19) stated that the distance from the upper wall of the SON to the upper wall of the IOF is 43.28 ± 3.17 mm for the right, 43.58 ± 3.37 mm for the left in males and 42.44 ± 2.93 mm for the right, 42.89 ± 3.14 mm for the left in females. They claimed that there were no side differences or gender. In our study; 42.79 ± 4.85 mm for the right, 43.51 ± 4.86 mm for the left, and no side differences were statistically observed. In 1999, Ikiz (20) studied the position of the infraorbital foramen in relation to the supraorbital foramen. In the study, it is claimed that the distance from the center of the SOF/SON to the center of the IOF is 50.2 ± 5.9 mm for the right and 50.4 ± 4.5 mm for the left.

The distance between the center of the IOF and the infraorbital rim is 9.5 ± 2.4 mm for the right side and 9.6 ± 2.0 mm for the left side. Contrary to our study, the center of the IOF was used as

a reference to measure the distances. The position of the IOF to the supraorbital foramen is not agreed upon in the literature. Aziz et al. (18), reported that the IOF and the SOF/SON were in the same vertical plane of the 50% of the cadavers. Chrcanovic et al. (19) claimed that this percentage was only seen in %52,50 and Chung et al. (21) claimed that this was in 36,4%. In our study, this was %2 for the right and %1 for the left. We think that this dramatic difference is due to the different reference points chosen for the supraorbital foramen in the articles. It could be said that the medial side of the SON or the center of the SOF could be used as a reliable point to locate the IOF.

It is important to protect the vessels and nerve structures in the region in interventions to the infraorbital region. We believe that estimating the localization of the IOF using the easily palpable SOF will provide ease of use for surgeons.

There are so many studies and give lots of descriptive values about the IOF and distances to other anatomical structures. In this study, we found close values with the literature. In the continuation of these studies we aimed to locate the IOF using the SON/SOF. We give some reliable regression formulas for this purpose with the help of mathematics. We hope our findings will help the surgeons to locate the IOF.

In this study, because of the unknown gender, we did not report any gender difference. The number of the skull was lower. The side difference was not observed in this study and this would be because of the low number of the skull.

ACKNOWLEDGEMENT

We thank all the individuals who have donated themselves as cadaver because of their belief in Science.

REFERENCES

1. Arx TV, Lozanoff S. Clinical Oral Anatomy: A Comprehensive Review for Dental Practitioners and Researchers. Switzerland: Springer Nature. 2017:71-84.
2. Junior O, Moreira RT, Neto BL, et al. A Morphological and Biometric Study of the Infraorbital foramen (E2 Sibai Point) in Adult Skulls. *Int J Morphol.* 2012;30(3):986-92.
3. Altan Kara S, Unal B, Erdal H, et al. Radiologic analysis of Infraorbital Foramen Anatomy. *KBB ve BBC Dergisi.* 2003;11(1):17-21.

4. Nanayakkara D, Peiris R, Mannapperuma N, et al. Morphometric Analysis of the Infraorbital Foramen: The Clinical Relevance. *Anatomy Research International*. 2016;11:1-8.
5. Cutright B, Quillopa N, Schubert W. An anthropometric analysis of the key foramina for maxillofacial surgery. *J Oral Maxillofac Surg*. 2003;61:354–57.
6. Singh R. Morphometric analysis of infraorbital foramen in Indian dry skulls. *Anat Cell Biol*. 2011;44:79–83.
7. Przygocka A, Podgorski M, Jedrzejewski K, et al. The Location of the infraorbital foramen in human skulls, to be used as new anthropometric landmarks as a useful method for maxillofacial surgery. *Folia Morphol*. 2012;71(3):198-204.
8. Gupta T. Localization of important facial foramina encountered in maxillo-facial surgery. *Clin Anat*. 2008;(21):633-40.
9. Jan SL, Shieh G. Sample size calculations for the validation in linear regression analysis. *BMC Medical Research Methodology*. 2019;19:54.
10. Ashwini LS, Mohadas Rao KG, Saran S, et al. Morphological and Morphometric Analysis of Supraorbital Foramen and Supraorbital Notch: A Study on Dry Human Skulls. *Oman Medical Journal*. 2012;27(2): 129-33.
11. Sharma N, Varshney R, Faruqi NA, et al. Supraorbital Foramen- Morphometric Study and Clinical Implications in Adult Indian Skulls. *Acta Medica International*. 2014;1(1):1-9.
12. Raschke R, Hazani R, Yaremchuk MJ. Identifying a Safe Zone for Midface Augmentation Using Anatomic Landmarks for the Infraorbital Foramen. *Aesthetic Surgery Journal*. 2012;33(1):13-18.
13. Michalek P, Donaldson W, McAleavey F, et al. Ultrasound imaging of the infraorbital foramen and simulation of the ultrasound-guided infraorbital nerve block using a skull model. *Surg Radiol Anat*. 2013;35:319–22.
14. Aggarwal A, Kaur H, Gupta T, et al. Anatomical study of the infraorbital foramen: a basis for successful infraorbital nerve block. *Clin Anat*. 2015;28:753-60.
15. Lee T, Lee H, Baek S. A three-dimensional computed tomographic measurement of the location of infraorbital foramen in East Asians. *J Craniofac Surg*. 2012;23:1169–73.
16. Varshney R, Sharma N. Infraorbital foramen – Morphometric study and clinical applications in Adult Indian Skulls. *Saudi Journal for Health Sciences*. 2013;2(3):151-55.
17. Kazkayasi M, Ergin A, Ersoy M, Tekdemir I, et al. Certain anatomical relations and the precise morphometry of the infraorbital foramen – canal and groove: an anatomical and cephalometric study. *Laryngoscope*. 2011;111: 609–14.
18. Aziz SR, Marchena JM, Puran A. Anatomic characteristics of the infraorbital foramen: a cadaver study. *J Oral Maxillofac Surg*. 2000;58(9): 992-6.
19. Chrcanovic BR, Abreu MH, Custodio AL. A morphometric analysis of supraorbital and infraorbital foramina relative to surgical landmarks. *Surg Radiol Anat*. 2011;33:329–35.
20. İkiz I. Incisura (Foramen) Supraorbitalis'in Varyasyonları ve Foramen Infraorbitale'nin Pozisyonu. *Uludağ Üniversitesi Tıp Fakültesi Dergisi*. 1999;26:9-12.
21. Chung MS, Kim HJ, Kang HS, et al. Locational relationship of the supraorbital notch or foramen and infraorbital and mental foramina in Koreans. *Acta Anat (Basel)*. 1995; 154:162–6.