



Traumatic anterior dislocation of the hip associated with ipsilateral femoral neck fracture: a case report

Aynı tarafta femur boyun kırığıyla beraber travmatik öne kalça çıkığı: Olgu sunumu

Irfan ESENKAYA,¹ Mucahit GORGEC²

¹Inonu University Medical Faculty Orthopaedics and Traumatology Department, Malatya-TURKEY

²Haydarpaşa Numune Teaching and Research Hospital, Orthopaedics and Traumatology Department, Istanbul-TURKEY

Otuz dokuz yaşındaki kadın hasta acil polikliniğimize trafik kazası öyküsüyle getirildi. Direkt radyolojik muayenesinde sol tarafta subkapital femur kırığıyla beraber travmatik öne kalça çıkığı, sağ tarafta femur diafiz parçalı kırığı saptandı. Bilgisayarlı tomografi incelemesinde, sol tarafta asetabulumun boş olduğu ve femur başının obturator deliğe yakın bölgeye deplase olduğu görüldü. Sol kalçaya primer olarak çimentosuz total kalça protezi, karşı taraftaki femur kırığının tedavisi için kilitli intramedüller çivi uygulandı. Ameliyattan 62 ay sonra yapılan kontrolde, hastanın günlük aktivitelerini zorlanmadan yapabildiği saptandı.

Anahtar sözcükler: Femur boynu kırığı/cerrahi; femur başı/yaralanma; kalça çıkığı/komplikasyon; kalça kırığı/komplikasyon.

A thirty-nine-year-old female patient was brought to the emergency room following an automobile accident. Radiographic examination revealed a subcapital fracture of the left femur associated with anterior femoral head dislocation, and a contralateral comminuted femoral shaft fracture. Computed tomography showed that the acetabulum was empty, with the femoral head dislocated anteriorly close to the obturator foramen. Uncemented total hip arthroplasty and locked intramedullary nailing were performed on the left and right sides, respectively. Sixty-two months after surgery, she had no difficulty in performing daily activities.

Key words: Femoral neck fractures/surgery; femur head/injuries; hip dislocation/complications; hip fractures/complications.

Traumatic anterior dislocation of the hip associated with ipsilateral femoral neck fracture is a rare injury.^[1-4] Epstein et al.^[5] defined that the most important factor causing traumatic anterior dislocation of the hip is forcible abduction; in this position causes femoral neck and trochanter major become tightly impinges on the acetabular rim and as a result, femoral head is levered out of the acetabulum and is vigorously pushed towards anterior part of the capsule. During this strain if the hip is in flexed, obturator type hip dislocation; if the hip is in extended, pubic type hip dislocation occurs.^[5] Fractures of

femoral neck may occur if this strain continues.^[4] A stated, traumatic anterior hip dislocation associated with ipsilateral subcapital femoral fracture case is presented in this article.

Case report

A 39-year-old female was presented to the emergency polyclinic of Haydarpaşa Numune Hospital Orthopaedics and Traumatology Department as a result of car accident in July 1996. After the assessment of general status, it was seen that she could not move her both lower extremities which were in

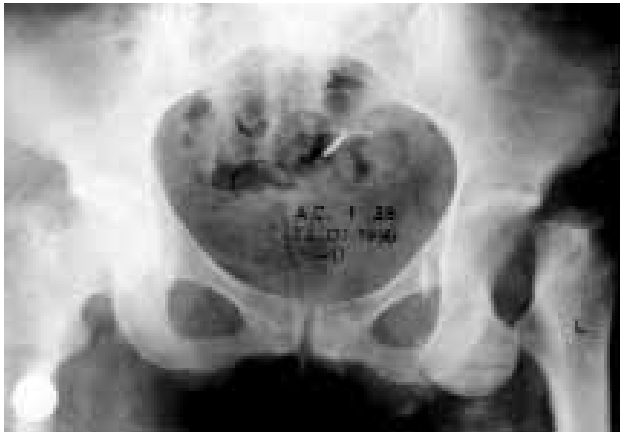


Figure 1. Ipsilateral traumatic anterior dislocation of the hip associated with subcapital femoral neck fracture on the left side, on AP plain radiograph.

external rotation, in physical examination. Traumatic anterior dislocation of the hip associated with ipsilateral left femoral subcapital neck fracture (Fig.1) and contralaterally right femoral comminuted fracture of diaphysis were detected on roentgenographic evaluation. On the CT scans (cross sections) of pelvis and hip it's also detected that acetabulum on left side was empty and associated femoral head was displaced to a region near the obturator foramen (Fig.2). A surgical approach was performed to left hip by lateral approach after reduction and fixation of femoral fracture with the locked intramedullary nailing on left side was completed. Musculus vastus lateralis and musculus gluteus medius were ecchymotic. An extensive hematoma was detected in the anteroinferior region of hip joint as the dissection became deeper. It's seen that, anteroinferior edges of the joint capsule were torn irregularly. Acetabulum was empty; femoral neck fracture was detected approximately 2.5-3 cm over the trochanter minor. It's appointed that the fragment of broken femoral head and neck detected in preoperative plain radiographs and CT scans was in anteroinferior part of the acetabulum near obturator foramen. A defect was detected in the articular cartilage of femoral head of the extracted fragment (Fig.3). The uncemented Spotorno total joint arthroplasty to both femoral and acetabular regions was performed, primarily to left hip joint with metal-backed expansion cup (Fig.4). Patient healed without a problem. No complications associated with union of femur fracture or prosthesis has occurred during follow-ups. It's detected in last

control of the patient at October 2001 that range of motion was close to normal except the internal rotation at right hip joint. And patient stated that she can do inside and outside activities without any restriction or assistance.

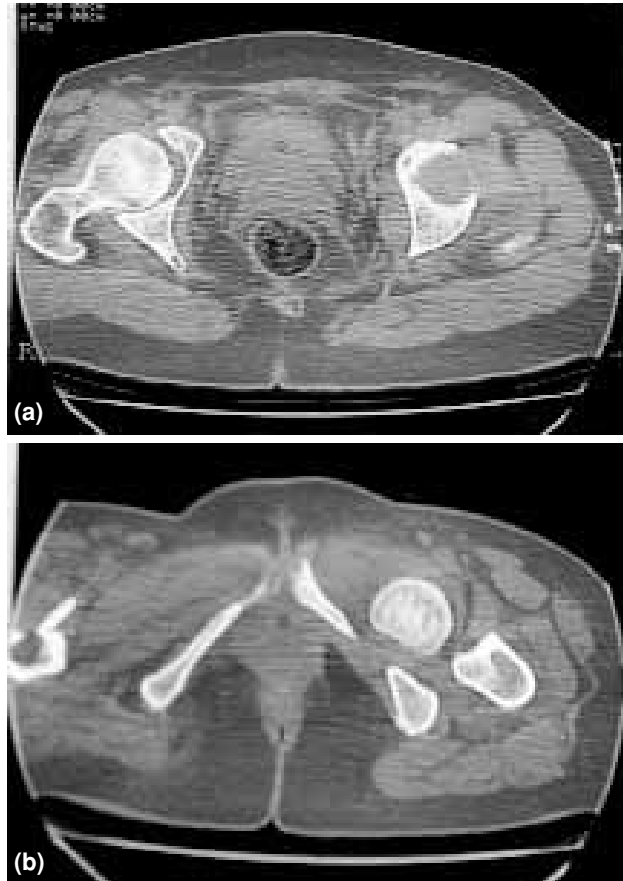

Figure 2. CT scans of obturator type anterior dislocation of the hip on the left side. (a) Empty acetabulum and (b) anteriorly displaced femoral head to the region near obturator foramen

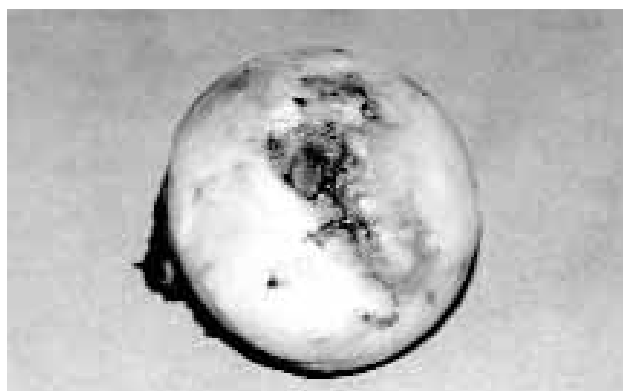

Figure 3. Cartilage defect of the femoral head extracted in the operation.

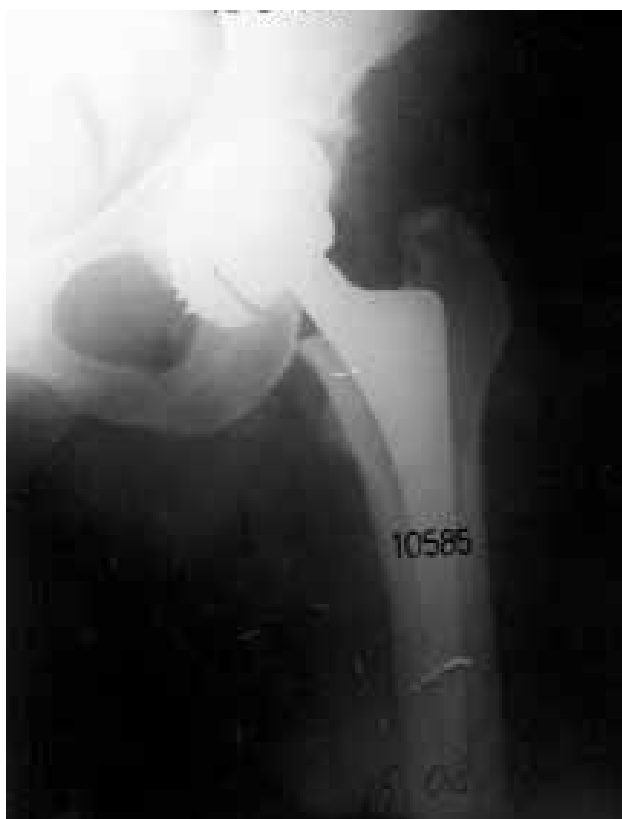

Figure 4. Spotorno type uncemented total hip arthroplasty applied to patient's left hip.

Discussion

Traumatic posterior dislocation of the hip associated with femoral head^[6-9] and neck^[1,7,10,11] fractures are rare injuries. Traumatic anterior dislocations of the hip associated with femoral head^[3,5,12-14] or neck^[1-4] fractures are less common injuries. Hart^[2] reported that he treated anteroinferior hip dislocation associated with femoral neck cases by Whitman type reconstruction procedure. Sadler and DiStefano^[4] once performed fixation with hip screw and plate after reduction in an anterior hip dislocation associated with ipsilateral basocervical femoral neck fracture case but avascular necrosis has occurred during the follow-up, so they applied Judet-Meyers type muscle pedicle grafting 12 weeks after the injury.

McClelland et al.^[3] reported that they applied collarless press-fit bipolar prosthesis to a case of obturator hip dislocation associated with femoral fracture of head and neck. Dummer and Sanzana^[1] reported that they applied uncemented total hip joint arthroplasty in a similar case with subcapital fracture. In our case there was also a subcapital fracture fragment, including head and neck, with defects on its cartilage covering the articular surface (Fig. 3) so, primarily we applied uncemented total hip arthroplasty.

References

1. Dummer RE, Sanzana ES. Hip dislocations associated with ipsilateral femoral neck fracture. *Int Orthop* 1999;(23): 353-4.
2. Hart VL. Fracture-dislocation of the hip. *J Bone Joint Surg* 1942;24:458-60.
3. McClelland SJ, Bauman PA, Medley CF Jr, Shelton ML. Obturator hip dislocation with ipsilateral fractures of the femoral head and femoral neck. A case report. *Clin Orthop* 1987;(224):164-8.
4. Sadler AH, DiStefano M. Anterior dislocation of the hip with ipsilateral basocervical fracture. A case report. *J Bone Joint Surg [Am]* 1985;67:326-9.
5. Epstein HC, Harvey JP Jr. Traumatic anterior dislocations of the hip: management and results. An analysis of fifty-five cases [Proceedings]. *J Bone Joint Surg [Am]* 1972;54:1561-2.
6. Epstein HC, Wiss DA, Cozen L. Posterior fracture dislocation of the hip with fractures of the femoral head. *Clin Orthop* 1985;(201):9-17.
7. Hougaard K, Thomsen PB. Traumatic posterior fracture-dislocation of the hip with fracture of the femoral head or neck, or both. *J Bone Joint Surg [Am]* 1988;70:233-9.
8. Pipkin G. Treatment of grade IV fracture-dislocation of the hip. *J Bone Joint Surg [Am]* 1957;39:1027-42.
9. Roeder LF Jr, DeLee JC. Femoral head fractures associated with posterior hip dislocation. *Clin Orthop* 1980;(147):121-30.
10. Klasen HJ, Binnendijk B. Fracture of the neck of the femur associated with posterior dislocation of the hip. *J Bone Joint Surg [Br]* 1984;66:45-8.
11. Meller Y, Tennenbaum Y, Torok G. Subcapital fracture of neck of femur with complete posterior dislocation of the hip. *J Trauma* 1982;22:327-9.
12. DeLee JC, Evans JA, Thomas J. Anterior dislocation of the hip and associated femoral-head fractures. *J Bone Joint Surg [Am]* 1980;62:960-4.
13. Richards BS, Howe DJ. Anterior perineal dislocation of the hip with fracture of the femoral head. A case report. *Clin Orthop* 1988;(228):194-201.
14. Scham SM, Fry LR. Traumatic anterior dislocation of the hip with fracture of the femoral head. A case report. *Clin Orthop* 1969;(62):133-5.