



Surgical treatment of scapular fractures

Skapula kırıklarında cerrahi tedavi

Irfan ESENKAYA

Inonu University Medical Faculty Orthopaedics and Traumatology Department, Malatya-TURKEY

Amaç: Cerrahi tedavi uygulanan skapula kırıklı olgulara ait bulgu ve sonuçları değerlendirmek.

Çalışma planı: Skapula kırıklı altı hasta (4 kadın, 2 erkek; ort. yaş 40; dağılım 25-59) açık redüksiyon ve internal fiksasyonla tedavi edildi. Tüm yaralanmalar trafik kazası sonrası oluşmuştu ve hepsinde eşlik eden yaralanmalar vardı. Dört hastada skapula boyun kırığı, iki hastada glenoid çukuru kapsayan eklem içi kırık saptandı. Skapula kırıklı hastaların üçünde aynı tarafta klavikula kırığı da vardı. Hastalar ortalama 27 ay (dağılım 18-38 ay) süreyle izlendi. Hastaların son değerlendirmesi, Herscovici ve ark.nın fonksiyonel değerlendirme yöntemine göre yapıldı.

Sonuçlar: Dört hastada mükemmel, bir hastada iyi, bir hastada orta sonuç alındı. Dört hastada hiç ağrı yoktu. Üç hasta yaralanma öncesindeki iş ve aktivitelerine geri döndü. Ev kadını olan iki hastanın iş yapabilme becerilerinde sorun yoktu. Dört hastada omuz abduksiyon veya fleksiyonu 120 derecenin üzerinde saptanırken, adale gücü "5" olarak belirlendi. Ameliyat sonrası komplikasyon oluşmadı.

Çıkarımlar: Skapula boynu kırığı ile aynı tarafta klavikula kırığı veya glenoid çukurda önemli derecede ayrışmaya neden olan eklem içi kırıklarda, eklem sertliğini, fonksiyon kaybını, ağrıyı ve oluşabilecek sakatlık halini önleyebilmek için açık redüksiyon ve yeterli sıkı tespit ile erken rehabilitasyon uygulanabilir.

Anahtar sözcükler: Klavikula/yaralanma; kırık fiksasyonu, internal/yöntem; kırık/cerrahi; multipl travma; skapula/yaralanma/cerrahi; omuz eklemi/radyografi.

Objectives: To evaluate the findings and results in patients who were treated surgically for scapular fractures.

Methods: Six patients (4 females, 2 males; mean age 40 years; range 25 to 59 years) with scapular fractures were treated by open reduction and internal fixation. All the fractures were caused by traffic accidents and all the patients had associated injuries. Four patients had scapular neck fractures, three of whom had accompanying ipsilateral clavicular fractures. In two patients, the fractures involved the glenoid fossa. The mean follow-up period was 27 months (range 18 to 38 months). Functional evaluations were made according to the scoring system described by Herscovici et al.

Results: The results were excellent in four patients, good in one, fair in one patient. Four patients had no pain. Three patients returned to preinjury jobs. Two patients who were housewives were able to do their housework. The range of movement was greater than 120 degrees in both abduction and flexion, and the muscle strength was 5 in four patients. No postoperative complications were encountered.

Conclusion: Open reduction and stabilization followed by early rehabilitation may be successful in preventing stiffness, pain, and disability in scapular neck fractures accompanied by ipsilateral clavicle fractures, or fractures involving the glenoid fossa and leading to significant displacement.

Key words: Clavicle/injuries; fracture fixation, internal/methods; fractures/surgery; multiple trauma; scapula/injuries/surgery; shoulder joint/radiography.

Scapula, which is an irregular bone, includes glenohumeral and acromioclavicular joints that create upper limb movements.^[1,2] Superficially and deeply located thick muscle layers almost embed

scapula and cover it to protect. It has the ability to absorb energy by its mobility on the chest wall.^[1-4] Besides the protective muscle structure; its joint capsule, glenohumeral, coracoclavicular, coracoacromi-

al, acromioclavicular and coracohumeral ligaments have role in stabilization.^[2,3,5-9] Because of these properties scapula fractures occur as a result of high energy injuries and seen relatively rare. It's reported that scapular fractures constitute 1% of all fractures and 5% of shoulder region fractures.^[4,10] Its incidence in all fractures was reported as 0.6% and 2.9% in other studies.^[5,11]

Scapular fractures commonly occur as a result of high energy injuries like traffic accidents.^[3-7,9,11-17] Adjacent regions like shoulder and chest region injuries or bone, soft tissue and visceral injuries of distant regions may be seen along with them.^[4-6,7,11-16,18-20] However, it is also reported that these fractures may occur as a result of low energy sport injuries.^[12,21,22]

First scientific studies about scapula fractures were published by Desault in 1805 and Cooper in 1807.^[13,14] The treatment of scapular fractures, started with the surgical approach of Longabaugh in 1924 as excision of triangular shaped fragment which is separated (displaced) from angulus inferior of scapula,^[1,10] and in following years it is progressed with conservative^[3-7,9,12-14,16,19,22,23] and surgical^[5,9,10,13-17,20,21,24-26] methods.

In this study, findings and results of six patients; had surgical treatments performed, because of displaced scapular glenoid fossa and scapular neck fractures and comminuted body fractures or associated clavicular fractures, and had routine controls done, are represented.

Patients and method

Six patients (4 female, 2 male; average age 40; range 25-59) with scapular fracture were treated by surgical methods between the dates April 1998 – June 2000. The cause of injury in all patients was traffic accident (4 patients were in car, 2 patients were pedestrian). Plain radiograms and CT scans were utilized for the diagnosis of fractures. Additional injuries, more than one in three cases, besides scapula were detected in all patients. Serial rib fractures in three patients (pneumothorax in one case and hemothorax in one case); ipsilateral diaphyseal fractures of humerus and ulna in one patient; clavicle fracture in one patient; sternal fracture and thoracic (T6) spine burst fracture in one patient were detected.

All the fractures were closed fractures. Classification was done according to the method defined by Hardegger et al.^[20] and adapted by Ada and Miller,^[14] and corresponding to anatomic location of the fracture line (Fig.1). According to this classification, there were four patients with type II scapular neck fractures (two type IIA, one type IIB and one type IIC) and two patients with type III intraarticular glenoidal fractures. According to the classification, which Ideberg defined and later modified,^[27] there was one patient with type III (transverse fracture of glenoidal fossa extending to superior edge "margo superior" of scapula) and one patient with type IV (fracture starting from glenoidal fossa extending to medial edge "margo medialis" of scapula) glenoidal cavity fractures. There were four patients who had combined injury with scapular neck fracture, and unisolated fracture in one patient with glenoidal fossa fracture, related to type IV scapular comminuted body fractures. Detected ipsilateral clavicular fractures besides scapular fractures are evaluated as floating shoulder^[5-9,15-20] in three patients.

All patients treated by the same surgeon. Indications, like scapular neck fracture associated with ipsilateral clavicular and comminuted body fractures, angulation of scapular neck fracture more than 40°, medial displacement of glenoidal surface

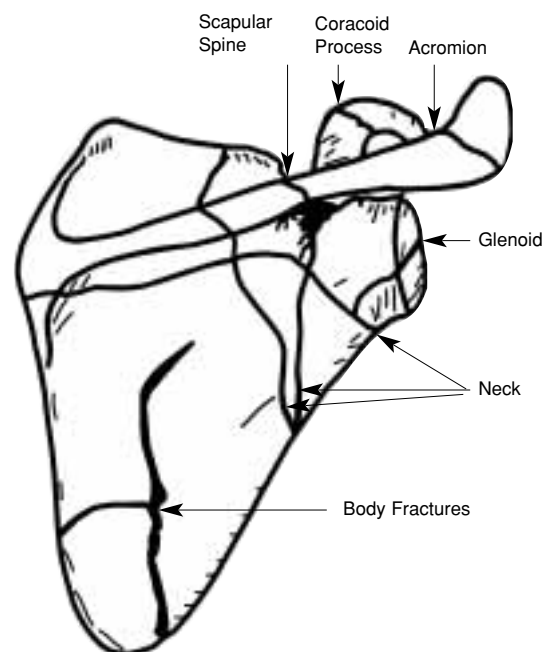


Figure 1. Anatomic classification of the scapular fractures.^[14]

for 1cm or more with prominent stepping on its articular surface^[1,9,14,15,20,21,24,27] were considered in surgical application. Anterior deltopectoral incision^[1] was performed for surgical reduction and fixation of fractures in one patient with intraarticular fracture, posterior Judet incision^[14] was used in other five patients. A reconstruction plate was applied to one of the two patients having intraarticular glenoidal fracture and two reconstruction plates were applied to the other. In the patients with scapular neck and comminuted body fractures, considering the condition of the fracture, 2-4 reconstruction plates, which were compatible with minicortical screw and could be formed, were applied for fixation. Fixations of clavicular fractures were done in two of three patients with clavicular fractures. And the third patient had vertebral fracture associated with scapu-

lar fracture consequently both operations performed in the same session and operation time was extended so fixation of clavicular fracture could not be performed. Examples of the patients are shown in figures 2 and 3.

A sling was used in all patients in postoperative period. According to associating injury (except the patient having ipsilateral humeral and ulnar fractures), after taking out the drains, patients have started elbow movements and pendular exercises if they can (except the patients operated for vertebral fracture and patients who applied thoracic drain to prevent hemothorax/pneumothorax). A sling was used for six weeks in five patients and ten weeks in patients with ipsilateral humeral and ulnar fractures. Postoperative controls are made periodically and

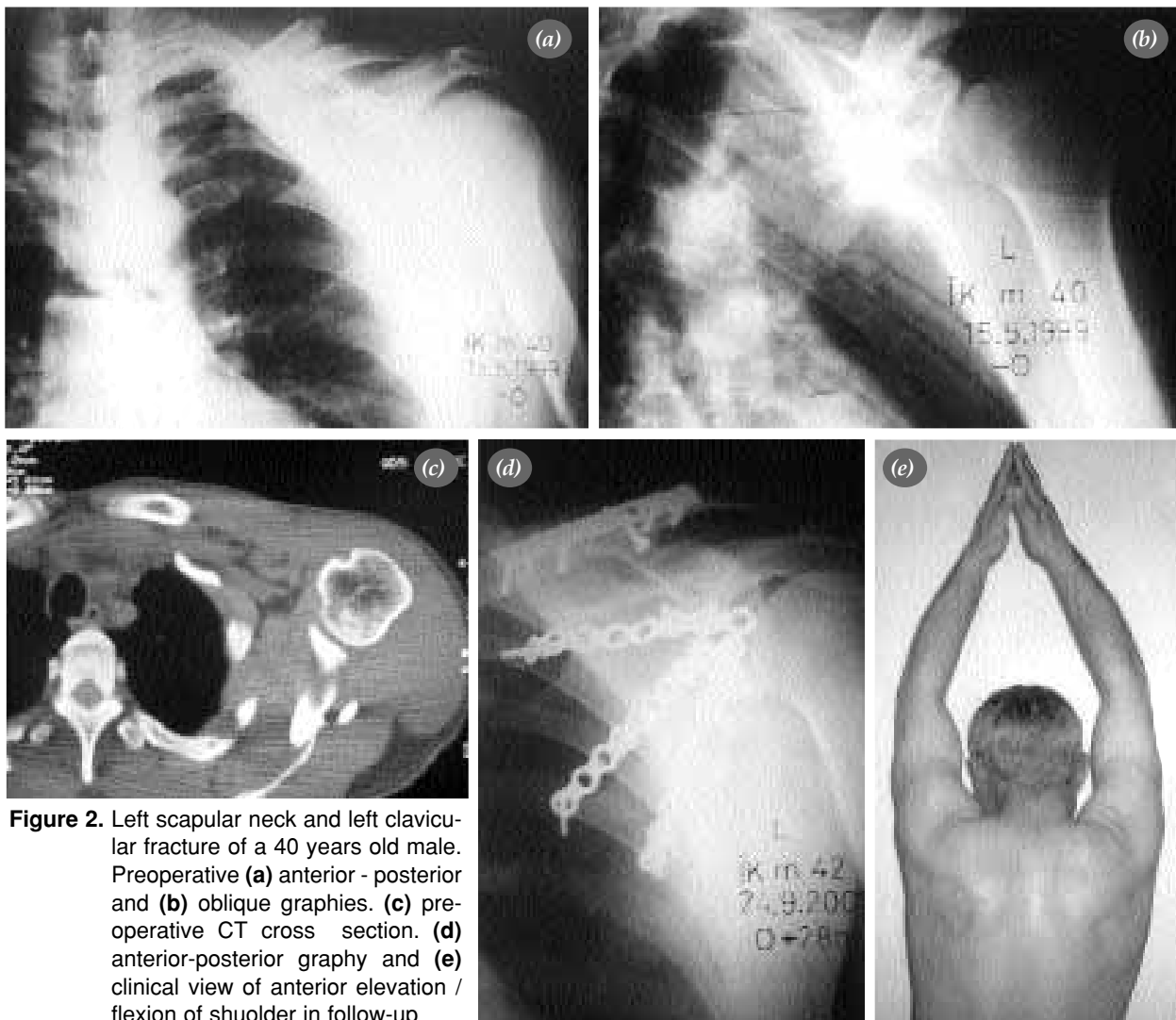


Figure 2. Left scapular neck and left clavicular fracture of a 40 years old male. Preoperative (a) anterior - posterior and (b) oblique graphies. (c) preoperative CT cross section. (d) anterior-posterior graphy and (e) clinical view of anterior elevation / flexion of shuolder in follow-up

Table 1. Findings and results of six patients

No	Age	Operation date	Side	Additional injury	Pain	Back to job	Anterior elevation (flexion)-abduction	Muscle strength	Result
1/Male	34	April	1998 Right	Right clavicular	None	+	160-130	5	Excellent
2/Female	36	December	1998 Righ	Bilateral serial costal fracture, pneumothorax	Minimal	Similar job	120-110	4	Good
3/Female	59	December	1998 Right	Right humerus, rihgt ulnar fracture	Moderate	Partly	90-90	3-4	Fair
4/Male	40	May	1999 Left	Left clavicular fracture	None	+	170-135	5	Excellent
5/Female	25	September	1999 Rihgt	Serial costal fracture	None	Similar job	160-130	5	Excellent
6/Female	45	June	2000 Left	Left clavicular fracture serial costal fracture, homothorax sternal fracture, T6 burst fracture	None	+	150-125	5	Excellent

followed up for average 27 months (range 18-38 months). In the last follow-up of patients, they were evaluated by a functional scoring system developed by Herscovici et al.^[5] which assesses subjective (pain, quality/style of life) and physical examination (abduction or flexion range of motion, muscle strength) results numerically. In this system the patient categorized for each 4 points (13-16 excellent, 9-12 good, 5-8 moderate/fair and 1-4 poor).

Results

There were no complications like neurovascular injury, infections, hematoma and problems of wound healing or fracture union in any patient in postoperative period. Four patients were excellent, one was good and one was moderate according to functional scoring system. Four patients had no pain complaint. Three patients (two farmers and a health officer) have started the jobs they were doing before the injury. Two patients (housewives) had no significant decrease in ability to do works and they were not complaining about their general condition. A patient with moderate pain and using analgesics sometimes was only able to do his daily needs. Range of motions were evaluated as, flexion movements of 170° in one patient, 160° in two patients, 150° in one patient, 120° in one patient, 90° in one patient and abduction movements of 135° in one patient, 130° in two patients, 125° in one patient, 110° in one patient, 90° in one patient. Muscle strength was "5" in four patients. But a decrease in muscle strength especially external rotation against resistance was detected (4 in patient with good result, 3 in patient with moderate result and 4 in other movements) in two patients evaluated as good and moderate. No significant arthrosis was detected in glenohumeral joint of

any case except a joint space narrowing in a patient, in compared radiological evaluations. Findings and results of the patients are shown in table 1.

Discussion

Other vital structures and extremity injuries associate with scapular fractures in ratio of 27%-98.2% in injuries of high energy traumas.^[4,6,11-14,16,19,20] Scapular fractures may be omitted because of life threatening other injuries.^[4,11,13,17,18,20]

There is no certain alorhytm that guides surgical treatment of scapular fractures. Conservative^[3-7,9,12-14,16,19,22,23] and surgical^[5,9,10,13-17,20,21,24-26] methods are recommended according to location, type, displacement degree and associating injury of the fracture.

Thick and large muscle masses surrounding scapular body prevents excessive displacement of fracture fragments in scapular body fractures. And these fractures can be treated conservatively.^[3,4,12-14,20,22] But lateral margin of the body may be displaced and sharp spike of fragment may enter the joint capsule in burst type comminuted fractures. Surgical reduction and fixation, yet extraction / osteotomy of this fragment may be needed not to damage articular function.^[20]

Conservative treatment is performed in glenoid rim fractures if the displacement is minor. It's accepted that fragment displacement over 10 mm or fractures involving anterior 1/4 of or posterior 1/3 of glenoidal fossa causes instability.^[27]

Conservative treatment is performed to the without displacement fractures of glenoidal fossa.^[1,20,26,27] Open reduction and fixation is performed for integri-

ty and congruity of articular surface when stepping is 3mm,^[1] 4mm,^[24] 5mm^[27] or more, or a displacement between the fragments is seen.^[1,10,14,20,24,26,27] Surgical treatment is performed also in glenoidal fractures associated with subluxation.^[13,27]

Long head of triceps muscle, inserting to infra-glenoid tubercle, significantly displaces fracture fragment distally and laterally in fractures of the anatomical neck (collum anatomicum fractures). Open reduction and stabilization is recommended in conditions where the lateral traction is not enough.^[20]

When less displaced fractures of the surgical neck (collum chirurgicum fractures) are treated by conservative methods,^[1,3,4,20] lateral angle “angulus lateralis” of scapula which also includes glenoid may be severely displaced. The amount of displacement is related with the injuries of associating clavicular fracture and coracoclavicular ligament, or both. When suspensory and stabilising functions of these structures are lost the neck fragment becomes unstable and displace medially and distally by the effects of muscle force and weight of the arm.

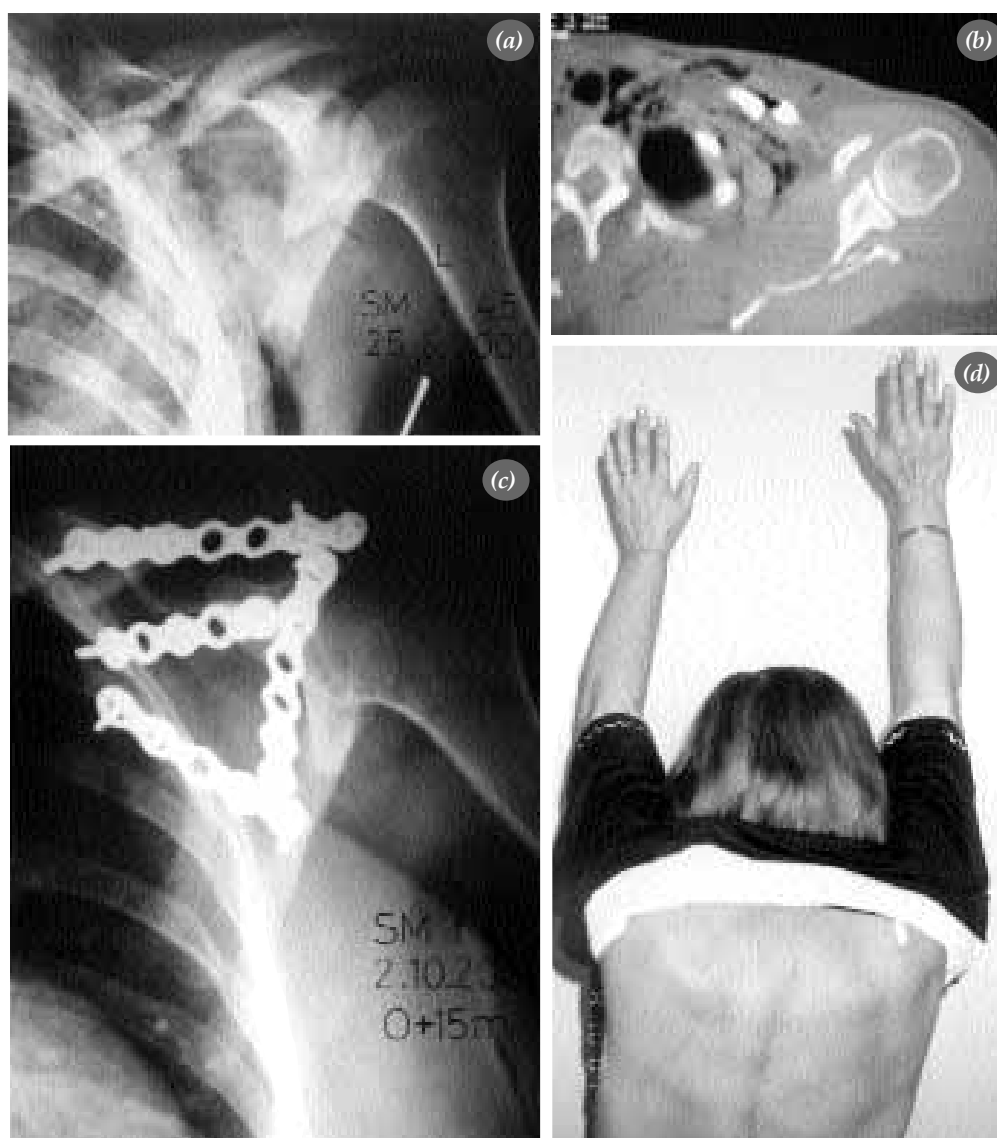

Figure 3. Left scapular neck and left clavicular fractures of the 45 year old female. There were T6 vertebral burst fracture, sternal fracture, ipsilateral serial costal fractures and hemothorax as additional injuries. Preoperative (a) anterior-posterior graphy and (b) CT cross section (c) anterior-posterior graphy and (d) clinical view of anterior elevation/flexion of shoulder in follow-up.

Surgical^[1,5,9,15,20] or conservative^[6,7,9] treatment is recommended to regain normal functions and anatomic relations. Ada and Miller^[14] suggested surgical treatment in situations like scapular neck fractures over 40 degrees of angulation or displacement of glenoidal surface 1 cm and over medially.

Before the treatment of the rotator cuff injury in sportsman especially, the hemorrhage inside the muscles supraspinatus, infraspinatus, subscapularis, as Neviaser described, should be differentiated from the pseudorupture mimicking rotator cuff.^[13,14,22]

Lindholm and Leven^[3] stated that they got normal shoulder movements in 19 patients (scapular body fractures in 13 patients and some of them were comminuted, scapular neck fractures in 6 patients and one with intraarticular extension) after treatment with conservative methods and none of the patient had pain complaint, except one. McGinnis and Denton^[4] noted that they had 62% excellent, 11% good, 8% fair and 11% poor results in routinely controlled 26 of 39 patients who had conservative treatment; and 8% of the cases were not evaluated because of their plexus brachialis injury and persisting comatose status. They also stated that two of three patients with poor results had head trauma and other visceral injuries.^[4] Wilber and Evans^[13] reported that they had 31 good, three fair, two poor and four unknown results in 38 conservatively and two surgically treated 40 patients. As the results of these patients clarified, it is seen that they had good results in scapular body, neck and spine fractures; fair results in glenoid and acromion fractures; poor results in glenoid and coracoid fractures. They had good results in patient with scapular body fracture and poor results in patient with coracoid process fracture after performing surgical treatment. Fixation was done when the arm was in adduction and a regular exercise program was not applied to patients with poor results.^[13] Ada and Miller^[14] evaluated 24 patients who had scapular neck, intraarticular and comminuted scapular spine fractures, in 113 patients, and detected weakness in abduction type activities and nocturnal subacromial pain in patients with displaced scapular neck fractures; decreased or painful range of motion in patients with intraarticular fractures; weakness in abduction type activities, nocturnal subacromial pain and crepitations in scapulothoracic region in patients with comminuted

scapular spine fractures. Authors reported that they had excellent results with surgical treatment in eight patients with scapular neck angulation over 40 degrees or displacement of glenoidal surface 1 cm and over medially.^[14] Hardegger et al.^[20] had excellent results in 21, good results in five, fair results in five and poor results in two patients, in long-term followed-up 33 of surgically treated 37 patients. And according to fracture types commonly glenoid rim fractures (11 patients) and glenoidal fossa fractures (12 patients), intraarticular fractures as combined fractures (5 patients) were seen.^[20]

In our clinic, conservative treatment was performed to the patients with nondisplaced fractures and stable glenoid articular continuity; internal fixation with surgical reduction applied to six patients with displaced, unstable glenoid articular continuity or additional ipsilateral clavicular fractures, by the same surgeon. We did not perform conservative treatment to the patients having similar features, attended to our clinic, consequently only literature data was presented without comparison of conservative treatment methods or their results.

Herscovici et al.^[5] applied surgical treatment by fixation of clavicle only, in seven of nine patients with ipsilateral scapular neck fracture and clavicular fracture, and they had excellent results in each. They had good result in one of the two patients who had conservative treatment and poor result in the other. And serious visceral injuries were present in two patients who had conservative treatment.^[5] Ramos et al.^[6] had 84.6% excellent, 7.7% good and 7.7% fair results in conservatively treated 13 patients with ipsilateral scapular and clavicular fractures. In a biomechanical study on shoulders of 12 fresh-frozen human cadaver, Williams et al. reported that ipsilateral scapular neck fractures and clavicular fractures does not always cause floating shoulder in the absence of coracoacromial and acromioclavicular capsular ligaments; consequently surgical fixation is not always necessary in ipsilateral scapular neck and clavicular fractures.^[8] Egol et al.^[9] stated that they applied conservative treatment to 12 and surgical treatment to seven of 19 patients with ipsilateral scapular neck fracture and clavicular fracture or acromioclavicular dislocation; had successful results in both groups; eventually they do not recommend surgical treatment in every patient, treatment should

be planned according to the features of patient. Leung and Lam^[15] applied internal fixation for both scapular and clavicular fractures to 15 patient with ipsilateral scapular and clavicular fractures and had excellent results in eight patients, good results in six patients and fair result in one patient. The authors attributed their successful results to fixation of two fractures by nontraumatic surgical approach with separating fewer muscles, ensuring the shoulder stability and thus performing postoperative rehabilitation with ease.^[15] We had excellent results, according to classification of Herscovici et al.,^[5] in two patients whom we applied internal fixation to clavicular fracture associated with scapular fracture, and in other patient that we did not performed operation. In patient who didn't have the operation was healed by putting fracture ends 1 cm over another (overriding), however got union without any problem. We think that, to start exercises in early postoperative period in patients with additional extremity injuries especially, operating both scapular and clavicular fractures increases the stabilization. However, as in our patient groups, in patients with ipsilateral upper extremity fractures or in patients that we can not ambulate early just like the one with vertebral (spinal) fracture, early active movement is not always started. According to our experiences shoulder range of motion can be kept by in bed, assisted passive motions at early phase.

We evaluated the results of four patients as excellent, one patient as good and one patient as fair in their last control. We applied plates, by subperiosteally stripping infraspinatus muscle from scapula, to five patients, whom we performed posterior incision according to Judet^[14] technique. And we had excellent results in three patients, good result in one patient and fair in the other. We detected weakness especially in abduction and external rotation movements of two patients with good and fair results. There was glenoidal fossa fracture extending to medial border "margo medialis" of scapula, right along with ipsilateral humerus and ulnar body fractures in patient with fair result. Although the operation and fixation of all three fractures were done, we focused on shoulder movements (except pendular exercises) after 8th week because of the other fractures. We believe that, in posterior approaches, especially in fixations of glenoidal fractures and body fractures near glenoid, not to cause any weakness in

external rotation and abduction movements of the patients, approaching between the infraspinatus and teres minor muscles should be kept in mind which causes less damage to the surrounding muscle tissues, as recommended by Klassen and Cofield^[1] and Kavanagh et al.^[24] Computerized tomography and 3D computerized tomography can be utilized in addition to plain radiograms in preoperative evaluation and preparation phases. Different positions of imaging may be needed, to see the details of fracture and to detect the associated injuries like clavicular fracture, in plain radiograms, especially the ones taken to small cassettes (Figure 2a, b) or, as most appropriate solution; large size cassettes can be used. Magnetic resonance imaging can be utilized to evaluate soft tissue pathologies like rotator cuff injury, especially in sportsman and young people.

Patients must be examined carefully, for possible associated injuries in scapular fractures occurring as a result of high energy trauma. Patients must be observed for possible pulmonary injuries, hemothorax and pneumothorax even in isolated scapular fractures.

Pre-injury functions can be regained by open reduction and adequate rigid fixation with early mobilization in intraarticular displaced glenoidal fractures and, clavicular and comminuted body fractures associated with scapular neck fractures of sportsmen, young people and active people especially.

References

1. Klassen JF, Cofield RH. Surgical management of scapular fractures. *Oper Tech Orthop* 1994;4:58-63.
2. Kibler WB. The role of the scapula in athletic shoulder function. *Am J Sports Med* 1998;26:325-37.
3. Lindholm A, Leven H. Prognosis in fractures of the body and neck of the scapula. A follow-up study. *Acta Chir Scand* 1974;140:33-6.
4. McGinnis M, Denton JR. Fractures of the scapula: a retrospective study of 40 fractured scapulae. *J Trauma* 1989;29:1488-93.
5. Herscovici D Jr, Fiennes AG, Allgower M, Ruedi TP. The floating shoulder: ipsilateral clavicle and scapular neck fractures. *J Bone Joint Surg [Br]* 1992;74:362-4.
6. Ramos L, Mencia R, Alonso A, Ferrandez L. Conservative treatment of ipsilateral fractures of the scapula and clavicle. *J Trauma* 1997;42:239-42.
7. Edwards SG, Whittle AP, Wood GW 2nd. Nonoperative treatment of ipsilateral fractures of the scapula and clavicle. *J Bone Joint Surg [Am]* 2000;82:774-80.
8. Williams GR Jr, Naranja J, Klimkiewicz J, Karduna A, Iannotti JP, Ramsey M. The floating shoulder: a biomechanical

- ical basis for classification and management. *J Bone Joint Surg [Am]* 2001;83:1182-7.
9. Egol KA, Connor PM, Karunakar MA, Sims SH, Bosse MJ, Kellam JF. The floating shoulder: clinical and functional results. *J Bone Joint Surg [Am]* 2001;83:1188-94.
 10. Fischer WR. Fracture of the scapula requiring open reduction. *J Bone Joint Surg* 1939;21:459-61.
 11. Thompson DA, Flynn TC, Miller PW, Fischer RP. The significance of scapular fractures. *J Trauma* 1985;25:974-7.
 12. Imatani RJ. Fractures of the scapula: a review of 53 fractures. *J Trauma* 1975;15:473-8.
 13. Wilber MC, Evans EB. Fractures of the scapula. An analysis of forty cases and a review of the literature. *J Bone Joint Surg [Am]* 1977;59:358-62.
 14. Ada JR, Miller ME. Scapular fractures. Analysis of 113 cases. *Clin Orthop* 1991;(269):174-80.
 15. Leung KS, Lam TP. Open reduction and internal fixation of ipsilateral fractures of the scapular neck and clavicle. *J Bone Joint Surg [Am]* 1993;75:1015-8.
 16. Tarhan O, Arkan C, Tolun U, Buluç L. Skapula kırıkları. *Artroplastik Artroskopik Cerrahi* 2000;11:42-4.
 17. Martin SD, Weiland AJ. Missed scapular fracture after trauma. A case report and a 23-year follow-up report. *Clin Orthop* 1994;(299):259-62.
 18. Harris RD, Harris JH Jr. The prevalence and significance of missed scapular fractures in blunt chest trauma. *AJR Am J Roentgenol* 1988;151:747-50.
 19. McLennan JG, Ungersma J. Pneumothorax complicating fracture of the scapula. *J Bone Joint Surg [Am]* 1982;64:598-9.
 20. Hardegger FH, Simpson LA, Weber BG. The operative treatment of scapular fractures. *J Bone Joint Surg [Br]* 1984;66:725-31.
 21. Aulicino PL, Reinert C, Kornberg M, Williamson S. Displaced intra-articular glenoid fractures treated by open reduction and internal fixation. *J Trauma* 1986;26:1137-41.
 22. Cain TE, Hamilton WP. Scapular fractures in professional football players. *Am J Sports Med* 1992;20:363-5.
 23. Tezer M, Kabukçuoğlu YS, Koçkesen TÇ, Ordueri M, Kuzgun Ü. Çocuk skapula cisim kırığı (Parsiyel skapulotorasik dissosiasyon) (Bir olgu sunumu). *Acta Orthop Trauma Turc* 1998;32:256-9.
 24. Kavanagh BF, Bradway JK, Cofield RH. Open reduction and internal fixation of displaced intra-articular fractures of the glenoid fossa. *J Bone Joint Surg [Am]* 1993;75:479-84.
 25. Gupta R, Sher J, Williams GR Jr, Iannotti JP. Non-union of the scapular body. A case report. *J Bone Joint Surg [Am]* 1998;80:428-30.
 26. Boz Ü, Yeşiltaş Y, Can Ö. Skapulanın eklem içi kaymış kırıklarında uyguladığımız cerrahi tedavi sonuçlarımız. In: Ege R, editör. XVI. Milli Türk Ortopedi ve Travmatoloji Kongre Kitabı; 3-7 Kasım 1999; Antalya, Turkey. Ankara: Sargin; 1999. s. 384-7.
 27. Goss TP. Fractures of the glenoid cavity. *J Bone Joint Surg [Am]* 1992;74:299-305.