



Reconstruction of shoulder abduction and external rotation in obstetric brachial plexus palsy

Doğumsal brakial pleksus felcinde omuz abdüksiyon ve eksternal rotasyonunun rekonstrüksiyonu

Türker ÖZKAN,¹ Atakan AYDIN,¹ Defne ÖNEL,² Safiye ÖZKAN¹

¹Istanbul University Istanbul Medical Faculty Plastic and Reconstructive Surgery Department, Hand surgery division; ²Private Doctor

Amaç: Doğumsal brakial pleksus paralizisine bağlı omuzda internal rotasyon kontraktürü gelişmiş olgularda subskapularis ve pektoralis majör kaslarının serbestleştirilmesi ve latissimus dorsi/teres majör kaslarının rotator manşete transferinin sonuçları değerlendirildi.

Çalışma planı: Yetmiş hastada (44 erkek, 26 kız; ort. yaş 7.6; dağılım 2-16) latissimus dorsi/teres majör kaslarının rotator manşete transferi yapıldı. On dokuz olguda C₅-C₆, 16'sında C₅-C₇, 35'inde C₅-T₁ spinal köklerinde hasar vardı. Kırk altı olguda subskapularis kasının skapula ön yüzünden serbestleştirilmesi, 55 olguda pektoralis majör kasının parsiyel tenotomi ile uzatılması uygulandı. Glenohumeral eklem ön-arka direkt grafi ve aksiyel manyetik rezonans görüntüleri ile değerlendirildi. Waters ve Peljovich sınıflamasına göre tip I ile tip II'ye uyan deformiteleri olan olgulara ameliyat uygulandı. Hastalar ameliyat öncesi ve sonrası ölçülen eklem hareket açıklığı değerleri ve Mallet skorlaması ile değerlendirildi. Ortalama izlem süresi 37.9 ay (dağılım 24-64 ay) idi.

Sonuçlar: Ameliyat sonrasında aktif abdüksiyon ve eksternal rotasyon açıları ortalamaları sırasıyla 132.6° (dağılım 90-170°; ortalama artış 60.3°) ve 81.1° (dağılım 30°-100°; ortalama artış 58.7°) ölçüldü. Ameliyat sonrası Mallet skoru ortalamaları abdüksiyon ve eksternal rotasyonda 3.9; eli başa, ağza ve sırta götürmede sırasıyla 3.7, 3.4 ve 2.5 bulundu. İzlem döneminde ciddi bir komplikasyonla karşılaşmadık.

Çıkarımlar: Omuz hareketlerinin restorasyonu için uyguladığımız rekonstrüksiyonlar, hafif glenohumeral eklem deformitesi olan hastalarda tatmin edici düzeyde omuz abdüksiyonu ve eksternal rotasyon sağlamaktadır.

Anahtar sözcükler: Doğum yaralanmaları/cerrahi/radyografi; brakial pleksus/yaralanma/cerrahi; çocuk; parali, doğumsal/tanı/sınıflama/cerrahi; pektoralis kası/cerrahi, eklem hareket açıklığı; rotator manşet/cerrahi; omuz eklemi/cerrahi; tendon transferi/yöntem.

Objectives: We evaluated the results of the subscapularis and pectoralis major muscle releases and the transfer of latissimus dorsi/teres major muscles to the rotator cuff in patients with internal rotation contractures due to obstetric brachial plexus palsy.

Methods: Seventy patients (44 boys, 26 girls; mean age 7.6 years; range 2 to 16 years) underwent transfer of the latissimus dorsi/teres major muscles to the rotator cuff. Spinal root involvement was at C₅-C₆ in 19 patients, at C₅-C₇ in 16 patients, and at C₅-T₁ in 35 patients. In 46 patients, the subscapularis muscle was released from the anterior surface of the scapula, and in 55 patients, the pectoralis major muscle was released by fractional tenotomy. The glenohumeral joint was evaluated by anteroposterior direct graphics and axial magnetic resonance scans. According to the Waters-Peljovich grading system, all the patients had type I or type II deformities. Pre- and postoperative range of motion values and Mallet scores were compared. The mean follow-up period was 37.9 months (range 24 to 64 months).

Results: The mean shoulder abduction increased to 132.6° (range 90° to 170°; mean gain 60.3°) and external rotation increased to 81.1° (range 30° to 100°; mean gain 58.7°). The mean postoperative Mallet scores for global abduction and external rotation were 3.9; hand-to-head, to-mouth, and to-back scores were 3.7, 3.4, and 2.5, respectively. No serious complications were seen during the follow-up period.

Conclusion: The results of reconstruction techniques employed in our study show satisfactory increases in shoulder abduction and external rotation in patients with a minimal glenohumeral deformity.

Key words: Birth injuries/surgery/radiography; brachial plexus/injuries/surgery; child; paralysis, obstetric/diagnosis/classification/surgery; pectoralis muscles/surgery; range of motion; rotator cuff/surgery; shoulder joint/surgery; tendon transfer/methods.

Correspondance to: Dr. Türker Özkan, Vali Konağı Cad., Sezai Selek Sok., Akil Apt., No: 2/2, D: 5, 34365 Nişantaşı, İstanbul.

Phone: 0212 - 246 52 53 Fax: 0212 - 246 61 24 e-mail: drozkan@prizma.net.tr

Received: 20.02.2004 Accepted: 25.06.2004

A part of this study was presented at "Inaugural Congress of the World Society for Reconstructive Microsurgery" (29 October-3 November 2001, Taipei, Taiwan).

Obstetrical brachial plexus palsy (OBPP) is one of the most severe birth complications.

Although most patients show a favorable outcome after intense physical therapy in the early period, as the age advances approximately 10 % of the patients develop severe sequela, including contractures and bone deformities that result from paralysis.^(1,2)

The surgical approaches can generally be classified in two groups. The first is the primary nerve repair, performed before 18 months of age, and the latter group includes palliative procedures such as muscle releases, tendon transfers, and bone procedures like rotation osteotomy of the humerus performed at older ages.⁽³⁻⁶⁾ Despite the fact that primary nerve surgery has become more common in our country, as in others, there exists still many patients who have lost the chance to be treated in this way.

In our study, the results of 70 patients who underwent release of subscapular and pectoralis major muscles with concomitant transfer of the latissimus dorsi / teres major transfer to the rotator cuff^(2,7) for the correction of internal rotation contracture of the shoulder, are evaluated.

Patients and Methods

Between 1998-2002, 70 patients with OBPP (44 male, 26 female; mean age 7.6, range 2-16) were operated due to contractures that developed in the shoulder. 32 of these, underwent further surgery for the treatment of elbow contractures, forearm supination deformity and for the reconstruction of wrist and finger functions.

History revealed that all patients were born with cephalic presentation. 39 patients had right sided involvement while 31 had left. Most patients were born from multiparous mothers, and the mean birth weight was 4532 (range 2500-6600g). Mean gestational age at birth ranged from 38-42 weeks.

Nineteen patients had C₅-C₆ involvements, 16 had C₅-C₆-C₇ spinal roots and 35 had total brachial plexus involvement. Transfer of the latissimus dorsi and teres major tendons to the rotator cuff was carried out in all patients. Also, subscapular muscle was released in 46 patients and pectoralis major muscle was released in 55.

When associated injuries are considered, one patient had a fracture of the clavicle, two patients had humerus fracture and one had fracture of the scapula. One patient had injury to the sternocleidomastoid muscle and six patients had history of Horner's syndrome.

All patients had received a house program and regular rehabilitation protocol since birth. Bilateral anteroposterior x rays of the shoulders in adduction and 90 degrees abduction were used for the preoperative evaluation. The glenohumeral joint deformities were evaluated with magnetic resonance imaging of the shoulder joint in axial plane. Those cases who had deformities consistent with type I and type II deformity according to the Waters and Peljovich classification (6) underwent release and tendon transfer (Figure 1 and 2), and patients with more severe deformities or posterior shoulder luxation were not taken into the study (Table 1). In the preoperative evaluation, active and passive range of motion and motor functions were evaluated with Mallet classification (6) (Figure 3).

After the operation, a cast that kept the shoulder in 90° abduction and complete external rotation was applied for six weeks, which was subsequently replaced for four weeks with a thermo-plastic splint that was prepared preoperatively. The exercise program started on the postoperative sixth to eight weeks with the gravity eliminated, and without allowing antagonist movement. On the eighth to tenth weeks, the splint was applied

Table 1 : Radiographic classification of glenohumeral deformity (Waters and Peljovich).

Type I	Normal glenoid (<5° retroversion difference versus contralateral normal) Tip II Hafif deformite (5 dereceden fazla retroversiyon farkı)
Type II	Minimal deformity (>5° retroversion difference)
Type III	Moderate deformity (posterior humeral head subluxation)
Type IV	Severe deformity (posterior humeral head subluxation with false glenoid)
Type V	Severe flattening of humeral head and glenoid +/- complete dislocation
Type VI	Infantile glenohumeral dislocation
Type VII	Proximal humeral growth arrest

only at nighttime, and mild strengthening exercises with light functional activities were allowed. After the twelfth week, stretching exercises started and the patient was asked to use the extremity in all daily activities. The patients were followed with regular intervals, during which ROM and Mallet score measurements were made. Mean follow-up duration was 37.9 months (range 24-64 months). The patients were divided into four groups according to age (2-4, 5-7, 8-10, and 11-16 years) and into two groups according to brachial plexus involvement (C₅, C₆ and /or C₇ and C₅-T₁) and evaluated statistically with analysis of variance (ANOVA). $p < 0.05$ was considered to be significant. The latissimus dorsi and teres major muscles to be transferred were required to have a power of 4 or 5 according to the British Medical Research Council muscle power classification.

Surgical technique

The patients were placed on the operating table in supine position. The latissimus dorsi and teres major muscles were reached through a zig zag incision placed on the posterior axillary line (Figure 4a). The united tendon of these muscles, conjoined tendon, was exposed. Both muscles were freed from their surrounding attachments, taking care to preserve the pedicle. Generous dissection of the muscles were made to enable the conjoined tendon to reach the rotator cuff easily. The conjoined tendon was separated from its insertion site on the humerus and prepared for transfer (Figure 4b).

The shoulder was brought into passive abduction and external rotation, and the tension of the subscapularis and pectoralis major muscles was controlled. In cases that had tightness of these structures, it was decided to release the pectoralis major

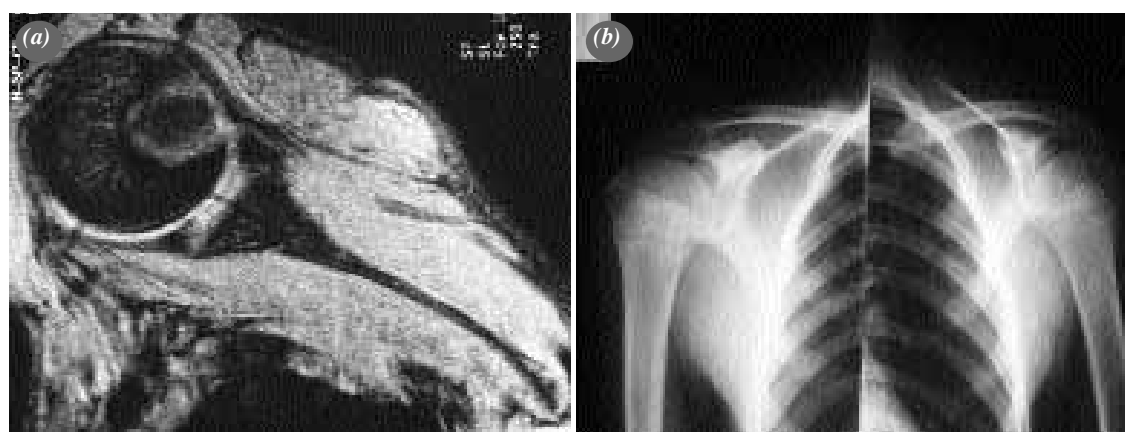

Figure 1. Left sided birth palsy with type I deformity according to Waters and Peljovich classification. **a)**magnetic resonance and **b)**direct x ray images (normal glenoid, retroversion difference less than 5 degrees)

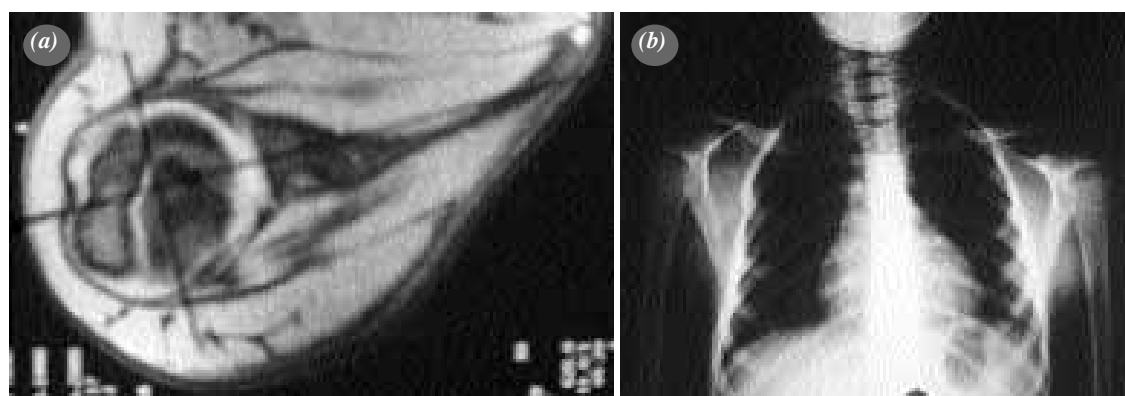

Figure 2. Left sided birth palsy with type II deformity according to Waters and Peljovich classification. **a)**magnetic resonance and **b)**direct x ray images (mild deformity of the humeral head, retroversion difference more than 5 degrees)

and / or subscapular muscles. The subscapular muscle was dissected off the anterior surface of the scapula (Fig 4c). During this release, while entry to the subperiosteal plane is made, it is important to avoid injury to the pedicles of the muscles that are going to be transferred as well as avoiding excessive medial dissection, which may result in the separation of the serratus muscle from its insertion site. The tendon of the pectoralis major muscle which resulted in tension was exposed through a zig zag incision in the anterior axillary line and release was made.

A third incision was made in the posterior deltoid region and the site on the major tubercle of the humerus which the rotator muscles attached was marked. The anchor was fixed to the humerus at this marked point (Figure 4d,e) and the 2/0 ethibond polyester suture material at the end of the anchor was passed by blunt dissection without injuring the axillary nerve through the tunnel, and this suture was

taken out of the posterior incision, which included the conjoined tendon. After the suture material is woven into the conjoined tendon, the tendon was passed through the same tunnel with the aid of the suture.

The knot was tied with the arm in 90° abduction and full external rotation. The tendon was also sutured to the rotator cuff, especially the infraspinatus muscle tendon. After the surgical incisions were closed, the cast was applied without changing the shoulder position.

Results

Preoperative mean abduction was 72.7° (range 10-170°), mean external rotation 22.4° (range 0-80°); mean Mallet scores for abduction and external rotation were 3 and 2.5, respectively, hand to head, to back and to mouth were found to be 2.3, 2.6, and 2.6, respectively.

Mean active abduction degree following surgery increased by 60.3° and reached 132.6° (range 90-170°). Mean increase in abduction value was 83.4%.

Mean external rotation value increased by a mean of 58.7° and reached 81.1° (range 30-100°). Mean increase in external rotation was 262.1%.

Postoperative values for Mallet scores in abduction and external rotation was 3.9, in hand to head was 3.7, and hand to back reached 2.5

When patients were classified according to age groups and brachial plexus involvement was classified into two subgroups as C₅-C₆ and / or C₇ and C₅-T₁, it was seen that the increases in abduction and external rotation as well as postoperative results were close and there were no significant differences (ANOVA, f=1.286, p>0.05 for abduction; f=0.92, p>0.05 for external rotation). Pre and postoperative views of two patients are shown in figures 5 and 6.

No serious complications occurred except for wound dehiscence in three patients that healed without problems, and abrasions on the thoracic wall that were caused by the cast.

Discussion

The first description of OBPP, which has a frequency of 0.4 to 0.6 per 1000 births, goes back to the 18th century. Many studies have been performed to

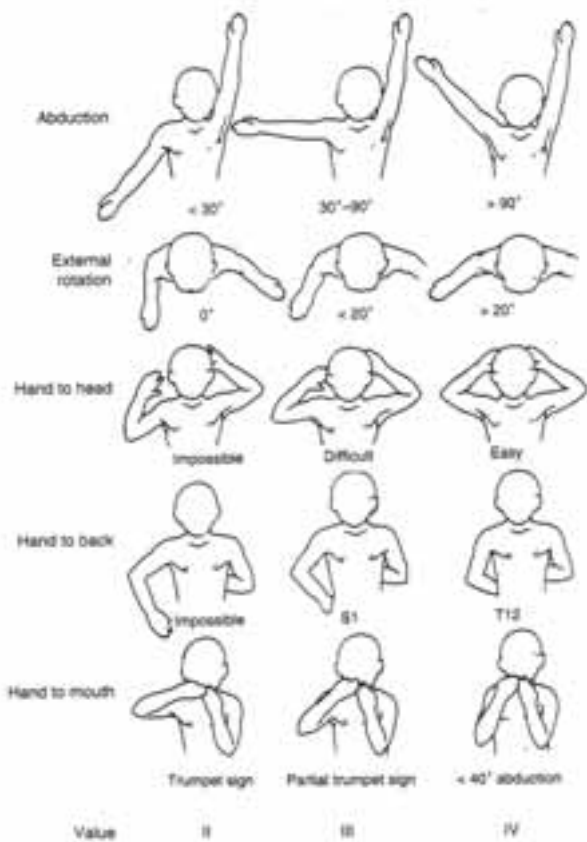


Figure 3. Mallet classification. Grade 0 indicates no movement in the desired plane, Grade V is full movement.

determine the pathogenesis and general prognosis. Although 80-90% of the patients show complete or almost complete healing, the remainder, depending on the level of the lesion, develop functional deficits and consequent joint contractures and skeletal deformities.^(9,10)

The shoulder joint is the most affected. Muscles that adduct and internally rotate the shoulder are innervated by spinal roots C₅-T₁. During the healing process, these muscles are either innervated earlier or are effected to a lesser degree from injury, when compared to shoulder abductors and external rotators, which are innervated by the C₅-C₆ roots. The dominance of internal rotators and adductor muscles

result in internal rotation contracture of the shoulder. In time, the imbalance in the distribution of forces around the shoulder results in bone deformities such as subluxation, dislocation, and elongation in the coracoid and acromion⁽¹¹⁾.

Primary neural surgery in the first 12-18 months of life was first advocated by Gilbert and co-workers in the 1980's, and the results have been promising. Nevertheless, the requirement for palliative surgery still continues in some cases who have undergone primary neural surgery. Especially patients with upper trunk avulsion or total brachial plexus palsy or patients whose upper trunks are sacrificed for lower trunk reconstruction are examples of such conditions.⁽¹³⁾ Also, there are many patients in our country

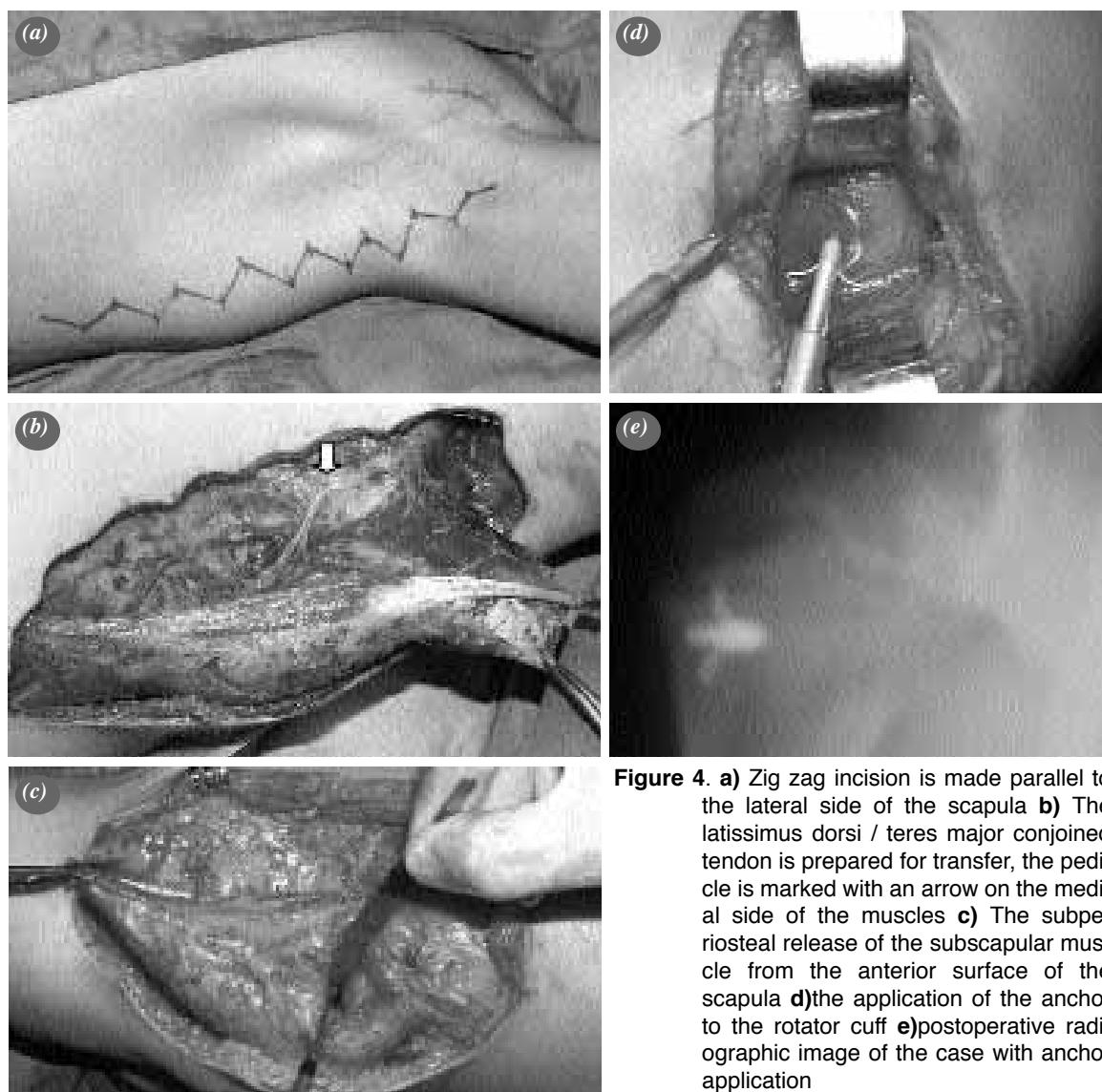


Figure 4. a) Zig zag incision is made parallel to the lateral side of the scapula b) The latissimus dorsi / teres major conjoined tendon is prepared for transfer, the pedicle is marked with an arrow on the medial side of the muscles c) The subperiosteal release of the subscapular muscle from the anterior surface of the scapula d) the application of the anchor to the rotator cuff e) postoperative radiographic image of the case with anchor application

who have lost the chance for primary surgery. The seventy patients evaluated in this study are all such patients who have not undergone primary neural reconstruction.

To correct the disrupted muscle power distribution in the shoulder joint, the subscapular muscle is released before age two. Despite intense physical therapy, if the deficiency in abduction and external rotation persists, abduction and external is enabled with tendon transfers, performed at ages 1-5 (14). Since all patients in our study group were over age two, the subscapular release procedure was applied simultaneously with transfer of the latissimus dorsi/teres major tendon transfer.

Shoulder deformities generally begin to develop around age 3-4. Birch⁽¹⁵⁾ classified glenohumeral joint deformities into five groups by using results of direct x rays and other imaging techniques. Using the images from magnetic resonance and computed tomography, Waters and Peljovich⁽⁶⁾ calculated the percentage of subluxation and retroversion degree, and classified the joint deformity in seven groups (Table 1).

In type I and II patients, muscle release and reconstruction with tendon transfers was preferred. In type III deformity which is characterized with posterior luxation of the humeral head and described as a joint deformity with moderate severity, or in

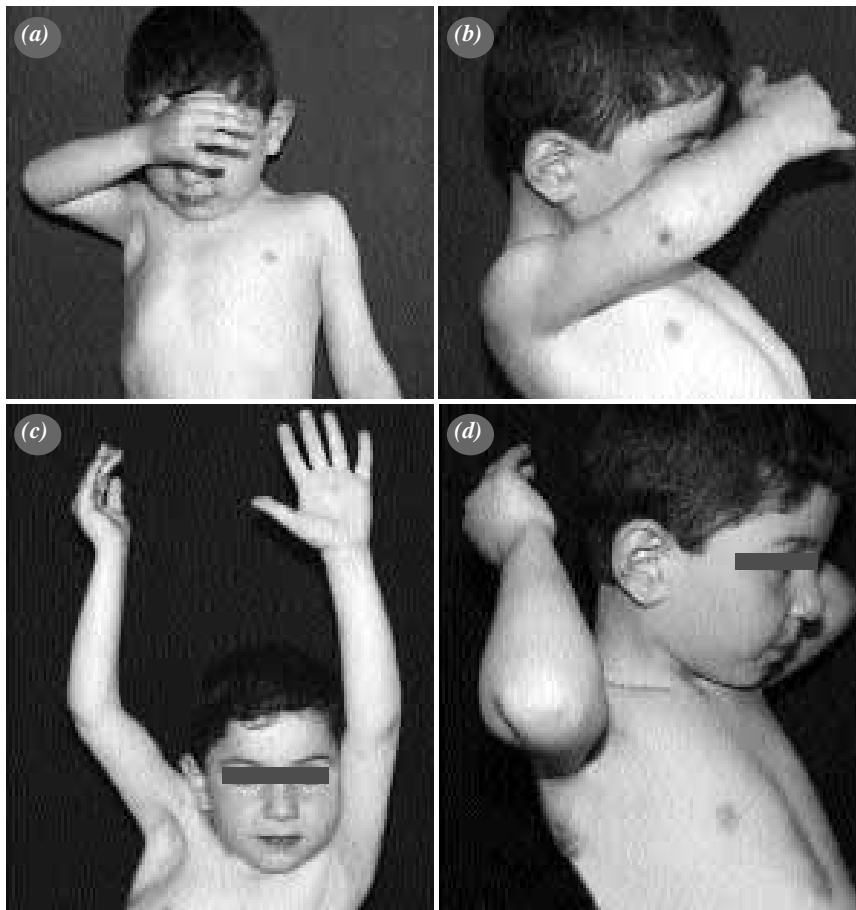


Figure 5. A four year old patient with right sided brachial plexus injury. Preoperative abduction was 100° , and external rotation was 55° . **a)** Attempted elevation of the right arm, anterior view **b)** The patient attempts to bring the hand to the back of the neck, preoperative view. Postoperative abduction was 145° , and external rotation was 90° . **c)** Abduction of both arms **d)** Right sided view as the patient attempts to bring the right hand to the back of the neck

more severe deformities, the choice of reconstruction is external rotation osteotomy of the shoulder and repair of shoulder dislocation. However, there are studies where tendon transfers were applied to patients with type III deformities.⁽¹⁶⁾ All patients in our study, had either type I or type II deformity, therefore, restoration of abduction and external rotation with release of the subscapular muscle with transfer of the latissimus dorsi/teres major to the rotator cuff were preferred.

Various techniques have been described for the release of the subscapularis muscle. In patients who have associated bony deformities, lengthening of the subscapular tendon with an anterior approach and simultaneous correction of bony deformities are preferred. In earlier cases that do not have bone deformities, release of the subscapular muscle from the anterior surface of the scapula with a posterior approach is considered more appropriate.^(17,18) The release of the subscapularis muscle from the anterior

or surface of the scapula was first described by Carlioz and Brahimi.⁽⁷⁾ With this technique, the correction of internal rotation contracture without disruption of the rotator cuff and internal rotatory action of the muscle is aimed.^(17,18)

The transfer of the conjoined tendon formed by latissimus dorsi and teres major tendons to the posterolateral humeral head was described by L'Episcopo. Following this, many surgeons working in this field applied the procedure, either as originally described or after adding modifications, and reported results of various studies (Table 2).^(2,7,16,19-26) Hoffer's⁽²⁾ modification is the transfer of the conjoined tendon to the insertion site of the infraspinatus muscle in the humeral head rather than the humeral neck, with an aim to decrease the moment arm of the rotation movement and to increase the efficacy of the transfer.^(25,26) We have seen that the posterior short transverse incision used by Hoffer⁽²⁾ is inadequate to enable transfer of the conjoined ten-

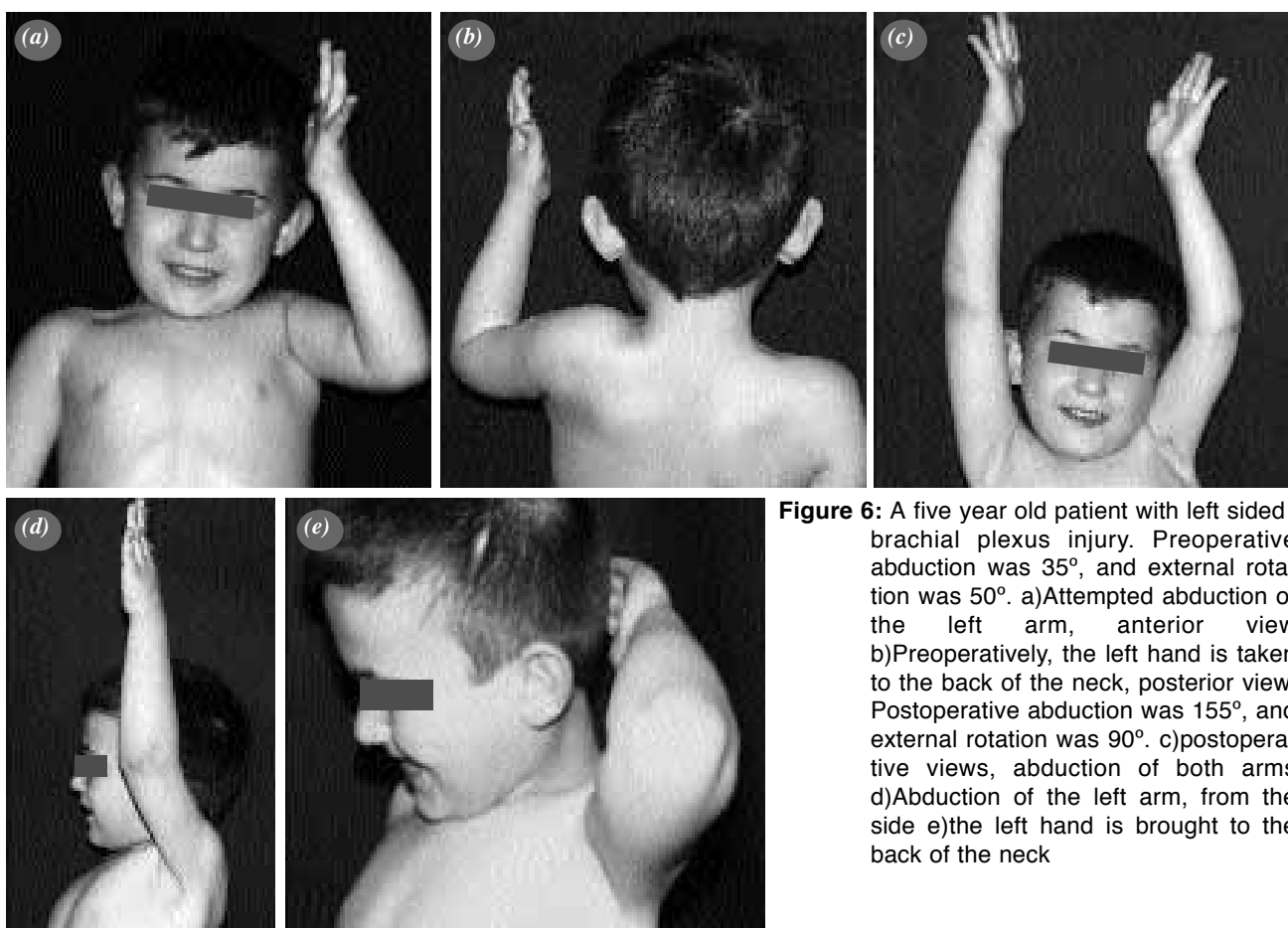


Figure 6: A five year old patient with left sided brachial plexus injury. Preoperative abduction was 35°, and external rotation was 50°. a) Attempted abduction of the left arm, anterior view b) Preoperatively, the left hand is taken to the back of the neck, posterior view. Postoperative abduction was 155°, and external rotation was 90°. c) postoperative views, abduction of both arms d) Abduction of the left arm, from the side e) the left hand is brought to the back of the neck

Table 2. Abduction and external rotation gains in the literature and our study:

	Abduction degree gain	External rotation degree gain
Hoffer (1978) ^[7]	64	45
Zancolli (1981) ^[20]	50	45
Strecker (1990) (1990) ^[22]	–	56
Covey (1992) ^[19]	26	29
L. Nualart (1995) ^[21]	64	42
Price-Grossman (1995) ^[7]	69	62
Chuang (1998) ^[24]	77	48
Edwards (2000) ^[23]	64	-14
Özkan et al.	60	58

don to the rotator cuff ,especially in older children. Therefore, we used all modifications including longitudinal zig zag incision on the posterior axillary line, total release of the muscles and more stable fixation of the conjoined tendon with anchor. As a result, in this study of seventy patients, we had a 60.3 degree increase in abduction and 58.7 degree increase in external rotation. The skin incision is placed on the posterior axillary line and esthetically does not result in significant deformity. Also due to the zig zag course, it does not cause axillary contracture. During the follow up, we did not see a decrease in the gain of abduction and external rotation (recurrence of the deformity) and shoulder luxation/subluxation; and the loss of internal rotation of the shoulder was regained with time. We did not see a negative effect of the application of the anchor on the humerus growth plate or epiphysis.

As a result of our experience, we believe that in cases with mild joint deformity who have lost the chance for primary surgical treatment of who have not gained adequate correction of shoulder functions after primary surgery, satisfactory shoulder abduction and external rotation can be achieved with muscle release and tendon transfer procedures.

References

- Brown KL. Review of obstetrical palsies. Nonoperative treatment. *Clin Plast Surg* 1984;11:181-7.
- Hoffer MM. The shoulder in neonatal brachial palsy. *Clin Orthop* 1999;(368):101-4.
- Yüçetürk A. Obstetrik brakial pleksus yaralanmalarında erken dönem sinir tamirleri. *Türk Ortopedi ve Travmatoloji Birliđi Derneđi Dergisi* 2002;1:24-35.
- Waters PM, Smith GR, Jaramillo D. Glenohumeral deformity secondary to brachial plexus birth palsy. *J Bone Joint Surg [Am]* 1998;80:668-77.
- Goddard NJ, Fixsen JA. Rotation osteotomy of the humerus for birth injuries of the brachial plexus. *J Bone Joint Surg [Br]* 1984;66:257-9.
- Waters PM, Peljovich AE. Shoulder reconstruction in patients with chronic brachial plexus birth palsy. A case control study. *Clin Orthop* 1999;(364):144-52.
- Price AE, Grossman JA. A management approach for secondary shoulder and forearm deformities following obstetrical brachial plexus injury. *Hand Clin* 1995;11:607-17.
- Clarke HM, Curtis CG. Examination and prognosis. In: Gilbert A, editor. *Brachial plexus injuries*. 1st ed. London: Martin Dunitz; 2001. p. 159-72.
- Hoeksma AF, Wolf H, Oei SL. Obstetrical brachial plexus injuries: incidence, natural course and shoulder contracture. *Clin Rehabil* 2000;14:523-6.
- Warner WC. Paralytic disorders. In: Canale ST, editor. *Campbell's operative orthopaedics*. Vol. 4, 9th ed. New York: Mosby; 1998. p. 4039-44.
- Egloff DV, Raffoul W, Bonnard C, Stalder J. Palliative surgical procedures to restore shoulder function in obstetric brachial palsy. Critical analysis of Narakas' series. *Hand Clin* 1995;11:597-606.
- Gilbert A, Brockman R, Carliz H. Surgical treatment of brachial plexus birth palsy. *Clin Orthop* 1991;(264):39-47.
- Raimondi PL, Muset Lara A, Saporiti E. Palliative surgery: shoulder paralysis. In: Gilbert A, editor. *Brachial plexus injuries*. 1st ed. London: Martin Dunitz; 2001. p. 225-38.
- Bennett JB, Allan CH. Tendon transfers about the shoulder and elbow in obstetrical brachial plexus palsy. *J Bone Joint Surg [Am]* 1999;81:1612-27.
- Birch R. Medial rotation contracture and posterior dislocation of the shoulder. In: Gilbert A, editor. *Brachial plexus injuries*. 1st ed. London: Martin Dunitz; 2001. p. 249-59.
- Demirhan M, Erdem M, Uysal M. Treatment of residual obstetrical brachial plexus palsy with tendon transfer. [Article in Turkish] *Acta Orthop Traumatol Turc* 2002;36:295-302.
- Chen L, Gu Y, Xu J. Operative treatment of medial rotation contracture of the shoulder caused by obstetric brachial plexus palsy. *Chin J Traumatol* 2000;3:13-17.
- Muhlig RS, Blaauw G, Slooff AC, Kortleve JW, Tonino AJ. Conservative treatment of obstetrical brachial plexus palsy (OBPP) and rehabilitation. In: Gilbert A, editor. *Brachial plexus injuries*. 1st ed. London: Martin Dunitz; 2001. p. 173-87.
- Covey DC, Riordan DC, Milstead ME, Albright JA. Modification of the L'Episcopo procedure for brachial plexus birth palsies. *J Bone Joint Surg [Br]* 1992;74:897-901.
- Zancolli EA. Classification and management of the shoulder in birth palsy. *Orthop Clin North Am* 1981;12:433-57.
- Nualart L, Cassis N, Ochoa R. Functional improvement with the Sever L'Episcopo procedure. *J Pediatr Orthop* 1995;15:637-40.
- Strecker WB, McAllister JW, Manske PR, Schoenecker PL, Dailey LA. Sever-L'Episcopo transfers in obstetrical palsy: a retrospective review of twenty cases. *J Pediatr Orthop* 1990;10:442-4.
- Edwards TB, Baghian S, Faust DC, Willis RB. Results of latissimus dorsi and teres major transfer to the rotator cuff

- in the treatment of Erb's palsy. *J Pediatr Orthop* 2000;20:375-9.
24. Chuang DC, Ma HS, Wei FC. A new strategy of muscle transposition for treatment of shoulder deformity caused by obstetric brachial plexus palsy. *Plast Reconstr Surg* 1998;101:686-94.
25. Phipps GJ, Hoffer MM. Latissimus dorsi and teres major transfer to rotator cuff for Erb's palsy. *J Shoulder Elbow Surg* 1995;4:124-9.
26. Hoffer MM, Phipps GJ. Closed reduction and tendon transfer for treatment of dislocation of the glenohumeral joint secondary to brachial plexus birth palsy. *J Bone Joint Surg [Am]* 1998;80:997-1001.