



## Subcutaneous injection of insecticide for attempted suicide: a report of two case

### *İntihar amacıyla ciltaltına böcek ilacı enjeksiyonu: İki olgu sunumu*

Atakan AYDIN, Funda AKÖZ, Metin ERER

*Istanbul University Istanbul Medical Faculty Plastic and Reconstructive Surgery*

Önkola böcek ilacı enjeksiyonuyla intihar teşebbüsünde bulunan iki hasta (30 yaşında kadın, 20 yaşında erkek) sunuldu. İki olguda da akut ve subakut dönemlerde sistemik toksikasyon bulgularına rastlanmadı. Kolda akut atravmatik kompartman sendromunu düşündüren ciddi şişlik, ağrı ve gerginlik olduğundan acil olarak fasyotomi ve cerrahi debridman uygulandı. Ameliyatta ciltaltı dokularda geniş nekroz gözlemlendi. Olguların uzun süreli izlemlerinde herhangi bir motor ve duysal sekele veya kontraktür gelişimine rastlanmadı.

**Anahtar sözcükler:** Apse; selülit; debridman; önkol; enjeksiyon, ciltaltı; böcek ilacı/zehirlenme; nekroz; intihar teşebbüsü.

We present two patients (30-year-old female, and 20-year-old male) who attempted suicide by injecting commercially available insecticides into the forearm. No systemic signs of intoxication were observed during the acute and subacute periods. Since both patients had severe swelling, pain, and tension in the affected limb, suggesting acute atraumatic compartment syndrome, immediate fasciotomy and surgical debridement were performed. At surgery, extensive subcutaneous necrosis was observed. During long-term follow-ups, no motor and sensory deficits or contractures were seen.

**Key words:** Abscess; cellulitis; debridement; forearm; injections, subcutaneous; insecticides/poisoning; necrosis; suicide, attempted.

Pyrethroids, not being accepted as directly cytotoxic agents, but are ion channel toxins that elongate the neural excitation. Systemic toxicity is rarely reported despite the widespread use. Local signs of toxicity include paresthesia if skin is involved, and gastrointestinal irritation if the route of exposure is oral intake. Due to the slow rate of absorption via skin, systemic toxicity is not expected concerning this kind of exposure<sup>1,2</sup>. It is reported more than once time that the subcutaneous injection of the agent, the domestic form, resulting in cellulitis, compartment syndrome, liquefaction necrosis, and abscess formation (microbic or sterile) following cellulitis<sup>3-5</sup>. The primary goal of a hand surgeon dealing with such injury involves precise timing and planning of debridement and fasciotomy to prevent further damage to hand functions. Antibiotic chemotherapy and rehabilitation should be considered adjunctive to

surgery. Taking different treatment measures is vastly dependent on perceiving the different clinic presentations of subcutaneous insecticide injection<sup>6</sup>.

### Case Report

**Case 1** – 30 year old woman with undetermined psychiatric disorder attended to our emergency clinic with a history of recent subcutaneous pyrethroid insecticide injection in a suicidal attempt. No signs of systemic toxicity were noted in acute (24-72 hrs) or subacute (3-10 days) periods. Severe edema, pain and distention were present in the affected arm, whilst the clinical symptoms of compartment syndrome became manifested on progress. The patient was then brought to operation room for immediate fasciotomy and superficial muscle debridement. The resultant open wound was then closed with a split-thickness skin graft at the end of a week of intensive

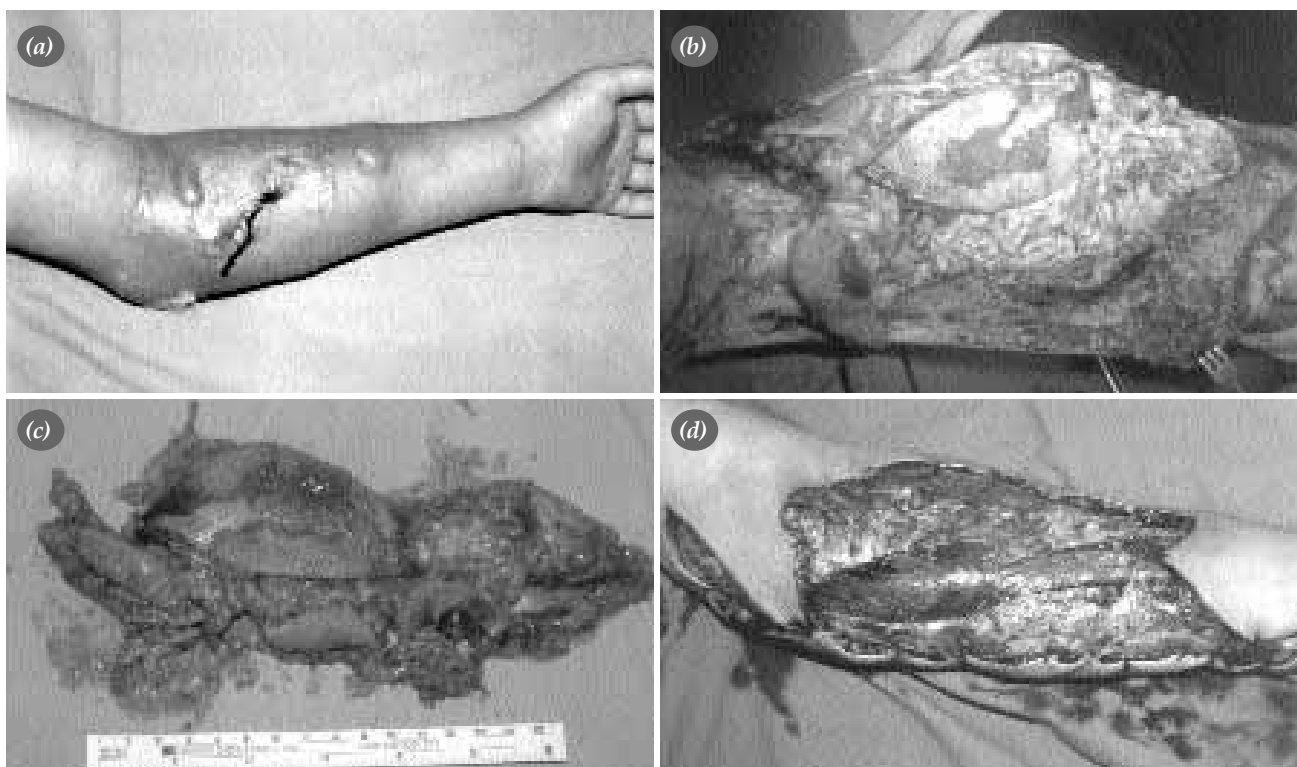
wound care. 5 year follow up of the patient showed no signs of motor or sensory deficits, or muscular contracture.

**Case 2** – 20 year old man was brought to our clinic, 24 hours after injecting pyrethroid insecticide to his left forearm subcutaneously in a suicidal attempt. Because of intense pain, he could have injected only minute amount (1-2 ml) of insecticide on occasion. Despite the lack of any signs of systemic toxicity, profound erythema, edema, hypothermia, pain and bullous lesions were observed (figure 1a). Immediate fasciotomy and surgical debridement were performed. In spite of the lack of demarcation lines at the skin, a pathological appearance regarded as liquefaction necrosis was seen in the subcutaneous fat tissue extending from subdermal tissues to the fascia of the forearm within a normal appearing skin (figure 1b). Microbiological studies of deep tissue samples remained sterile. The pathologic appearing skin and subcutaneous tissues were excised (figures 1c-1d). The resultant open wound, after one week of daily wound care has developed granulation tissue for

which a STSG (split-thickness skin graft) was used to cover. One year follow up showed no symptoms/signs of complications.

## Discussion

Intramuscular, intravenous and subcutaneous injections of organophosphates for attempted suicide were reported in previous literature<sup>7,8</sup>. Contrarily, the data on the use of pyrethroid type insecticides for same reasons are quite rare. The current toxicological data is based on the experimental studies conducted on the rodents which implies manifestations as tremor, choreatetosis, hypersalivations, convulsions, and death following intravenous and intracerebral injections of pyrethroid compounds. The presentations of systemic toxicity following oral intake of the compounds in humans can be grouped in two distinct set of disorders depending on the chemical properties of the pyrethroid compound, one of which is known as the so called tremor syndrome and the other as choreatetosis syndrome. No data is found in the current literature on systemic toxicity fol-



**Figure 1.** (a) Eritema, edema, severe pain at the forearm was present after insecticide injection (b) The pathologic appearance of subcutaneous fatty tissue is assessed as liquefaction necrosis (c) the excised skin and subcutaneous tissue (d) the appearance of the defect at the forearm after debridement

lowing subcutaneous injections, hence no signs and symptoms of systemic toxicity were manifested in our both cases despite the cooperation problems and depression were due. However the patients must be monitored closely and intensely.

Following the injections made in the clinical practice, and/or self injections done by the drug/chemical abusers may lead to acute compartment syndrome, which may then severely threaten the circulation and hence the existence of the given extremity. Edema, pain, swelling and skin changes are seen in the affected body part. The compartment syndrome is the result of direct vasotoxic effect of the chemical or prolonged comatose state, hence prolonged compression of the extremity. Amputations may become necessary due to the vasotoxicity. When left untreated, motor/sensory deficits or contractures would complicate the picture. Immediate fasciotomy is a must in order to prevent the long term adversaries and fixated deformities<sup>6</sup>.

Following the injection of house hold type of insecticides, apart from the compartment syndrome, profound necrosis, sterile or microbic abscess formation was reported<sup>3,5,8</sup>. This is the result of both direct cytotoxic effect of this compounds and vascular compromise of the tissues. These factors both contribute to the perfect environment for microorganisms to reign. For this reason, early administration of antibiotics and tetanus prophylaxis is necessary. Whilst delay of surgical debridement of the necrotic tissues until subacute phases were reported, prompt debridement<sup>9</sup> and fasciotomy were indicated in our 2nd case for which the quantity was as small as 1-2 ml and attendance to our clinic was as late as 24 hrs after

the event. Surgical debridement may also aid in clearance of the toxic substances hence contributing to prevention of possible systemic toxicity<sup>10</sup>.

As a result, the patients presenting with insecticide injections in suicidal attempts should be evaluated carefully so that early diagnosis, immediate planning of fasciotomy and surgical debridement can be established to prevent later complications which may include ischemic contracture or limb amputations.

## References

1. Soderlund DM, Clark JM, Sheets LP, Mullin LS, Piccirillo VJ, Sargent D, et al. Mechanisms of pyrethroid neurotoxicity: implications for cumulative risk assessment. *Toxicology* 2002;171:3-59.
2. Ray DE, Forshaw PJ. Pyrethroid insecticides: poisoning syndromes, synergies and therapy. *J Toxicol Clin Toxicol* 2000; 38:95-101.
3. Goldberg LH, Shupp D, Weitz HH, Zeccardi JA. Injection of household spray insecticide. *Ann Emerg Med* 1982;11:626-9.
4. Buchman MT. Upper extremity injection of household insecticide: a report of five cases. *J Hand Surg [Am]* 2000;25:764-7.
5. Wedin GP, Jones RR. Parenteral administration of hydrocarbons. *J Toxicol Clin Toxicol* 1984;22:485-92.
6. Franc-Law JM, Rossignol M, Verneq A, Somogyi D, Shrier I. Poisoning-induced acute atraumatic compartment syndrome. *Am J Emerg Med* 2000;18:616-21.
7. Guven M, Unluhizarci K, Goktas Z, Kurtoglu S. Intravenous organophosphate injection: an unusual way of intoxication. *Hum Exp Toxicol* 1997;16:279-80.
8. Hadimioglu N, Dosemeci L, Arici G, Ramazanoglu A. Systemic organophosphate poisoning following the percutaneous injection of insecticide. Case report. *Skin Pharmacol Appl Skin Physiol* 2002;15:195-9.
9. Rush MD, Schoenfeld CN, Watson WA. Skin necrosis and venous thrombosis from subcutaneous injection of charcoal lighter fluid (naptha). *Am J Emerg Med* 1998;16:508-11.
10. Terzi C, Bacakoglu A, Unek T, Ozkan MH. Chemical necrotizing fasciitis due to household insecticide injection: is immediate radical surgical debridement necessary? *Hum Exp Toxicol* 2002;21:687-90.