



## Treatment of AO type C2-C3 fractures of the distal end of the radius with external fixation

### *Radius distal uç kırıklarının (AO tip C2-C3) eksternal fiksasyonla tedavisi*

Mahmut KOMURCU,<sup>1</sup> Levent KAMACI,<sup>2</sup> M. Taner OZDEMIR,<sup>3</sup> A. Sabri ATESALP,<sup>1</sup> Mustafa BASBOZKURT<sup>1</sup>

<sup>1</sup>Gulhane Military Medical Academy, Department of Orthopedics, Ankara; <sup>2</sup>Military Hospital, Iskenderun; <sup>3</sup>Military Hospital, Corlu

**Amaç:** Radius distal uç kırığı nedeniyle kapalı redüksiyon, greftleme, K-teli ve eksternal fiksasyon uygulanan hastalar tedavi sonuçları açısından değerlendirildi.

**Çalışma planı:** Çalışmaya 24 hasta (15 erkek, 9 kadın; ort. yaş 34; dağılım 21-73) alındı. Kırıklar, AO sınıflamasına göre 16 hastada C2, sekiz hastada C3 tipte idi. Üç hastada açık kırık, dört hastada median sinir basısı bulguları vardı. Tedavi olarak, redüksiyon ve otolog greftlemeden (16 olgu) sonra K-teli (2-5 adet) ile fiksasyon ve eksternal fiksasyon uygulandı. Sonuçlar, klinik olarak Gartland-Werley, radyografik olarak Stewart ölçütleri ile değerlendirildi. Dejeneratif değişiklikler Knirk-Jupiter skalasına göre sınıflandırıldı. Ortalama izlem süresi 35 ay (dağılım 25-52 ay) idi.

**Sonuçlar:** Çalışan 19 hastanın hepsi, ortalama 3.5 ayda yaranın öncesi aktivitelerine döndü. Radyografilerde, radial uzunluğun büyük oranda korunduğu saptandı. Eklem yüzeyinde ortalama 1.4 mm çökme gözlemlendi. Radial inklinasyonunda ortalama %6.7, volar tiltte %17.6 kayıp vardı. Stewart ölçütlerine göre, 12 olguda iyi, dokuz olguda orta, üç olguda kötü sonuç alındı. Eklem hareket genişliklerinde fleksiyon-ekstansiyonun %75, supinasyon-pronasyonun %70, radial-ulnar deviyasyonun %75 korunduğu görüldü. Yakalama gücünde, karşı tarafa göre %70'lik bir değere ulaşıldı. Gartland-Werley ölçütlerine göre, sonuçlar üç olguda mükemmel, sekiz olguda iyi, 10 olguda orta, üç olguda kötü bulundu. Knirk-Jupiter sınıflamasına göre, altı olguda dejenerasyon hiç yoktu; 11 olguda hafif, altı olguda orta, bir olguda ileri derecede dejeneratif değişiklik saptandı. Dört hastada K-teli yoluyla ilgili sorun; iki hastada erken dönemde geçici refleks sempatik distrofi; iki hastada radial sinir yüzeyel dalının geçtiği bölgede hipoestezi görüldü.

**Çıkarımlar:** Radius distal uç kırıklarında (AO tip C2-C3) eksternal fiksasyon, otograft ve perkütan K-teli kombinasyonu ile tedavi normale yakın radyografik ve klinik sonuçlar sağlamaktadır.

**Anahtar sözcükler:** Colles kırığı/cerrahi; eksternal fiksasyon; kırık fiksasyonu, internal; kırık, parçalı/cerrahi; radius kırığı/sınıflandırma/cerrahi; hareket açıklığı, eklem; el bileği yaranması.

**Objectives:** We evaluated the results of combined treatment with closed reduction, grafting, K-wires, and external fixation in patients with fractures of the distal end of the radius.

**Methods:** Of 24 patients (15 males, 9 females; mean age 34 years; range 21-73), 16 patients had C2, eight patients had C3 fractures according to the AO classification. Three patients had open fractures, and four patients had signs of median nerve compression. Treatment included closed reduction, autologous grafting (16 cases) followed by fixation with 2 to 5 K-wires, and an external fixator. Clinical and radiographic results were assessed according to the Gartland-Werley's and Stewart's criteria, respectively, and degenerative changes to the Knirk-Jupiter's criteria. The mean follow-up was 35 months (range 25 to 52 months).

**Results:** All of the 19 patients who were employed returned to preinjury working conditions in a mean of 3.5 months. Radial length was preserved to a great extent. The mean amount of collapse of the joint surface was 1.4 mm. The mean loss was 6.7% in radial inclination, and 17.6% in the volar tilt. According to the Stewart's criteria, the results were good, moderate, and poor in 12, nine, and three patients, respectively. Flexion-extension (75%), supination-pronation (70%), and radial-ulnar deviation (75%) were preserved to a great extent. Grip force amounted to 70% of the healthy side. According to the Gartland-Werley criteria, three patients had excellent, eight patients had good, 10 patients had moderate, and three patients had poor results. According to the Knirk-Jupiter's criteria, degenerative changes were slight in 11 patients, moderate in six patients, and severe in one patient. Six patients had no signs of degeneration. Complications included pin track infections (n=4), early transient reflex sympathetic dystrophy (n=2), and hypoesthesia along the superficial branch of the radial nerve (n=2).

**Conclusion:** Treatment of the distal end fractures of the radius (AO type C2-C3) with a combination of external fixation, grafting, and percutaneous K-wires provides almost normal radiologic and clinical parameters.

**Key words:** Colles' fracture/surgery; external fixators; fracture fixation, internal; fractures, comminuted/surgery; radius fractures/classification/surgery; range of motion, articular; wrist injuries.

AO type C2 – C3 fractures are described as distal radial metaphyseal comminuted fractures with intraarticular extension. These fractures are generally occurs in young population, their treatment is quite difficult and complication rate is evidently high. Additionally there is no consensus on the treatment modality.<sup>[1,2]</sup> Regaining preinjury activity level in these patients is the least one among the patients whose suffered from distal radius fractures.<sup>[3]</sup> For these reasons Jupiter and Lipton describes the intra-articular comminuted distal radial fractures as "pilon fractures of the upper extremity".<sup>[4]</sup>

Increasing number of papers in the literature were seen about treatment of comminuted distal radial fractures and these papers stated that application of combined surgical techniques achieves better outcomes.<sup>[5]</sup> But two major drawbacks, joint stiffness and traumatic osteoarthritis are still worsen the long term results of these intrarticular fractures.<sup>[2,7,8]</sup>

In this paper, we discussed our preferred treatment modality of AO Type C2 – C3 fractures with closed reduction with image intensifier, bone grafting, multiple K wire fixation and external fixation.

### Patients and methods

Between September 1998-January 2001 24 patients (15male, 9 female, mean age 34, distribution 21-73) who have AO type C2-C3 fractures were retrospectively evaluated. 6 patients were on the post menopausal period. Fracture etiology in 11 patients were high energy trauma (6 traffic accident, 4 fall from height, 1 work accident) in 10 patients fall, in 3 patients sports related injury. There were 3 open fractures and were 2 Type one and 1 Type two according to Gustilo-Anderson classification. Three patients who suffered from traffic accident had contra lateral forearm fractures. Four patients who had volar displaced fragments revealed median nerve compression signs.

The fractures were classified according to AO classification system preoperatively with anteroposterior and lateral roentgenograms (Figure 1 a-b). 16 patients had type C2 and 8 patients had type C3 fractures. Additionally radial shortening, radial inclination, dorso-volar tilt, joint incongruency, position of carpal bones were recorded. In 5 cases computerized tomography was used to evaluate the joint surface. Results of radiological evaluation pointed out

that all fractures unstable and intraarticular comminution was present. Therefore patients underwent surgery. Extremities were splinted and elevated until the operation (one to five days) to prevent edema and neurovascular complications.

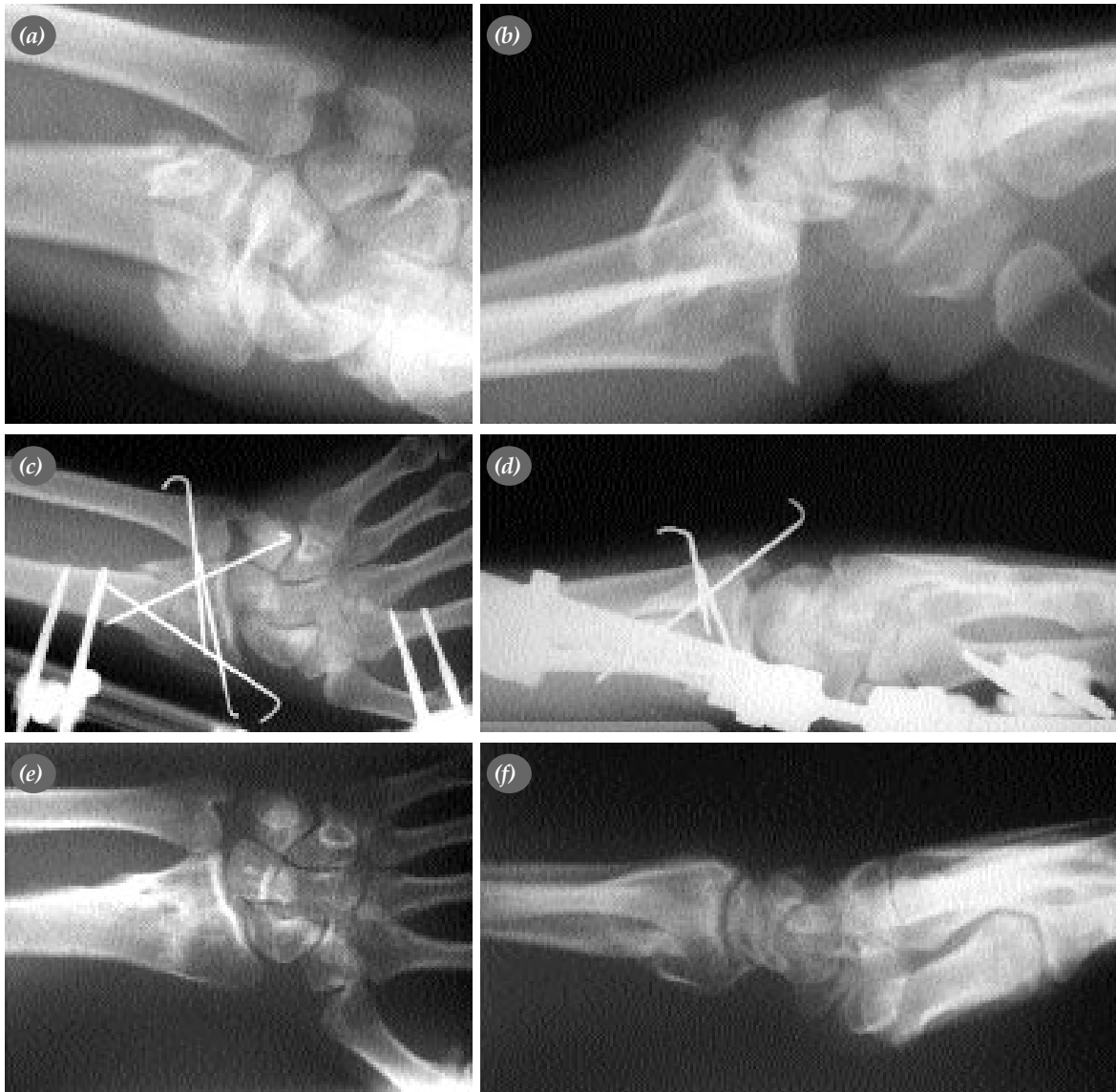Patients were treated by combined modalities. Surgical technique included closed reduction under fluoroscopic control, autologous cancellous bone, 2-5 K wire fixation and external fixation. Patients were operated under general or regional anesthesia. Initially closed reduction was attempted and external fixation was applied. 2, four millimeter schanz screws were placed on the 1/3 distal part of radius while superficial radial sensory nerve was protected with 2 cm incisions. 2, three millimeter schanz screws were applied on the second metacarpal. Then external fixator was applied to the screws loosely, after that closed reduction was performed under image intensifier and the joint was distracted 1-2 mm. Finally the fixator was tightened while the wrist in slight flexion and ulnar deviation. Ulnar deviation is the key point of reduction which is done to maintain radial length. In order to restore collapse and fragmentation in the metaphyseal region, a 1-2 cm incision was performed between the dorsal third and fourth compartments.

Then using an elevator, volar tilt was corrected. In 16 cases (all C3 and 8 C2 fractures) the metaphyseal defects were grafted with autogenous iliac cancellous bone. Under image intensification, joint surface was controlled. Great amount of care was taken to prevent joint incongruity and not to cause a gap wider than 1mm on the joint surface.


After achieving distal radial geometry, 2 to 5, 1,5mm K-wires were applied from the radial styloid and lunate fossa (Figure 1 c-d). Sometimes a parallel K-wire to the joint line was added. The decision of grafting in the metaphyseal region was made by these parameters; the age of patients, degree of comminution, presence of bone loss and radiographic appearance of distal radius after the reduction. In open fractures at first debridement was performed, then the other steps that mentioned above was initiated. Four patients suffered from median nerve compression therefore carpal tunnel release was performed during the operation. Ulnar styloid was fixed with a K-wire in two patients and temporary distal radioulnar fixation with K-wire was needed in

another. Amount of distraction on the external fixator was diminished after four weeks. K-wires were removed 4-6 weeks later (average 4,5 weeks) and external fixator was removed 5,5-8 weeks later (average 6,5 weeks). Patients were closely followed up for 1,3,6 weeks and 3,6 months respectively.

Active finger ROM exercises were initiated on the day after surgery. Supination and pronation exercises were started after two weeks. After the fixator removal no limitation of exercises were done. Meanwhile a dynamic splinting program was applied to patients who had pronation-supination



**Figure 1.** (a, b) Anteroposterior and lateral radiographs of a patient who suffered from a traffic accident. (AO type C2) (c, d) Early post-operative radiographs. (e, f) Anteroposterior and lateral radiographs on 25th month. (g, h) Clinical appearance of patient after physical therapy.



less than 120 degrees and flexion-extension 100 degrees. Intrinsic and extrinsic muscle strength was assessed with a dynamometer. Comparative radiographs were taken in order to evaluate the radial length, volar-dorsal angulation, joint surface regularity and arthritic changes. Mean follow up was 35 months (25-52 months). Radiological, clinical and degenerative arthritic results were assessed according to Gartland-Werley, Stewart and Knirk-Jupiter criteria's respectively. [6,7,8,9]

## Results

All working patients returned to their jobs after 2.5 – 6 months (average 3,5 months). However at the end of six months three patients who had type C3 fractures complained about difficulties in performing their daily activities and necessitated to use analgesic drugs. 3 patients (two type C3 and one Type C2) also reported that they were unable to do exercises and job related heavy works while they had no complaint about their daily activities.

According to the last follow up radiographs radial length was protected in almost whole patients (8.3-10.6 mm, mean 10.1 mm). However approximately 1.4 mm (0-2.4 mm) depression in the joint line was detected (Figure 1 e-f). Loss of radial inclination and volar tilt were 0.26 (%6.7), 0.68 degree (%17.6). According to Stewart criteria 12 good, 9 moderate and 3 poor results were obtained (Table 1).

Range of motion of involved extremities was almost preserved. Loss of motions were; % 25 flexion-extension, % 30 supination-pronation, %25 radial-ulnar deviation. The average final grip strength of involved extremity was % 70 of the uninvolved extremity. According to Gartland- Werley criteria 3 excellent, 8 good, 10 moderate, 3 poor results were obtained (Figure 1 g-h).

Three cases (all Type C3) represented with narrowed joint space. According to Knirk- Jupiter classification no degeneration in 6 cases, mild in 11 cases, moderate in 6 and serious in one were reported (Table 2).

Postoperatively 4 pin tract infection were treated with antibiotherapy. Early reflex sympathetic dystrophy appeared in two patients and resolved with physical therapy and medication. Two patients had hypoesthesia along the superficial branch of the

**Table 1.** Final results according to evaluation criteria.

	Excellent	Good	Moderate	Poor
Gartland Werley	3	8	10	3
Knirk Jupiter	6	11	6	1
Stewart	–	12	9	3

radial nerve. Control EMG of the patients who underwent carpal tunnel release was normal at the sixth month. There were no deep infection and nonunion observed.

## Discussion

Some of the distal radial intraarticular fractures are seen in young patients as a result of high energy traumas (motor vehicle accidents, fall from a height). [5,8] Performing combined surgical modalities after a careful preoperative evaluation and planning; is reported to be necessary in obtaining good functional and radiographic results. [3,5,6,10] In the treatment of mostly comminuted distal radial intraarticular fractures, surgeons may encounter serious complications such as difficult reduction and stabilization, loss of reduction while immobilization period, limitation of ROM, post traumatic arthritis of the wrist. For this reason a good algorithm of treatment should be made. A brief classification should be made before treating the distal radial fractures.

Among various classification systems, the AO classification system is the most suitable one because of reflecting the severity of the fracture and for helping the surgeon and the patient to know the possible outcomes. [2,11,12] We used the AO classification in this study.

**Table 2.** Radiographical and clinical parameters

Parameter	Comparative measurements
Flexion -- Extension	%75
Supinasyon-pronasyon	%70
Radial-ulnar deviyasyon	%75
Grip strength	%70
Radial length	10.1 mm
Depression on the joint surface	1.4 mm
Loss of radial tilt	%6.7
Loss of volar tilt	%17.6

According to AO classification; the surgical treatment of type C2 and C3 fractures are more difficult because they have intraarticular expansion and metaphyseal defect components. If the comminuted and impacted metaphysis is not restored anatomically then malunion, decreased radial length and depression in the metaphysis may occurs.<sup>[3,6]</sup>

The comminution of fragments show that the fracture is occurred as a result of a high energy trauma. The amount of the soft tissue damage is hard to predict in such injuries thus a good algorithm of treatment should be made. Generally the restoration of the irregularity of the joint surfaces with closed reduction is not possible. More than 1 mm displacement and depression of the fragments have high risk for post traumatic arthritis.<sup>[4,13,14]</sup> In order to prevent such poor outcomes, one should use combined surgical techniques to restore the distal radius most anatomically.<sup>[1,2,11]</sup>

The reasons of using external fixators are; the continuity of reduction made by fluoroscopy control, improve reduction by ligamentotaxis, protect to reduction until healing occurs. When metaphysis comminuted seriously, radial length which is required for the restoration of articular surfaces can be provided and maintained only by external fixation.<sup>[15]</sup> Additionally this method helps to improve the outcome by permitting supination and pronation, finger motion while the treatment.<sup>[1,6,7]</sup> However external fixation is not sufficient for reduction of dorsally displaced volar-medial fragments and to restore radiopalmar tilt.<sup>[2,12]</sup>

For this reason additional internal fixation methods especially K- wire fixation are suggested. K wire fixation is suggested to be very important for adjustment of the fragments and distal radial geometry.<sup>[5,8,13]</sup> The K wires provide additional stability since they prevent the micro motions of the fragments.<sup>[5]</sup> In high energy traumas volar approach if suggested to be added to dorsal approach restore the palmar stability.<sup>[1,16]</sup>

The restoration of the articular surfaces could not be done only by ligamentotaxis since there is an impaction between the metaphysis and cancellous bone.<sup>[7]</sup> ORIF should be performed for these epiphyseometaphyseal fractures.<sup>[2,16,17]</sup> The soft tissue damage in high energy traumas causes edema, wound

complications and high rate of infection.<sup>[5,7]</sup> We believed that surgery by less invasive techniques shortens the wound healing time and reduces the complication rates.

In our study reduction made by fluoroscopic control is supported and loss of reduction is prevented by K wire fixation and external fixators. The period of distraction is reported to affect the functional outcome directly.<sup>[1,2,18]</sup> The time for external fixation is 5-8 weeks for static fixation and 7-10 weeks for dynamic fixation.<sup>[6,15]</sup> In our study average time for fixators is 6.5 weeks (5,5-8 weeks). The distraction was reduced after the fourth week.

In the literature complication rate of external fixators are reported up to % 27 percent. These are pin tract infection, fractures occurred by pin fixation, clawing of fingers as a result of over distraction, hypoesthesia on radial nerve dermatome and reduction of the wrist ROM.<sup>[5,19]</sup> The neurological complications may were found to be present at the injury time but not after the surgical procedure.<sup>[5]</sup> In our study pin tract infection were seen in only four patients.

The shortening of radius causes dysfunction by impairing the weight bearing of joint surfaces.<sup>[1,6,7]</sup> Furthermore residual dorsal tilt causes poor outcome since it affects the ulnocarpal joint (especially pinching and grasping).<sup>[1,17]</sup> The depression of the metaphysis should reveal poor outcomes because it causes difficulties in restoration of the radial length.<sup>[3]</sup> For these depressed fractures ORIF and bone grafting are suggested to improve the functional outcome.<sup>[2,5,10,20]</sup> We faced such cases in our study and perform bone grafting in all C3 and in most of C2 fractures.

The comparison of the functional results of unstable intraarticular fractures is hard because of the different classification systems and evaluation criteria's. Additionally the difference of the ages of the patients, treatment procedures and mean follow up time causes difficulties in the comparison of these studies.<sup>[3,5]</sup>

The mostly seen poor outcomes include joint stiffness, loss of strength, persistent wrist pain. Evaluation of the results of five studies made by intra articular distal radial fractures treated by external fixators revealed % 45-90 excellent and good

results according to the Gartland-Werley criterias.<sup>[5]</sup> Although surgical procedure was similar to ours but evaluation criteria were different, Bass et al reported ten excellent and good results in 13 patients with C3 fractures in their study.<sup>[3]</sup> Klein et al reported %46 good, % 10 moderate, % 3 poor results in 102 patients according to Gartland- Werley criteria.<sup>[21]</sup>

The most important reasons of our good results; restoration of anatomy was made by minimal invasive techniques (volar tilt, intra articular displacement, radial length). Moreover we used bone grafting in metaphyseal comminuted fractures. But the important reason of surgical difficulties during operation is sufficient intra articular reduction. Fluoroscopy has not been found to be sufficient in this situation.

Therefore the best way to solve this problem is arthroscopy. Reduction could be made by arthroscopy assisted techniques and less than 0.5-1 mm displacement could be achieved. The negative factors of this technique are risk of compartment syndrome, necessity of experience and time, prolonged operation time. In order to understand the effect of arthroscopy and fluoroscopy, more controlled and comparative studies are needed.

Proper intra articular restoration, mini open reduction assisted by fluoroscopy, complete anatomical reduction, maintenance of reduction until healing are needed for good results in unstable distal radial fractures. The loss of reduction may occur in these patients and even if they are realigned again it shouldn't be forgotten that progressive collapse in the metaphysis may lead to chronic instability. External fixation is an outstanding technique because of the ability to restore and maintain the radial length and also prevention of metaphyseal collapse can be done autogenous grafting in AO C2-C3 fractures.

## References

- Hanel DP, Jones MD, Trumble TE. Wrist fractures. *Orthop Clin North Am* 2002;33:35-57.
- Fernandez DL, Geissler WB. Treatment of displaced articular fractures of the radius. *J Hand Surg [Am]* 1991;16:375-84.
- Bass RL, Blair WF, Hubbard PP. Results of combined internal and external fixation for the treatment of severe AO-C3 fractures of the distal radius. *J Hand Surg [Am]* 1995;20:373-81.
- Jupiter JB, Lipton H. The operative treatment of intraarticular fractures of the distal radius. *Clin Orthop* 1993;(292):48-61.
- Huch K, Hunerbein M, Meeder PJ. External fixation of intra-articular fracture of the distal radius in young and old adults. *Arch Orthop Trauma Surg* 1996;115:38-42.
- Zanotti RM, Louis DS. Intra-articular fractures of the distal end of the radius treated with an adjustable fixator system. *J Hand Surg [Am]* 1997;22:428-40.
- Trumble TE, Schmitt SR, Vedder NB. Factors affecting functional outcome of displaced intra-articular distal radius fractures. *J Hand Surg [Am]* 1994;19:325-40.
- Knirk JL, Jupiter JB. Intra-articular fractures of the distal end of the radius in young adults. *J Bone Joint Surg [Am]* 1986;68:647-59.
- Stewart HD, Innes AR, Burke FD. Functional cast-bracing for Colles' fractures. A comparison between cast-bracing and conventional plaster casts. *J Bone Joint Surg [Br]* 1984;66:749-53.
- Herrera M, Chapman CB, Roh M, Strauch RJ, Rosenwasser MP. Treatment of unstable distal radius fractures with cancellous allograft and external fixation. *J Hand Surg [Am]* 1999;24:1269-78.
- Kreder HJ, Hanel DP, McKee M, Jupiter J, McGillivray G, Swiontkowski MF. Consistency of AO fracture classification for the distal radius. *J Bone Joint Surg [Br]* 1996;78:726-31.
- Akmaz I, Pehlivan O, Kiral A, Solakoglu C, Arpaciglu O. Short-term results of external fixation of unstable distal radial fractures. [Article in Turkish] *Acta Orthop Traumatol Turc* 2003;37:126-32.
- Kaempffe FA, Wheeler DR, Peimer CA, Hvidsak KS, Ceravolo J, Senall J. Severe fractures of the distal radius: effect of amount and duration of external fixator distraction on outcome. *J Hand Surg [Am]* 1993;18:33-41.
- Dodds SD, Cornelissen S, Jossan S, Wolfe SW. A biomechanical comparison of fragment-specific fixation and augmented external fixation for intra-articular distal radius fractures. *J Hand Surg [Am]* 2002;27:953-64.
- Raskin KB, Melone CP Jr. Unstable articular fractures of the distal radius. Comparative techniques of ligamentotaxis. *Orthop Clin North Am* 1993;24:275-86.
- Tornetta P 3rd. Intraarticular distal radius fracture. *J Orthop Trauma* 2001;15:453-4.
- Gupta R, Bozentka DJ, Bora FW. The evaluation of tension in an experimental model of external fixation of distal radius fractures. *J Hand Surg [Am]* 1999;24:108-12.
- Jakim I, Pieterse HS, Sweet MB. External fixation for intra-articular fractures of the distal radius. *J Bone Joint Surg [Br]* 1991;73:302-6.
- Duncan SF, Weiland AJ. Minimally invasive reduction and osteosynthesis of articular fractures of the distal radius. *Injury* 2001;32 Suppl 1:SA14-24.

20. Ahlborg HG, Josefsson PO. Pin-tract complications in external fixation of fractures of the distal radius. *Acta Orthop Scand* 1999;70:116-8.

21. Klein W, Dee W, Rieger H, Neumann H, Joosten U. Results of transarticular fixator application in distal radius fractures. *Injury* 2000;31 Suppl 1:71-7.