



## An isolated sacral fracture and a fracture dislocation in two pediatric patients

### *İki çocuk hastada izole sakrum kırığı ve kırıklı çıkığı*

I. Erhan MUMCUOGLU, Mehmet ALBAYRAK, Gazi ZORER

*Istanbul Education and Research Hospital 1.Orthopaedics and Traumatology*

Çocuklarda izole sakrum kırığı son derece nadir görülen bir yaralanmadır. Sekiz ve 12 yaşlarında iki hastada düşmeye bağlı izole sakrum kırığı ve kırıklı çıkık saptandı. İki hastada da tip III kırık olmasına karşın nörolojik sorun görülmedi. Hastalara kırığın redüksiyonu için bir girişim yapılmadı ve kırıklar konservatif tedaviyle tümüyle iyileşti. Çocuklarda remodelasyon potansiyeli kendiliğinden iyileşme açısından önemlidir.

**Anahtar sözcükler:** Çocuk; çıkık/tanı; kırık/tanı/radyografi; manyetik rezonans görüntüleme; sakrum/yaralanma/tedavi/radyografi.

Isolated sacral fractures are very rare in children. Two children, aged eight and 12 years, presented with an isolated sacral type III fracture and a fracture dislocation, respectively, both of which were not associated with any neurologic problems. Without any attempts for reduction, the fractures healed completely with conservative treatment. These cases demonstrated a high remodeling potential in children for spontaneous healing.

**Key words:** Child; dislocations/diagnosis; fractures/diagnosis/radiography; magnetic resonance imaging; sacrum/injuries/therapy/radiography.

Literature on sacral fractures is very restricted. Many books on orthopedics and traumatology refer to sacral fractures in a few lines or a few paragraphs at most. However, sacral fractures present challenges both in diagnosis and treatment. In cases where it is accompanied with pelvic or vertebral fracture, sacral fracture mostly goes undiagnosed or incompletely treated. It is also known that sacral fractures may result in neurological injuries.<sup>[1,2]</sup> Although it is very rare to observe neurological problems with pelvic fractures when the sacrum was unaffected, all of the isolated sacral fractures have an evident neurological risk.<sup>[3]</sup> Permanent neurological injury attracts attention in the late period following the complete recovery of other more prominent injuries such as pelvic fractures.<sup>[1,2]</sup> As 5% of sacral fractures are accompanied with pelvic fracture, it is very common that neurological injury goes unrecognized.<sup>[4]</sup> Sacral fractures can be simply

unnoticed during radiological evaluation, which results from the fact that the sacrum is usually obscured by pelvic bones and soft tissue shadows of the intra-abdominal organs, and fractures are rarely disintegrated, and most of the time only anteroposterior radiography is ordered, but no lateral radiography.<sup>[5]</sup> Sacral fractures are very rare in children.<sup>[6-12]</sup>

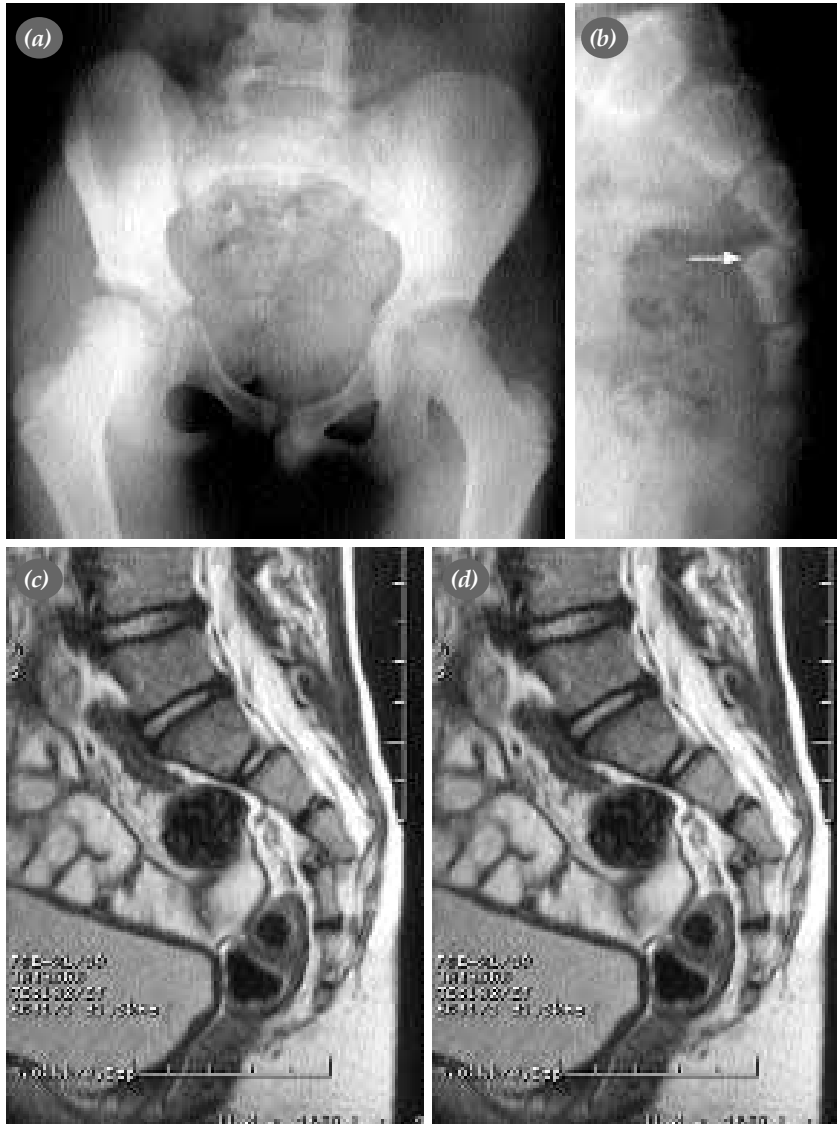This article reports isolated sacral fracture in two children.

### **Case reports**

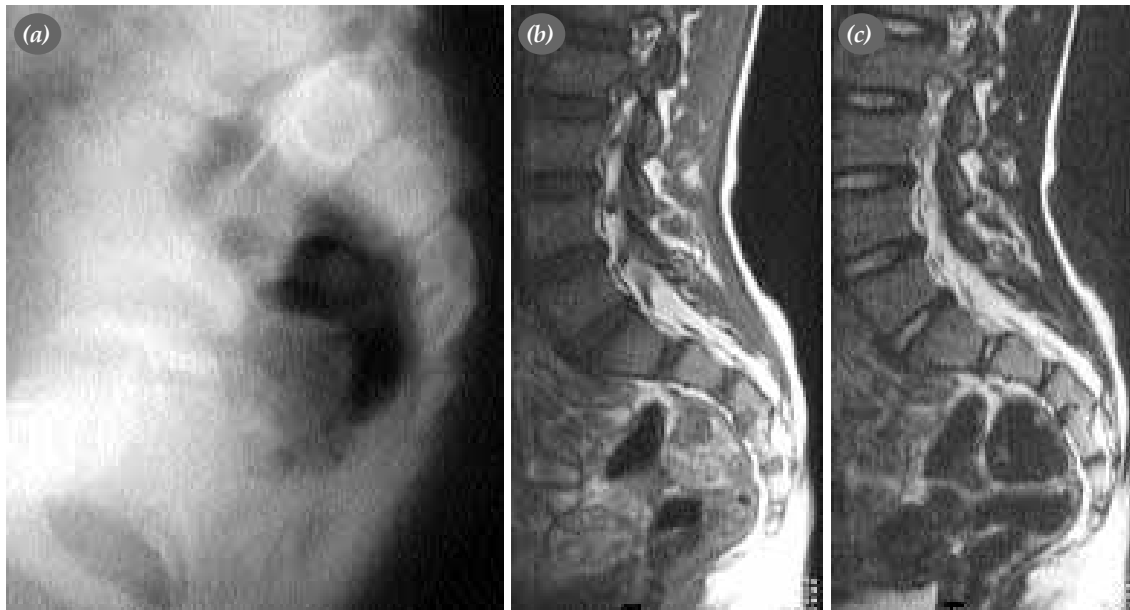**Case 1**– An eight-year-old boy who accidentally fell from stairs in sitting position presented to our emergency department. Patient was complaining about severe pain, and he could hardly walk. Physical examination revealed pain and palpable tenderness in the sacral region. No problem was found during the neurological evaluation, and

motor functions of both extremities were good; no urinary or anal incontinence was observed. Anteroposterior radiography showed no symptoms (Figure 1a); lateral radiography of the sacrum revealed type II epiphysiolysis according to the classification by Salter-Harris with an anterior displacement, forming a fracture-dislocation at the third vertebra of the sacrum (Figure 1b). Magnetic resonance imaging (MRI) gave the same results (Figure 1c, d). Distal end plate of the third sacral vertebra was disintegrated and displaced.

No stress was observed on the neurological structures. Patient didn't undergo rectal surgery for reduction; he was included in the follow-up program of the polyclinic after discharged from the hospital for bed-rest following two days of observation. At a three-months follow-up, his complaints were all relieved and his gait was improved. He had no complaints at a two-years follow-up; radiographic evaluation (Figure 2a) and MRI (Figure 2b, c) revealed full union of the fracture, and no stress was found on the neurological struc-



**Figure 1.** (a) Anteroposterior and (b) lateral radiographs of the pelvis. Type II epiphysiolysis according to the classification by Salter-Harris is evident in the third sacral vertebra, disintegrated with an anterior displacement, which was not evident in the anteroposterior radiography. (d, e) The T<sub>2</sub>-weighted sagittal magnetic resonance images reveal type II epiphysiolysis in the third sacral vertebra. No stress is observed on the neurological structures.

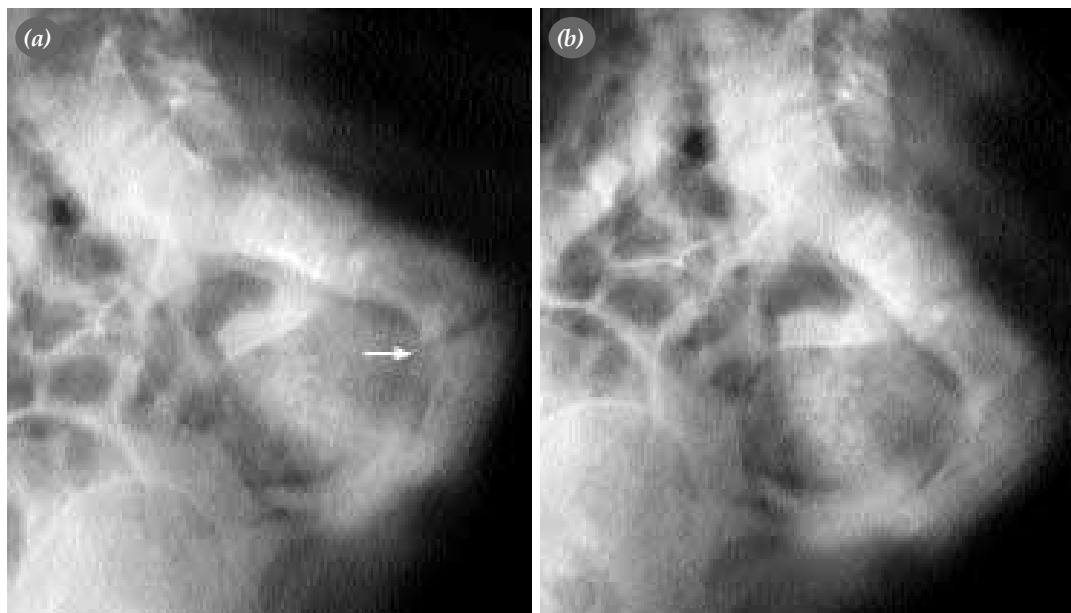


**Figure 2.** (a) Lateral radiography of the pelvis two years after the trauma, and (b, c) T2- weighted sagittal magnetic resonance images reveal complete union of the fracture.

tures.

**Case 2** – A twelve-year old girl with spastic quadriplegic cerebral palsy presented to the hospital due to swelling in the sacral region and complaints of pain emerging with contact. Her mother became aware of the swelling and pain in the bathroom, and it was reported that a few times she fell from the couch. Physical examination showed pain and pal-

pable tenderness in the sacral region. Muscular strength assessment couldn't be performed due to the joint contractures associated with cerebral palsy, however no symptoms were found in the sensation examination. Patient developed no urinary or anal incontinence. Lateral radiography of the pelvis showed a fracture with anterior angulation in the third sacral vertebra (Figure 3a). She was included in the follow-up program, and suggested a bed-rest. A



**Figure 3.** Lateral radiographs of the pelvis. (a) A fracture with frontal angulation is evident in the third sacral vertebra. (b) Complete union of the fracture is evident one year later.

two-months follow-up showed that swelling and pain were recovered, she could sit down without any complaints and physiotherapy for cerebral palsy could be easily given. A one-year follow-up showed that the radiographic evaluation of the patient, who had no complaints, revealed complete union of the fracture (Figure 3b).

## Discussion

Sacral fractures, often undiagnosed, rarely occur in adults, and they are very seldom in children. For a sacral fracture to occur, a high level of kinetic energy is required in children as it is in adults, and almost half of the sacral fractures are accompanied by pelvic fractures. However, fractures in our cases were associated with low-energy trauma, and restricted with the sacrum only. A comprehensive study about sacral fractures in adults showed that 30% of 776 pelvic injuries which were observed within 11 years had sacral fracture.<sup>[2]</sup> The most comprehensive study about sacral fractures in children demonstrated that incidence of sacral fractures was 0.6% among all children, and 4.76% among children with pelvic fracture.<sup>[1]</sup> Due to limited number of cases, no detailed information is available about its mechanism, natural course and convenient treatment.

Isolated sacral fracture is much more rare in children. To the best of our knowledge, it was reported only in five cases so far.<sup>[7,11,12-14]</sup> Among those cases, transverse sacral fractures were much more rare; and comprised only 5% of the all sacral fractures.<sup>[2,15]</sup> Fracture-dislocation in the sacrum has been reported only in one case up to now.<sup>[15]</sup>

First anatomic classification of the sacral fractures was made by Denis et al.<sup>[2]</sup> This classification divides sacral fractures into three based on the anatomic location of the fracture, taking the potential neurological injury into consideration: Zone I is the region remaining at the lateral of the neural foramina (sacral ala); Zone II, the region passing through the neural foramina (transforaminal); and Zone III, the region remaining at the medial of the neural foramina (spinal canal). Transverse fractures are also classified as Zone III fractures since they are involved in the spinal canal. According to the classification by Denis et al.<sup>[2]</sup> incidence of neurological injury is 6%, 28% and 58% in Zone I, Zone II and

Zone III fractures, respectively. Classifications by Sabiston-Wing and Schmidek cannot be adapted to the sacral fractures in children as the number of cases is very restricted and no statistical correlation exists between type of injury and neurological damage.<sup>[1]</sup> Likewise, it is not possible to make generalizations about the surgical indications in children with sacral fractures due to restricted number of patients. Neurological injuries and advanced deformities that cannot be associated with any other source may present indication for surgical decompression and/or stabilization.<sup>[1,7,11]</sup> In both of our cases, no neurological injury was found even though the fractures were transverse, i.e. zone III fractures.

It has been demonstrated that rectal surgery for reduction is not effective in sacral fractures with anterior angulation.<sup>[13]</sup> Although reduction can be advocated, considering that the fracture may not permit vaginal delivery of the girls when they are grown up, we believe that there would be a remodelling in the sacrum in any case, and that closed reduction of the transverse fractures, particularly near the proximal zone has potential to cause neurological injuries, and worsen the existing injury. However, we couldn't find any other study to compare our arguments. Anteroposterior radiographs of the pelvis may cause sacral fractures go unnoticed in children, as it is in adults.<sup>[1,2,9,12]</sup> Many fractures of the sacrum are undiagnosed, particularly in the pelvic traumas during childhood. Therefore, we would like to emphasize that any suspect for sacral fractures in children with pelvic fracture should be confirmed by lateral radiography and computed tomography, and by MRG in case of any neurological injury. In our first case, MRI analysis was made and no stress was found on the neurological structure even though the fracture was very evident in the lateral radiography. In the second case, no advanced analysis was done because of the spastic quadriplegic cerebral palsy.

In conclusion, we think that sacral fractures in children are not so rare as it is believed, but it is challenging to make the diagnosis. The key for diagnosis of the sacral fractures is being skeptic. Fracture of the sacrum should be suspected in the presence of ecchymosis and pain, pelvic instability, radiculopathy and/or urinary/anal incontinence in the sacral region and hips following a high-energy trauma, and engaged in necessary radiological analyses.

## References

1. Hart DJ, Wang MY, Griffith P, Gordon McComb J. Pediatric sacral fractures. *Spine* 2004;29:667-70.
2. Denis F, Davis S, Comfort T. Sacral fractures: an important problem. Retrospective analysis of 236 cases. *Clin Orthop* 1988;(227):67-81.
3. Schmidek HH, Smith DA, Kristiansen TK. Sacral fractures. *Neurosurgery* 1984;15:735-46.
4. Jones AL, Burgess AR. Fractures of the pelvic ring. In: Buchholz RW, Heckman JD, editors. *Rockwood and Green's fractures in adults*. 5th ed. Philadelphia: Lippincott Williams & Wilkins; 2001. p. 1469-512.
5. Canale ST, Beaty JH. Fractures of the pelvis. In: Beaty JH, Kasser JR, editors. *Rockwood and Wilkins' fractures in children*. 5th ed. Philadelphia: Lippincott Williams & Wilkins; 2001. p. 883-911.
6. Rodriguez-Fuentes AE. Traumatic sacrolisthesis S1-S2. Report of a case. *Spine* 1993;18:768-71.
7. Novkov HV, Tanchev PJ, Gyorev IS. Severe fracture-dislocation of S1 in a 12-year-old boy. A case report. *Spine* 1996; 21:2500-3.
8. Kewalramani LS, Tori JA. Spinal cord trauma in children. Neurologic patterns, radiologic features, and pathomechanics of injury. *Spine* 1980;5:11-8.
9. Rubel IF, Seligson D. Description of a rare type of posterior pelvis traumatic involvement: the green-stick fracture of the sacrum. *Pediatr Radiol* 2001;31:447-9.
10. Lam KS, Moulton A. Stress fracture of the sacrum in a child. *Ann Rheum Dis* 2001;60:87-8.
11. Kalra M, Anand S. Delayed sacral laminectomy for cauda equina in a child following fracture-dislocation of sacrum. *Injury* 1997;28:565-6.
12. Heckman JD, Keats PK. Fracture of the sacrum in a child. *J Bone Joint Surg [Am]* 1978;60:404-5.
13. Raissaki MT, Williamson JB. Fracture dislocation of the sacro-coccygeal joint: MRI evaluation. *Pediatr Radiol* 1999; 29:642-3.
14. Gutierrez PR, Mas Martinez JJ, Arenas J. Salter-Harris type I fracture of the sacro-coccygeal joint. *Pediatr Radiol* 1998; 28:734.
15. Suzuki K, Mochida J. Operative treatment of a transverse fracture-dislocation at the S1-S2 level. *J Orthop Trauma*