



# Arthroscopic selective capsular release in the treatment of frozen shoulder

## *Donuk omuz hastalığının tedavisinde artroskopik selektif kapsül gevşetmesi*

Mehmet Ugur OZBAYDAR, Murat TONBUL, Mehmet ALTUN, Okan YALAMAN

*Okmeydani Teaching Hospital, Orthopaedic Surgery Department, Istanbul*

**Amaç:** Donuk omuz hastalığında artroskopik selektif kapsül gevşetmesi ameliyatının sonuçları değerlendirildi.

**Çalışma planı:** Konservatif tedaviye dirençli donuk omuz tanısıyla 16 hastaya (5 erkek, 11 kadın; ort. yaş 51; dağılım 25-73) artroskopik kapsül gevşetmesi uygulandı. İki hastada donuk omuz travmaya bağlı oluşmuştu; dokuz hastada diabetes mellitus vardı; üç hastada herhangi bir etyolojik neden saptanmadı. İki hastada donuk omuzla birlikte rotator manşet tendiniti saptandı. Ameliyat öncesinde ortalama şikayet süresi 14 ay (dağılım 3-36 ay) idi ve ortalama 9.5 ay (dağılım 3-12 ay) konservatif tedavi uygulanmıştı. Omuz hareket açıklıkları gonyometre ile ölçüldü. Omuz fonksiyonları Amerikan Omuz ve Dirsek Cerrahları omuz değerlendirme formuna (ASES) göre değerlendirildi. Tüm hastalara genel anestezi altında artroskopik kapsül gevşetmesi, subakromiyal bursoskopi ve manipülasyon yapıldı. Subakromiyal sıkışma bulguları olan iki hastaya akromioplasti yapıldı. Ortalama izlem süresi 14 ay (dağılım 4-25 ay) idi.

**Sonuçlar:** Sağlam omuz ile karşılaştırıldığında, fleksiyonda ortalama %38, adduksiyon-dış rotasyonda %47, abduksiyon-iç rotasyonda %43 ve abduksiyon-dış rotasyonda %30 artış sağlandı. Ameliyat sonrasında infraspinatus, supraspinatus ve supskapularis kas güçlerindeki artış anlamlıydı ( $p<0.05$ ). Ameliyattan sonra ASES skoru ortalama 50 puan arttı ( $p<0.05$ ). Görsel ağrı skoru anlamlı düşüş gösterirken, günlük aktivite düzeyi anlamlı derecede yükseldi ( $p<0.05$ ). On dört hasta (%87.5) ameliyattan memnun olduğunu belirtti. Ağrı ve hareket kısıtlılığı ameliyattan sonra ortalama 3.5 ayda (dağılım 15 gün-12 ay) geçti.

**Çıkarımlar:** Konservatif tedavinin başarısız olduğu olgularda artroskopik selektif kapsül gevşetmesi ve manipülasyon donuk omuz tedavisinde etkin bir yöntemdir.

**Anahtar sözcükler:** Artroskopi; eklem kapsülü/cerrahi; eklem hastalığı/cerrahi; hareket açıklığı, eklem; omuz eklemi/yaralanma/cerrahi; sendrom.

**Objectives:** We evaluated the results of arthroscopic selective capsular release in patients with frozen shoulder.

**Methods:** Sixteen patients (5 males, 11 females; mean age 51 years; range 25 to 73 years) underwent arthroscopic capsular release for frozen shoulder. The syndrome was due to trauma in two patients; nine patients had diabetes mellitus; no etiologic cause was found in three patients. Two patients had rotator cuff tendinitis. The mean duration of complaints was 14 months (range 3 to 36 months). The patients were treated conservatively for a mean of 9.5 months (range 3 to 12 months). The range of motion of the shoulder was measured with a goniometer. Functional evaluations were made according to the American Shoulder and Elbow Surgeons Standardized Shoulder Assessment Form (ASES). Under general anesthesia, all the patients underwent arthroscopic capsular release, subacromial bursoscopy, and manipulation. Acromioplasty was performed in two patients with subacromial impingement. The mean follow-up was 14 months (range 4 to 25 months).

**Results:** Compared to the healthy side, postoperative increments in flexion, adduction-external rotation, abduction-internal and external rotations were 38%, 47%, 43%, and 30%, respectively. The strength of the infraspinatus, supraspinatus, and subscapularis muscles significantly increased ( $p<0.05$ ). The mean postoperative ASES score improved by 50 ( $p<0.05$ ). The mean visual analog scale score decreased significantly with significant improvements in daily activities ( $p<0.05$ ). Complaints of pain and limitation disappeared in a mean of 3.5 months (range 15 days-12 months) in 14 patients (87.5%) who were fully satisfied with the operation.

**Conclusion:** Patients with frozen shoulder unresponsive to conservative treatment can be effectively treated with arthroscopic selective capsular release and manipulation.

**Key words:** Arthroscopy; joint capsule/surgery; joint diseases/surgery; range of motion, articular; shoulder joint/injuries/surgery; syndrome.

Frozen shoulder is a painful stiffness which is still not fully understood but seen frequently. Frozen shoulder syndrome was first described by Dupley in 1872. Dupley used the term scapulohumeral peri-arthritis and suggested manipulation under anesthesia as treatment. Codman used the term frozen shoulder to describe this pathologic situation in 1934 and stated that most of the patients fully recovered with no treatment in two years. Neviaser used the term adhesive capsulitis based on cadaver and surgical findings of the patients he treated for the diagnosis of painful shoulder stiffness. Later, Zuckerman and Cuomo described frozen shoulder or adhesive capsulitis as a situation which had an unknown etiology and limited active and passive motions of shoulder with no intrinsic shoulder pathology. Primary frozen shoulder is used to describe the limitation of active and passive motion in all directions without no reason. Although it is regarded as a self limited disease in long term follow up it has been reported that some of the patients didn't regain normal motion. Secondary frozen shoulder is the stiffness of the shoulder which is described by a known cause such as trauma diabetes mellitus, cervical diseases, hyperthyroidism and ischemic heart diseases. The purpose of the treatment of the frozen shoulder is restore range of motion and relieved the pain.

There are non operative treatments such as physical therapy, intra articular steroid injection non steroid anti inflammatory drugs, and also there are surgical options such as open or arthroscopic soft tissue release procedures, manipulation under general anesthesia. Humeral fractures nerval injuries and dislocations are reported as serious complications due to manipulation under general anesthesia. The main problems of open procedures are wide dissection and rehabilitation difficulties following surgeries. Successful results are reported with arthroscopic procedures recently. With the arthroscopic technique, diagnosis and treatment diseases is obtained with minimum morbidity and also it gives the possibility to interfere with the other accompanying intraarticular pathologies. But there is still no consensus on the optimum treatment of frozen shoulder.

In this study, the results of capsular release procedure performed on the frozen shoulder patients were evaluated.

## Material and methods

16 patients out of 27 who were finally examined (5 male, 11 female, average age 51, ranging from 25-73), underwent arthroscopic capsular release with the diagnosis of frozen shoulder resistant to conservative treatment between 2001-2003 were enrolled in this trial. Cases with extraarticular pathologies were excluded from trial. Right shoulder in 10 patients, left in 6 patients, and dominant side involvement in 11 patients (68.8%) were present. Patients were classified by the method developed by Lundberg, based on the availability of a triggering factor. Consequently, the cases with no identified triggering factor, no other abnormal pathologic finding other than limitation in range of motion on examination and radiography and also the cases which are regarded as idiopathic were evaluated as primary. The cases with known intrinsic, extrensic or systemic pathology were classified as secondary frozen shoulder. The diseases determined like diabetes mellitus, hypothyroidism, hyperthyroidism, hypoadrenalism as systemic, cardiopulmonary diseases, cervical disc, cerebrovascular diseases, humeral fractures and parkinsonism as extrensic, rotator cuff tendinitis, rotator cuff tear, biceps tendinitis, calcified tendinitis, acromioclavicular arthrosis as intrinsic. 9 patients had diabetes mellitus (secondary, systemic). 2 patients had frozen shoulder due to trauma during invehicle traffical accident (secondary, extrensic). 1 of these patients had non displaced tuberculum majus fracture and one other had an anterior shoulder dislocation reduced closely. The patients had treated conservatively and frozen shoulder developed. In 2 patients rotator cuff tendinitis had determined in addition to frozen shoulder. (Secondary, intrinsic). In 3 patients no other etiologic reason had determined. (primary, idiopathic). During the follow up periods all the patients the system that include 3 phases which described by Reeves was used. The phases are: (i) painful phase (inflammatory) which continues 3-9 months and goes with generalise shoulder pain and increased shoulder stiffness. (ii) frozen phase which continue 4-12 and goes with persistent limitation in motion but relatively decreasing pain. (iii) Loosing phase which continues 12 to 20 months goes with improvement of the function gradually. The mean time of preoperative period of complaints was 14 months. (Range 3-36 months) Conservative treat-

ment, exercise program to continue on regaining range of motion and NSAID for pain control was applied to the patient mean time of 9,5 months (range 3-12) preoperatively. All the patients had at least 3 months of physical therapy. 6 patients who couldn't exercise due to pain had intraarticular steroid injection. Surgical therapy was planned for the patients who did not respond to rehabilitation program and had increasing shoulder stiffness during conservative therapy. It was agreed that the disease was in inflammatory phase for patients who had serious pain in addition to limitation of motion. The operation was not performed due to risk of capsular damage and limitation of motion, surgical treatment was postponed to frozen phase. Feeling of pain at the limits of range of motion (ROM) showed that the inflammatory phase ended and frozen phase began. Arthroscopis selective capsular release was applied to patients who did not respond to gentle close manipulation under general anesthesia and the reason for stiffness thought to be related with the capsul. The generalised extraarticular adhesions due to some surgical procedures or traumas had open release operation and these patients were not included in the study.

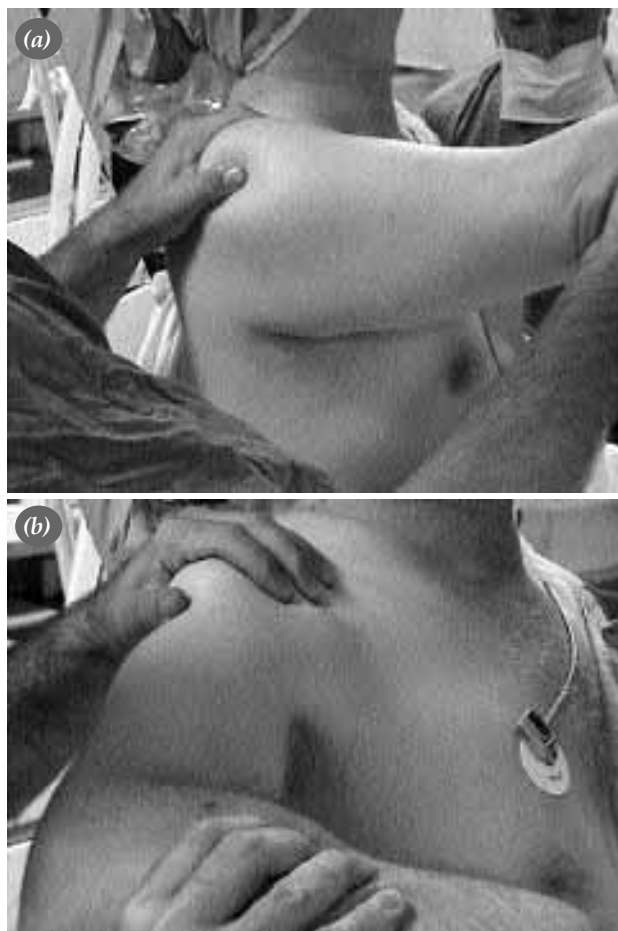In 2 patients who thought to have additional subacromial impingement syndrome gained anterior elevation was 70 degrees preoperatively. For this reason subacromial impingement sign of Neer, Hawkins-Kennedy, of the patients could not be evaluated, and Neer test could not be performed. Because of type 3 acromion according to the classification of Biglianni et al, in supraspinatus outlet graphies of patients; the cases which are suspected of subacromial impingement took the diagnosis subacromial impingement syndrome with inflammation and clear vision of anteroinferior of acromion in subacromial bursoscopy.

Shoulder range of motion was measured by goniometer. Muscular strenght determined manually. Shoulder functions were evaluated with the American Shoulder and Elbow Surgeons (ASES) score (maximum 100) and visual pain scala and daily activity of daily living. Postoperative mean follow up of patients was 14 months (range 4-25). T-test was used for statistical analysis.

### Operative Technique

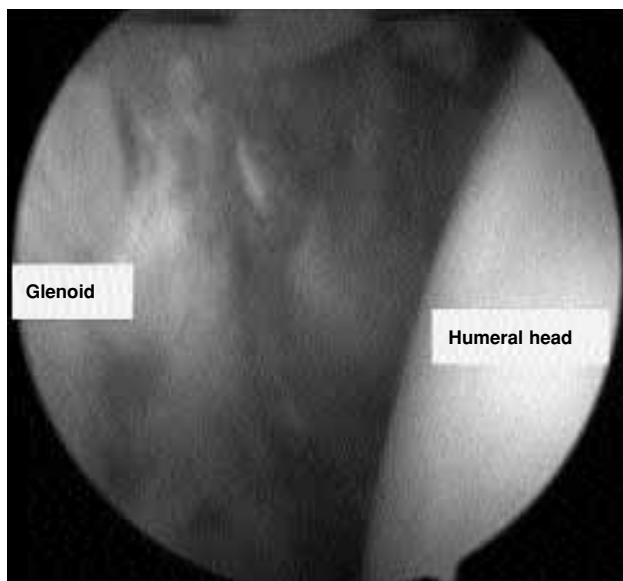Patients were operated on beach chair position

under general anesthesia. Passive range of motion was measured and recorded. Primarily gentle closed manipulation was applied. In unsuccessful cases, the joint was filled with sterile saline solution with the help of no 18 spinal needle by posterior approach. Scope was gentle pushed over humeral head through posterior portal without any harm to articular cartilage because of capsular contracture and decreased joint volume. Biceps tendon was found for reaching the superior border of rotator interval. Middle glenohumeral ligament released from labral border by motorised shaver and radiofrequency probe. Scar tissue surrounded subscapularis muscle was excised and subscapularis tendon was mobilised, when rotator interval region of capsul (from lower rim of biceps tendon to upper rim of subscapularis tendon) was shawed from thickened scar tissue. Coracohumeral ligament was released from coracoid adhesion point with the help of radiofrequen-

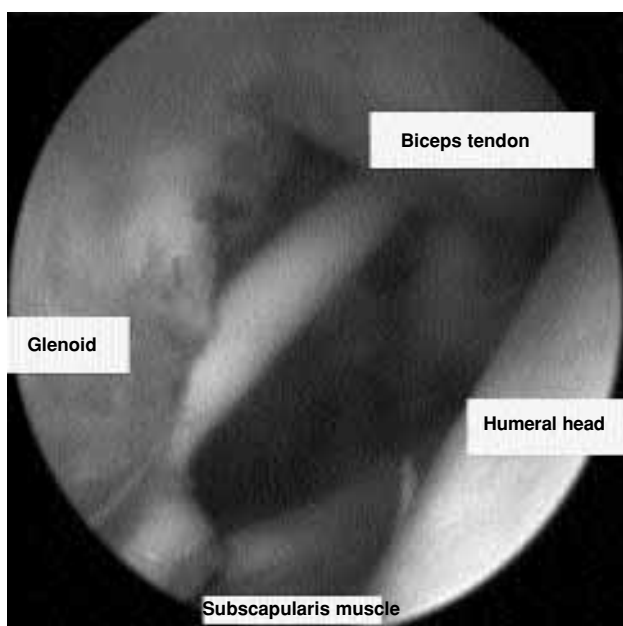


**Figure 1.** Preoperative examination under general anesthesia (a) Forward flexion (b) Restricted internal and external rotation.

cy probe. Thus supraspinatus tendon superiorly, subscapularis tendon inferiorly, rotator interval part of capsule up to inferiolateral of coracoid anteriorly were released surgically. Following the release, it was marked that most of the patients regained range of external rotation while arm was aside. Proliferative synovitis stayed usually under biceps tendon was shaved by motorized shavers intraarticularly and limited synovectomy was performed. Capsule was released from labrum anteroinferiorly



**Figure 2.** Thickened anterior capsule and scar tissue in rotator interval.



**Figure 3.** Rotator interval release.

to 5 o'clock position and where fibers of subscapularis muscle could be visualised, for the purpose of increasing external rotation range in abduction. At this point the care was taken to have subscapularis muscle as a buffer between anterior capsule and axillary nerve, not to harm axillary nerve while arm was in abduction. Additional pathologies were figured out by examining the joint. Bleeding control was provided by hypotensive anesthesia, pressured irrigation system and radiofrequency (RF) probe. Following release of rotator interval, manipulation was applied for examination and restoration of range of motion (ROM) in all directions. In the cases which external rotation (ER) was regained but internal rotation (IR), horizontal adduction and flexion could not be achieved, posterior capsular release was performed. For this purpose by changing portals over switching stick (SS), posterior capsule was released starting from posterior of origin of long head of biceps reaching to labrum at 9 o'clock position. Because of the close neighborhood of axillary nerve to inferior capsule diathermia and release as not applied to inferior capsule.

And then, using the same portal and additional lateral portal, subacromial bursoscopy was done. Adhesions were released by bursal debridement and rotator cuff was examined. The cases which thought as subacromial impingement syndrome, acromioplasty which was described by Ellman and modified by Altchek was performed. Then scope was taken out and inferior capsular release was completed with gentle manipulation by bringing arm to full elevation. It was determined that ROM in all directions was regained in examination. Postoperatively 10 ml. Marcaine was applied by catheter through anterosuperior portal. After closing the portals with 2.0 prolene sutures cryocuff and arm brace was put on.

Active and passive ROM exercises were started postoperatively. Patients took massive exercise program for 2 days. When they felt pain, marcaine was injected into the joint through catheter. Patients were discharged second day postoperatively.

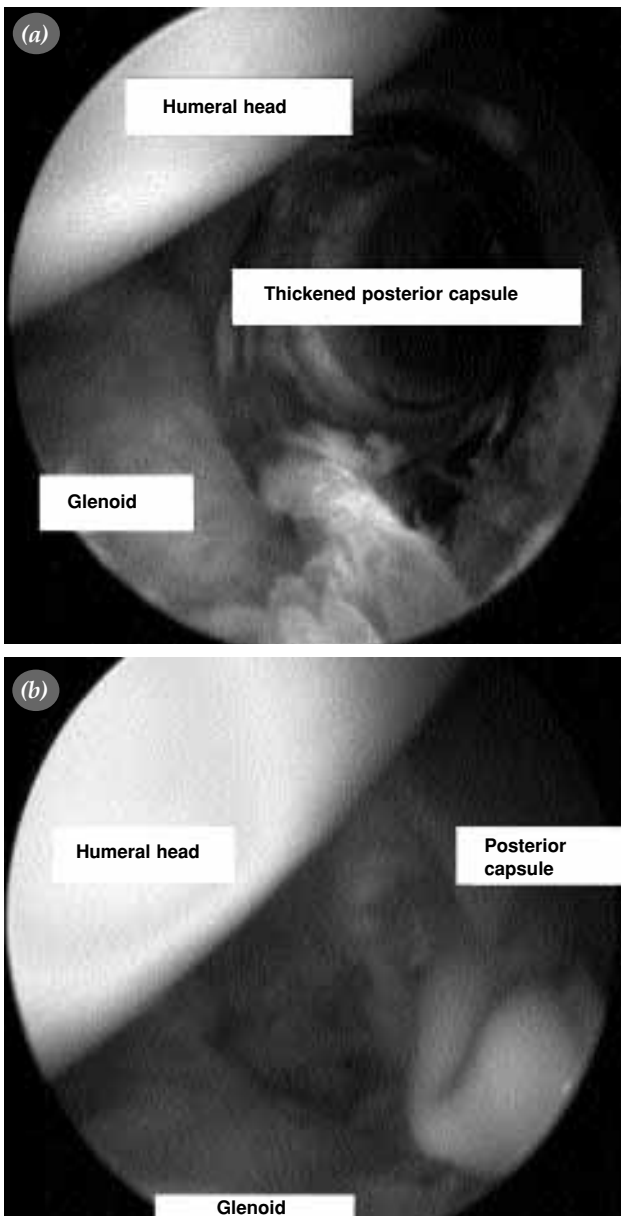
Patients whose stitches were taken at first week, were send to physical therapy (PT) clinic to join the specific rehabilitation program. In additoin to home exercise program performed under physiotherapist controle for 3 months in all patients, PT program accompanied by a physiotherapist mean 26 days

(range 10-60 days), was performed at 9 patients. Intermittant cold application NSAID were used for pain controle. Patients whose pain were not relieved central effecting analgesics were taken into consideration.

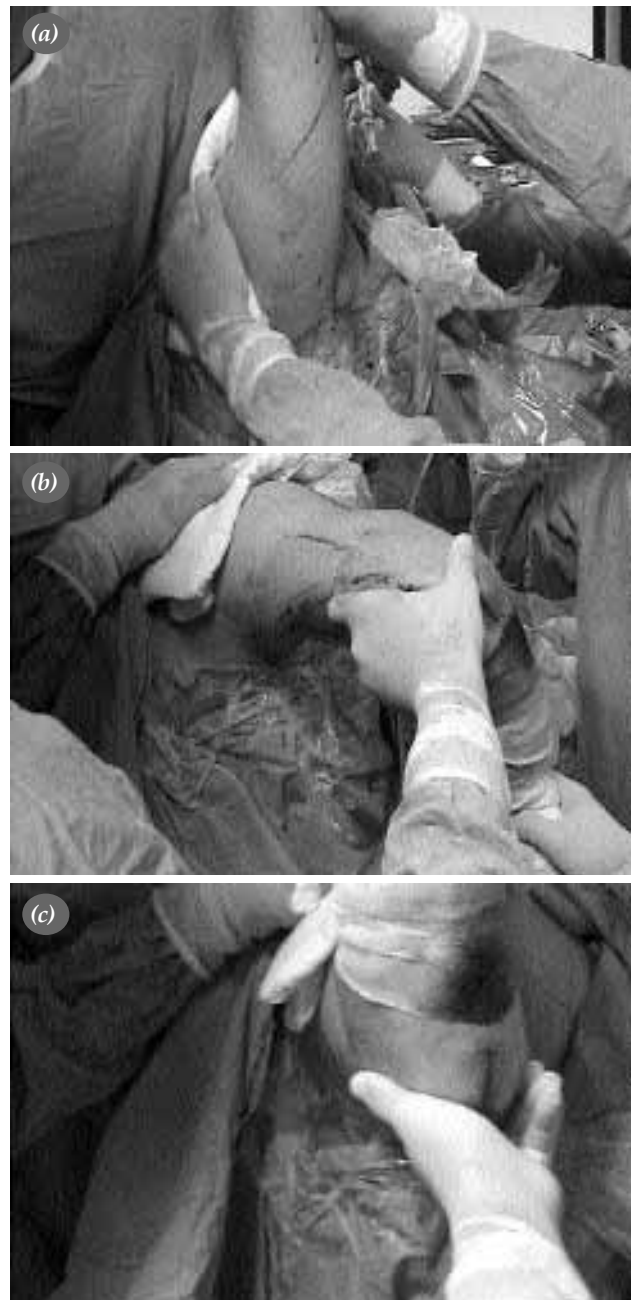
**Results**

Anterior capsular release was performed in all patients. In 10 patients whose internal rotation horizontal adduction and elevation was not yet achieved, while examination after applied manipulation, addi-

tional posterior capsular release was performed. In all patients proliferative synovitis was seen under the insertio of biceps tendon inside the joint. Limited synovectomy was performed on these patients. Subacromial bursoscopy was applied to the patients after glenohumeral arthroscopy. In 2 patients while bursoscopy, inflammation in bursa at subacromial space and clarity in anteroinferior part of acromion



**Figure 4.** (a) Arthroscopic view of thickened posterior capsule. (b) Posterior capsular release



**Figure 5.** Postoperative range of motion (a) Forward flexion, (b) abduction-external rotation (c) abduction-external rotation.

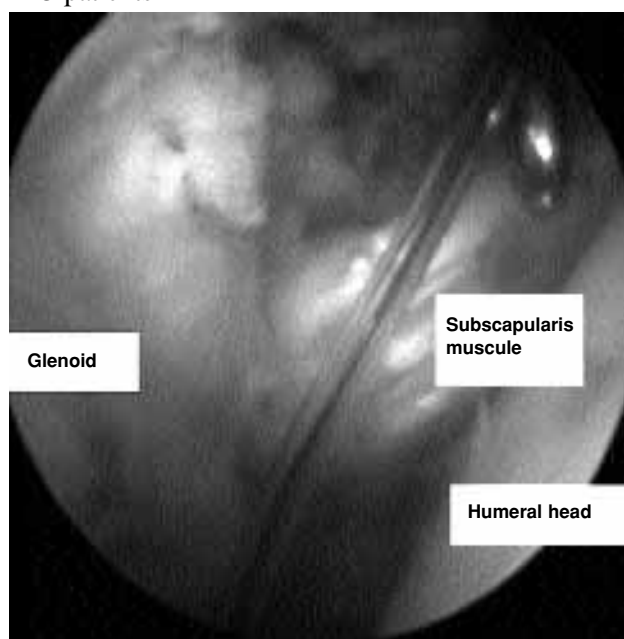
**Table 1.** Preoperative and postoperative functional and statistical results

	Preoperative	Postoperative	<i>p</i>
<b>Motion</b>			
Forward flexion	94° (70-140°)	160° (120-170°)	<0.05
Adduction-external rotation	26° (-20 - 70°)	59° (20-80°)	<0.05
Abduction-external rotation	29° (0-90°)	59° (40-90°)	<0.05
Abduction-internal rotation	36° (0-80°)	66° (30-170°)	<0.05
<b>Muscle strength(manuel/max 5)</b>			
Infraspinatus	3.3 (1-5)	4.3 (4-5)	<0.05
Supraspinatus	3.3 (1-5)	4.3 (4-5)	<0.05
Supscapularis	3.4 (1-5)	4.3 (4-5)	<0.05
<b>ASES score</b>			
Visual pain scale	4.8	0.7	<0.05
Daily activity	8.3	26.6	<0.05

was determined. Acromioplasty was performed in addition to capsular release on these patients. Rotator cuff (rc) tear was not determined on none of these patients.

Compared to ROM of healthy shoulder, improvement was 38% in flexion 47% in adduction external rotation, 43% abduction internal rotation, 30% abduction ER (table-1).

Preoperatively adduction-IR was at the level of PSIS in 7 patients, L<sub>1</sub> in 4 patients, T<sub>12</sub> in 2 patients, T<sub>7</sub> in 3 patients. Postoperatively it was at the level of PSIS in 1 patient, T<sub>12</sub> in 3 patients, T<sub>7</sub> in 7 patients, T<sub>4</sub> in 5 patients

**Figure 6.** Catheter placement into glenohumeral joint

Postoperatively muscle strength improvement in infraspinatus(IS) and subscapularis (SubS) was meaningful.

Postoperatively mean 50 points (range 5-80) improvement on ASES score ( $p < 0.05$  table1) was noted. While usual pain score was meaningfully decreased, daily activity score (DAS) increased meaningfully. 14 patients (%87.5) pointed out happiness with the results. Complaints of pain and limitation in motion which was present preop, totally recovered in these patients in mean 3.5 months (range 15 days-12months) postop.

In one patient anterior luxation which occurred during active-passive exercises first day following the operation was corrected by close reduction. In this patient postop exercise program was modified and slower rehab program was applied. On last follow-up it was noted that joint motion was in normal range and ASES score was improved to 90 which was 50 preop.

One of the patient who was unhappy with the treatment was a 58 years old diabetic female. Patient's complaint was the continuation of pain and limitation in ROM. Her unhappiness was tied up to irregularity of blood sugar level and uncongeniality to exercise program. The other one was a 25 years old male patient etiologically there was a trauma ending with undisplaced greater tuberosity fracture of right shoulder due to invehicle traffic accident. Because of his proficiency (textile worker) he had to use his arm continuously. The patient complaint was, although the ROM was improved, the feeling of pain while he was doing hard work. While examining the patient no spe-

**Table 2.** Preop and postop range of motion according to etiology

	Preop (°)	Postop (°)
Primer (idiopathic) (n=3)		
Forward flexion	86.6 (70-100)	151.6 (135-170)
Abduction-internal rotation	28.3 (25-30)	55 (30-90)
Abduction-external rotation	26.6 (40-70)	53.3 (40-70)
Adduction-external rotation	13.3 (-20 - 45)	40 (20-50)
Diabetes (seconder/sistemic) (n=9)		
Forward flexion	102.7 (70-140)	155.5 (130-170)
Abduction-internal rotation	31.1 (0-70)	64.4 (40-90)
Abduction-external rotation	25.5 (0-45)	59.4 (40-90)
Adduction-external rotation	30 (-20 - 70)	58.8 (30-80)
Trauma (seconder/extrinsic) (n=2)		
Forward flexion	90 (80-100)	150 (130-170)
Abduction-internal rotation	50 (20-80)	60 (50-70)
Abduction-external rotation	50 (10-90)	60 (40-80)
Adduction-external rotation	27.5 (10-45)	70
+ Subacromial impingement(seconder/intrinsic) (n=2)		
Forward flexion	70	145 (120-170)
Abduction-internal rotation	65 (50-60)	62.5 (35-90)
Abduction-external rotation	25 (20-30)	65 (40-90)
Adduction-external rotation	27.5 (10-45)	75 (70-80)

sific pathology for the reason of pain was noticed.

The patients was grouped due to etiological reasons and findings were evaluated. In 3 patients, who were thought to be primary (idiopathic) and had no determined etiological reason, add-IR range was found at level T<sub>12</sub>, T<sub>7</sub>, T<sub>4</sub> which were preop L<sub>1</sub>,PSIS,PSIS.

In 9 patients who were classified as secondary –systemic frozen shoulder and had diabetes, add-IR range was PSIS for 4 patients, L<sub>1</sub> in 3 patients, T<sub>12</sub> in one, T<sub>7</sub> in one one patient preop. It improved to the level of PSIS in one, T<sub>12</sub> in one, T<sub>7</sub> in 5, T<sub>4</sub> in 2 patients postop.

ASES score which was mean 37.7(range 15-64) was 89.4 (range 60-100) postop. In 2 patients who were clasified as secondary extrensec and had trauma story, add-IR range was PSIS and T<sub>7</sub> preop and found T<sub>4</sub>,T<sub>7</sub> postop. ASES score which was 57 (range 56-58) preop improved to 89 (range 78-100) postop. In 2 patients who were classified as secondary-intrensec frozen shoulder and thought to have subacromial

impingement together with frozen shoulder, add:IR range was T<sub>12</sub> and PSIS preop and found T<sub>12</sub>-T<sub>4</sub> postop. Also ASES score rised from 42,5 (range 33-52) to 82,5(range 65-100).

## Discussion

Frozen shoulder is a disease that can usually be treated by physical therapy methods, causes pain effects daily activities negatively and may restrict shoulder functions drastically. Griggs et al.in a prospective study which non opertaive treatment results of idiopathic adhesive capsulitis were investigated, reported succesful results with specific shoulder stretching exercise program. In most of the patients with stage 2 idiopathic adhesive capsulitis. However Shaffer et al. in a study which long term (mean 7 years) objective and subjective results of patients treated non opertaively for idiopathic frozen shoulder were evaluated, found that half of the patients were symptomatic on final examination. Frozen shoulder which is not classified etiologycally yet, although it was seen to be benign and self cured disease, it negatively effetcs

daily living activities by causing long term pain and limitation in motion for this reason treatment of this disease is important it has been treated by activity modification NSAID, local oral corticosteroids, PT, manipulation under anesthesia open or arthroscopic surgery. Dodenhoff et al. prospectively studied the effects of manipulation under anesthesia for 39 shoulders of 37 patients having frozen shoulder, for cure and return to previous activity, reported that 94% of the patients were happy with the treatment.

Although manipulation under anesthesia was successful in some of the patients, it was reported that this method had complications like humeral fractures, nerve injuries and shoulder dislocation. Patient did not benefit from manipulation. Open soft tissue release together with subscapularis lengthening was suggested during arthroscopic capsulotomy anatomic structures can be visualised directly and controlled release can be performed. Exercises can be initiated short term postop. A lot of successful outcomes reported with arthroscopic capsular release on frozen shoulder treatment but there is still no consensus over the applied surgical technique. Many different arthroscopic capsular release techniques are performed on frozen shoulder treatment. Pollock et al. performed arthroscopic debridement on subacromial space and glenohumeral joint after manipulation under general anesthesia. Beaufils et al. performed anterior and anteroinferior release after manipulation on 26 patients of whom 13 was primary. Harryman et al. described 360 degrees arthroscopic release technique and performed subacromial debridement on 30 patients of whom 14 were diabetic, reported the motion range of treated shoulders reached 93% of the opposite side and average 33 months follow up. Ogilvie-Harris and Myerthall described anteroinferior capsulotomy technique on diabetic patients. Pearsall et al. suggested cutting of intraarticular part of subscapularis tendon in addition to anteroinferior capsulotomy and reported that subacromial debridement was needed in 44% of the patient.

Some authors, reported 83% successful results and average 22 months follow up on 43 patients in whom arthroscopic anteroinferior capsular release was performed. They examined arthroscopically glenohumeral joint and subacromial space of all the

patients and faced with fibrosis which required debridement in 18 patients. And also they performed acromioplasty in patients having anterior acromial osteophytes. Warner et al. reported that rotator interval was loosened in 18 of 23 patients having idiopathic adhesive capsulitis, anteroinferior capsulotomy was done in 5 patients, acromioplasty was needed in 7 of these patients and noted that variation in joint ROM was meaningful in mean 39 months follow up. Segmuller et al. achieved 88% successful result in average 13,5 month follow up, in 26 shoulders of 26 patients whose arthroscopic inferior capsular release was performed. Berghs et al. reported that they performed arthroscopic anterior and posterior capsular release and released inferior capsule by manipulation. Akpınar et al. followed 16 patients whom 360 degrees arthroscopic release was performed for average of 17 months and reported average 47 points improvement constant score. In our study with selective capsular release and manipulation we achieved improvement in average 50 points (range 5-80) on ASES score, 66 degrees (0-100) fore flexion, 33 degrees (5-60) in add:ER, 30 degrees (5-85) in abd:ER, and 30 degrees (0-160) in abd:IR postop. The changes in ASES scores were meaningful ( $P < 0,05$ ) 87,5 % were happy with the treatment when classified according to etiological reasons it was notified that the procedure was effective in increasing ROM at all groups, but subjective pain scores and patient satisfaction was lower in diabetic (secondary, systemic) and trauma (secondary, extrinsic) cases in our study patients evaluated separately and arthroscopic technique was performed differently according to determined pathology preop and perop. We think that performing controlled manipulation together with selective capsular release may overcome the disadvantages seen when performing each of the methods separately. Thus fractures which was happened during closed manipulation may be lessened by capsular release and the occurrence of complications like axillary nerve lesion may be prevented by performing capsular release selectively. It was reported that complications like axillary nerve and artery injuries, dislocations may develop during arthroscopic release. In our study anterior dislocation occurred in 1 patient 6,3% and closed reduction was performed. In this patient postoperative exercise



program was modified and slower rehab was applied. On final examination it was noted that this ASES score was improved to 90 which was 50 preop and joint ROM was normal. No artery nor vein injury was seen.

In our study postop intraarticular catheter was applied for pain relief of patients. In this case we shall consider the fact that during early rehabilitation period excessive force may be applied in pain reduced patient. Which may be a cause of shoulder dislocation. This complication prevented by not access the recorded perop ROM, during the rehab. The weak parts of this study were, small number, heterogen distribution, and short follow up of the patients. But postop morbidity may be reduced by performing arthroscopic capsular release with controlled manipulation in various degrees according to pathological signs of frozen shoulder patients and succesful results may be obtained by aggressive rehab in short term.

The results of our study are congenial to similar studies. Frozen shoulder should primarily be treated non operatively. Although some of the patients recovered by the time, some others continue to suffer from the symptoms. In despicable part of succesful outcome is postop pain controle and congenial rehab. The main advantages of arthroscopic capsular release are shorter rehab period, lower risk of humeral fracture and postop intraarticular bleeding. The diagnosis, treatment of the disease and additional pathologies are possible diagnosis, treatment of the disease and additional pathologies are possible with arthroscopic capsular release method in patients whom conservative treatment had been unsuccessful.

## References

1. Azar MF. Shoulder and elbow injuries. In: Canale ST, Campbell WC, editors. *Campbell's operative orthopaedics*. 10th ed. St. Louis: Mosby; 2003. p: 2339-75.
2. Neer SC. *Shoulder reconstruction*. Philadelphia: W. B. Saunders; 1990.
3. Neviasser TJ. Adhesive capsulitis. In: McGinty JB. *Operative arthroscopy*. 2nd ed. Philadelphia: Lippincott-Raven; 1996. p. 785-93.
4. Zuckerman JD, Cuomo F. Frozen shoulder. In: Matsen FA 3rd, Fu FH, Hawkins RJ, editors. *The shoulder: a balance of mobility and stability*. Rosemont, IL: American Academy of Orthopaedic Surgeons; 1993. p. 253-67.
5. Shaffer B, Tibone JE, Kerlan RK. Frozen shoulder. A long-term follow-up. *J Bone Joint Surg [Am]* 1992;74:738-46.
6. Harryman DT 2nd, Matsen FA 3rd, Sidles JA. Arthroscopic management of refractory shoulder stiffness. *Arthroscopy* 1997;13:133-47.
7. Holloway GB, Schenk T, Williams GR, Ramsey ML, Iannotti JP. Arthroscopic capsular release for the treatment of refractory postoperative or post-fracture shoulder stiffness. *J Bone Joint Surg [Am]* 2001;83:1682-7.
8. Ogilvie-Harris DJ, Myerthall S. The diabetic frozen shoulder: arthroscopic release. *Arthroscopy* 1997;13:1-8.
9. Griggs SM, Ahn A, Green A. Idiopathic adhesive capsulitis. A prospective functional outcome study of nonoperative treatment. *J Bone Joint Surg [Am]* 2000;82:1398-407.
10. Segmuller HE, Taylor DE, Hogan CS, Saies AD, Hayes MG. Arthroscopic treatment of adhesive capsulitis. *J Shoulder Elbow Surg* 1995;4:403-8.
11. Pearsall AW 4th, Osbahr DC, Speer KP. An arthroscopic technique for treating patients with frozen shoulder. *Arthroscopy* 1999;15:2-11.
12. Watson L, Dalziel R, Story I. Frozen shoulder: a 12-month clinical outcome trial. *J Shoulder Elbow Surg* 2000;9:16-22.
13. Lundberg BJ. The frozen shoulder. Clinical and radiographical observations. The effect of manipulation under general anesthesia. Structure and glycosaminoglycan content of the joint capsule. Local bone metabolism. *Acta Orthop Scand Suppl* 1969;119:1-59.
14. Cuomo F. Diagnosis, classification and management of the stiff shoulder. In: Iannotti JP, Williams GR Jr, editors. *Disorders of the shoulder: diagnosis and management*. Philadelphia: Lippincott Williams & Wilkins; 1999, p. 397-41.
15. Reeves B. The natural history of the frozen shoulder syndrome. *Scand J Rheumatol* 1975;4:193-6.
16. Neer CS 2nd. Anterior acromioplasty for the chronic impingement syndrome in the shoulder: a preliminary report. *J Bone Joint Surg [Am]* 1972;54:41-50.
17. Hawkins RJ, Kennedy JC. Impingement syndrome in athletes. *Am J Sports Med* 1980;8:151-8.
18. Bigliani LU, Morrison DS, April CS. The morphology of the acromion and its relationship to rotator cuff tear [Abstract]. *Orthop Trans* 1986;9:48.
19. Ellman H. Arthroscopic subacromial decompression: analysis of one- to three-year results. *Arthroscopy* 1987;3:173-81.
20. Altchek DW, Warren RF, Wickiewicz TL, Skyhar MJ, Ortiz G, Schwartz E. Arthroscopic acromioplasty. Technique and results. *J Bone Joint Surg [Am]* 1990;72:1198-207.
21. Moskal MJ, Harryman DT 2nd, Romeo AA, Rhee YG, Sidles JA. Glenohumeral motion after complete capsular release. *Arthroscopy* 1999;15:408-16.
22. Bennett WF. Addressing glenohumeral stiffness while treating the painful and stiff shoulder arthroscopically. *Arthroscopy* 2000;16:142-50.
23. Dodenhoff RM, Levy O, Wilson A, Copeland SA. Manipulation under anesthesia for primary frozen shoulder: effect on early recovery and return to activity. *J Shoulder Elbow Surg* 2000;9:23-6.
24. Warner JJ, Allen A, Marks PH, Wong P. Arthroscopic release for chronic, refractory adhesive capsulitis of the shoulder. *J Bone Joint Surg [Am]* 1996;78:1808-16.
25. Ozaki J, Nakagawa Y, Sakurai G, Tamai S. Recalcitrant chronic adhesive capsulitis of the shoulder. Role of contracture of the coracohumeral ligament and rotator interval in pathogenesis and treatment. *J Bone Joint Surg [Am]* 1989; 71:1511-5.

26. Pollock RG, Duralde XA, Flatow EL, Bigliani LU. The use of arthroscopy in the treatment of resistant frozen shoulder. *Clin Orthop Relat Res* 1994;(304):30-6.
27. Beaufils P, Prevot N, Boyer T, Allard M, Dorfmann H, Frank A, et al. Arthroscopic release of the glenohumeral joint in shoulder stiffness: a review of 26 cases. *French Society for Arthroscopy. Arthroscopy* 1999;15:49-55.
28. Harryman DT 2nd, Matsen FA 3rd, Sidles JA. Arthroscopic management of refractory shoulder stiffness. *Arthroscopy* 1997;13:133-47.
29. Berghs BM, Sole-Molins X, Bunker TD. Arthroscopic release of adhesive capsulitis. *J Shoulder Elbow Surg* 2004;13:180-5.
30. Akpınar S, Ozalay M, Hersekli MA, Ozkoc G, Tandogan RN. Arthroscopic capsular release for frozen shoulder. [Article in Turkish] *Acta Orthop Traumatol Turc* 2003;37:213-8.