



## Quadriceps tendon ruptures: Evaluation and treatment

### *Kuadriseps tendonu kopmalarında değerlendirme ve tedavi*

Cem Zeki ESENYEL, Kahraman OZTURK, Kamil CETINER, Ridvan YESILTEPE, Ayhan Nedim KARA

*Vakıf Gureba Training and Research Hospital, Department of Orthopedics and Traumatology, Orthopaedic Surgeon*

**Amaç:** Kuadriseps tendonunda (KT) kopma nedeniyle cerrahi tedavi uygulanan olgular değerlendirildi.

**Çalışma planı:** Dördü erkek, biri kadın beş hastada (ort. yaş 56, dağılım 33-77) KT kopması görüldü. Bir hastada iki taraflı kopma vardı. Bir hastada trafik kazası, iki hastada düşme nedeniyle oluşan kopmalar, kronik böbrek hastalığı nedeniyle diyaliz tedavisi görmekte olan iki olguda belirgin bir travma olmaksızın ortaya çıkmıştı. Tüm hastalarda KT patella üst kutbundan kopmuştu. Tamir patellaya açılan tünellerden geçirilen erimeyen ipliklerle yapıldı. İzlem süresi ortalama 2 yıl (dağılım 1-5 yıl) idi.

**Sonuçlar:** Tendon tamirinden altı ay sonra tüm hastalarda tam iyileşme sağlandı. Ortalama hareket açıklığı sınırları 0-119° idi. Hiçbir hastada belirgin kas atrofisi gelişmedi. Kas güçleri sağlam tarafla eşit bulundu. Hiçbir hastada patellofemoral ağrı görülmedi.

**Çıkarımlar:** Kuadriseps tendonunda kopmalar erken tanı ve cerrahi tedavi ile başarılı bir şekilde onarılabilir. Kırk yaşından sonra başka bir hastalığın da tendon kopmasına zemin hazırlayabileceği göz önüne alınmalıdır.

**Anahtar sözcükler:** Diz yaralanması; patella/yaralanma; hareket açıklığı, eklem; yırtılma/cerrahi; tendon yaralanması/cerrahi.

**Objectives:** We evaluated the patients who underwent surgical repair for rupture of the quadriceps tendon.

**Methods:** Five patients (4 men, 1 woman; mean age 56 years; range 33 to 77 years) had rupture of the quadriceps tendon at the osteotendinous junction. One patient had bilateral rupture. Etiology was a traffic accident in one patient, and fall from height in two patients. Two patients who were on dialysis treatment developed simultaneous bilateral rupture. Ruptures were repaired with heavy, nonabsorbable sutures placed in transosseous tunnels in the patella. The mean follow-up was two years (range 1 to 5 years).

**Results:** Complete healing was seen in all the patients within six months. The mean range of motion was 0 to 119 degrees. Muscle atrophy was not detected. Muscle strength was equal on both sides. None of the patients complained of patellofemoral pain.

**Conclusion:** Ruptures of the quadriceps tendon can be successfully managed through early diagnosis and surgical treatment. It should be recalled that concomitant diseases may predispose to ruptures in cases above 40 years of age.

**Key words:** Knee injuries; patella/injuries; range of motion, articular; rupture/surgery; tendon injuries/surgery.

The quadriceps tendon rupture is a rarely seen injury requires prompt diagnose and treatment. Normally the tendon of quadriceps has a structure which can carry quiet big forces. Even though the extensor mechanism consisted of quadriceps' tendon, patella and the tendon of patella is under heavy pressure, rupture of the tendon of quadriceps is gen-

erally not seen. Fatty and cystic degeneration of tendons, mixed degeneration, microangioblastic dysplasia, decrease in collagen and calcification occurs by age. These structural changes weaken the tendon. Despite all these changes, rupture of QT is a rarely seen injury even in elder population.<sup>[1]</sup>

**Correspondance to:** Dr Cem Zeki Esenyel. Vakıf Gureba Training and Research Hospital, Department of Orthopedics and Traumatology, Orthopaedic Surgeon, Adnan Menderes Bulvarı, 34296 Fatih, Istanbul.

Phone: +90 212 - 534 69 00 / 1732 Fax: +90 212 - 635 14 80 e-mail: esenyel@yahoo.com

**Received:** 17.06.2004 **Accepted:** 12.02.2005

The presence of rupture by a micro trauma or its presence in elder people indicates the essential role of degeneration in pathophysiology.<sup>[2-4]</sup> Also, chronic kidney failure, hyperglycemic diabetes, rheumatoid arthritis, hyperparathyroidism, various connective tissue disorders, systemic use of steroids or intra-articular steroid administration are the conditions which facilitate the rupture of the tendon of quadriceps.<sup>[3-9]</sup> 20% of the rupture of the tendon of quadriceps occurs in the patients who have above mentioned conditions.<sup>[4]</sup> The diagnosis is done mostly by anamnesis and physical examination. Pain, insufficient active knee extension, suprapatellar fissure are the important symptoms for diagnosis. Pain is sudden and severe. The resting of knee at extension relieves the pain. In examination, weakness is observed at the active extension of knee. Intraarticular aspiration and intraarticular local anesthetic administration allow the assessment of extensor mechanism by relieving the pain. Typically, active knee flexion is preserved. Despite all these obvious signs and symptoms, the rupture of QT may be missed. Hemarthrosis formed may mask the fissure. If the fissure is hidden by the hemarthrosis, patient may be laid in supine position while hip is at flexion to widen the defect at rupture site due to the active contraction of rectus femoris muscle. The radiological procedures for the diagnosis are direct radiography, arthrography, ultrasound and magnetic resonance imaging (MRI).<sup>[3,10-13]</sup> MRI and ultrasound replaced arthrography in recent years because of being non-invasive interventions. The sensitivity of ultrasound in determining the localization of the rupture is high. It is also quite sensitive in differentiation of complete or partial ruptures. Magnetic resonance is the most effective imaging method.<sup>[11-13]</sup>

Many techniques are described for repairing the tendon in the literature.<sup>[14,15]</sup> Most frequently used method is end to end fixation of the tendon by the sutures through the channels opened at patella. Repairing with carbon fibers and synthetic vessel grafts are also reported.<sup>[14]</sup> However, superiority of any of these techniques to the other could not be shown.<sup>[4]</sup>

In this trial, the results of the treatment with primary repairing in the rupture of quadriceps' tendon are assessed.

## Patients and methods

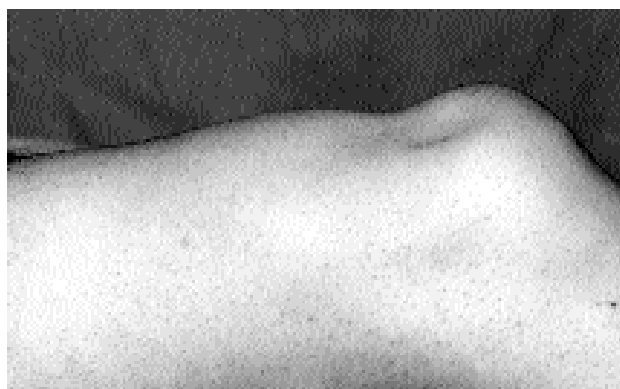
5 patients (4 males, 1 female, average age is 56, distribution of age 33-77) recruited to this trial that were operated at 1995-2002 for the rupture of the tendon of quadriceps. Bilateral rupture existed in one of the patients.

The reason for the injury was traffic accident in one patient and falling on knee in two. The other two patients who had no trauma story were on hemodialysis due to chronic kidney failure.

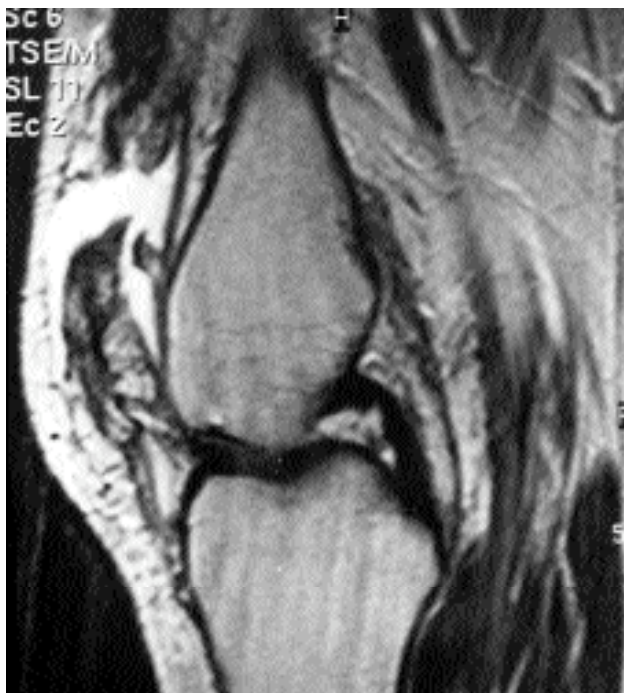In physical examination, difficulty in walking was observed and fissure at the top of the patella was palpated (figure 1). Patients could not perform active knee extension.

Any bone pathology was observed radiographically. Rupture of the tendon of the quadriceps at the upper pole of patella was observed in MRI (figure 2). All patients treated surgically.

Surgical technique: Tendon was revealed by mid-line incision (figure 3a). The proximal end of the tendon of quadriceps was cut till the intact part of the tendon. The residue of the tendon at the upper pole of patella was cleaned. A transverse fissure was formed at the superior of the patella. In order to prevent the tilting of patella, this fissure was prepared not close to the anterior surface. 2 or 3 vertical and parallel holes 1 cm apart to each other was opened at somewhere close to the base of this fissure. Nodes locking each other were made at the lateral and medial parts of the tendon by 5 numbered nonabsorbable strings. The free ends of the strings were passed through the holes dig on patella. The proximal endings of the strings were attached by hemostat



**Figure 1.** The fissure at suprapatellar site is being seen in physical examination.



**Figure 2.** The rupture of tendon of quadriceps at the site of adhesion to the patella in MRI.

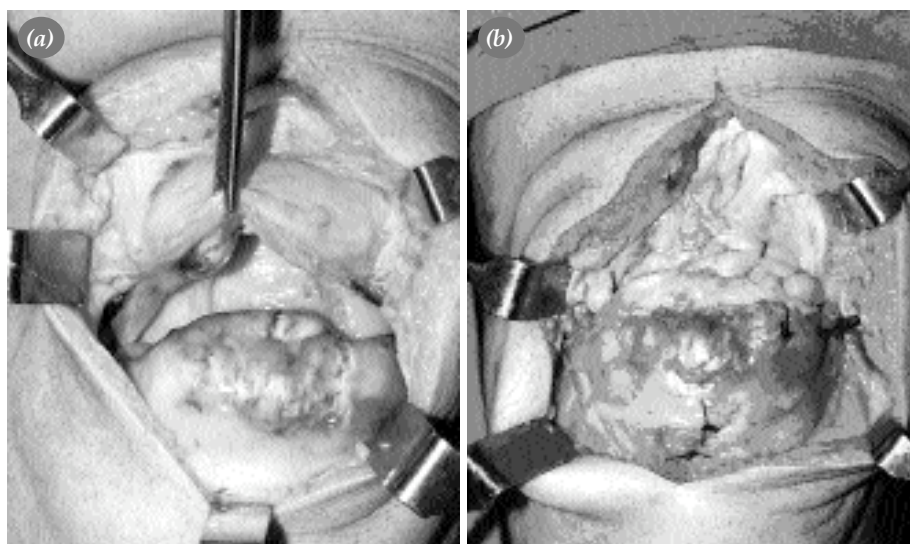
while stretching the tendon. The motion and rotation of patella were evaluated by positioning the knee at flexion (figure 3b). Lateral and medial retinaculums were repaired by no.5 nonabsorbable strings. After closing subcutaneous tissues and skin, casting was performed for 6 weeks while knee was at full extension.

Flat lifting exercise of the leg was started at the first week. Standing on the operated knee was allowed with crutch. After the removal of the casting at 6th week, a rehabilitation program including active, active-assisting and mild stretching exercises was performed for increasing the range of motion. During this time period, electrical stimulation was administered to the quadriceps for preventing atrophy. Exercises were prepared for decreasing the formation of adhesion, re-gaining the mobility of patella and the mobilization of the soft tissues around patella. After obtaining the normal range of motion, exercises for strengthening the quadriceps and hamstrings were started.

To evaluate the clinical and functional status of quadriceps muscle; muscle strength, range of motion of knee, presence of atrophy and the presence of patellofemoral joint signs were recorded at the follow up visits. Follow up interval was 2 years of average (distribution 1-5 years).

## Results

Ruptures occurred at the site of the junction of bone and tendon. All patients completely recovered 6 months after the operation. Mean range of motion was 0-119°. Significant muscle atrophy was not observed in any of the patients when compared with the healthy side. Muscle strength was almost equal in both sides. No pain existed in patellofemoral joint. No re-rupture occurred in any of the patients.



**Figure 3** (a) Intraoperative sight of the tendon of quadriceps ruptured at the upper pole of patella (b) Repairing of the tendon by the tunnels through patella.

## Discussion

Rupture of the tendon of quadriceps occurs by direct or indirect mechanism. Forces arising from the muscle group of quadriceps during active knee extension are transmitted to the tubercle of tibia via the tendon and retinaculum of patella. Patella is the supporting point at the anterior. Huberti et al.<sup>[16]</sup> has searched the degrees of flexion and the interaction of the forces between quadriceps and the tendons of patella. The force acting on the tendon of the quadriceps is 30% less than the force acting on the tendon of the patella at 30° of flexion. The same forces are similar at 50° of flexion. At these angles of flexion, patellofemoral contact occurs at the distal end of patella. This condition gives a mechanical advantage at active knee extension. At 90° of flexion, the force acting on the tendon of quadriceps is 30% higher than the force acting on the tendon of patella and the patellofemoral contact area shifts through the proximal end. Most of the ruptures of QT originated from the trauma occur at the moment of exposure to the highest tension strengths of the tendon while the knee is at semi-flexion or at the moment of eccentric contraction to balancing the body while falling down.<sup>[16]</sup> Also, direct trauma or a puncturing injury may cause the rupture of the tendon of the quadriceps, rarely. In the trial, the ruptures of QT in two patients occurred by falling down on knees and one by traffic accident. There was not a definitive trauma story in the other two patients.

Delay in diagnosis or misdiagnosis is often possible in the cases of rupture of QT. Delay affects the treatment success inversely.<sup>[4]</sup> Results of early repairing is better in most of the patients. At the early stages of soft tissue injuries, the structures of muscle and tendons are still elastic and they are not contracted yet. So, repairing is easy. On the contrary, in delayed cases, contraction occurs in muscle and tendons and their structure are retracted.<sup>[3]</sup> Surgical intervention was performed at the 20th day in one of the patients who admitted to 6 different health care units. Mean time to surgery was 8 days for the total of the patients. No difficulty was experienced during the repairing of the tendon.

No aspiration or local anesthetic administration into the knee joint was necessary for any of the patients, because fissure at the superior of the patel-

la was observed (figure 1). Significant loss of strength was observed during active knee extension. Antero-posterior radiography and tangential radiography of patella was taken from the both knees. MRI was taken. Inferior displacement of patella was observed in direct graphics but no interruption was seen in the shadow of the QT.

In all cases the rupture sites were at the junction of bone and the tendon. Rasul and Fischer<sup>[3]</sup> pointed out that rupture site is related with the age of the patient. 9 of 12 patients (75%) over 40 years of age, the ruptures were at the junction of tendon and bone, 5 of 7 patients (71%) younger than 40, the ruptures were at the middle of the tendon. In the same trial no influence on treatment was reported by age, gender, mechanism of trauma, effected side and repairing method.

On the other hand, age is reported being a predisposing factor and also effects the results negatively.<sup>[3]</sup> In our trial the mean age was 56 and also one of the patients was over 70. The repairing result was successful in this patient in whose both of the tendons were ruptured.

Sometimes the rupture of the tendon of quadriceps is seen with concomitant medical conditions. Spontaneous ruptures might be seen in the both tendons of the patients with gout, diabetes or steroid treatment. Renal diseases and uremia weaken the quadriceps by causing atrophy in the muscle fibers. In the patients with chronic renal insufficiency, structural changes occur in collagens. Two of our patients were suffering from chronic renal insufficiency and ruptures occurred spontaneously. Diabetes causes vascular changes of the tendon<sup>[1]</sup>, rheumatoid arthritis causes chronic inflammatory changes resulting in synovitis and diffuse fibrosis<sup>[6]</sup>, obesity causes fatty degeneration in tendons<sup>[7]</sup>, gout causes synovitis with tophus and fibrinoid necrosis in the tendons.<sup>[8]</sup> Hyperparathyroidism, erythematous systemic lupus, osteomalacia and steroid treatment cause vascular damage at microscopic level by spoiling normal structure of the tendon and this leads tendency to rupturing. Spontaneous rupture due to infiltration of the tendon was reported in a case with non-Hodgkin lymphoma (chronic lymphocytic leukemia with B cell).<sup>[9]</sup> That is why concomitant disease should be investigated in the cases with bilateral spontaneous ruptures of the tendon of

quadriceps. In our trial, laboratory tests were performed besides detailed systemic examination of every patient.

O'Shea et al<sup>[4]</sup> found out the male/female ratio as 8/1 in a trial with 27 patients. Possible cause of the higher incidence of rupture in men may be their more active life style.<sup>[3]</sup> Two fold more ruptures were reported in the non-dominant extremity in the same study. In our study the male/female ratio was 4/1. No difference was observed between the dominant and non-dominant sides.

Partial ruptures generally are treated by conservative methods. Raatikainen et al<sup>[17]</sup> treated partial ruptures of 28 patients surgically and got good or excellent results in 25 of them. In complete ruptures, surgical treatment is a must, because weakness and thinning may be seen by conservative treatment in long term.<sup>[18]</sup> In a few days after the rupturing, quadriceps begins to contract. For this reason the success rate of delayed surgery is lower. The results of many surgical methods are satisfactory. In ruptures in the middle of the tendon, proximal and distal ends are brought close to each other and primary end to end repairing is performed. The ruptures at the site of the junction of bone and tendon may be treated by the tunnels drilled through patella. Maniscalco et al<sup>[15]</sup> used anchors of sutures in spite of tunnels. In our cases the tendon of the quadriceps attached by the tunnels and retinaculum were repaired. Patellar compliance and the strictness of the fixation were tested while the knee is at 0° or 90° of flexion. If the repairing was seemed to be weak, strengthening might have been performed by wires, Leeds-Keio ligaments<sup>[19]</sup>, vessel graft of Dacron<sup>[20]</sup> or Mersilene strings.<sup>[21]</sup>

Bilateral ruptures are treated like monolateral ruptures. In these cases concomitant disease frequently exists and first evaluation is done by a non-orthopedist physician. So, diagnose may be missed or mixed with neurological stroke or arthritis, and treatment may fail due to these false diagnosis.<sup>[22]</sup> Yilmaz et al<sup>[23]</sup> used Scuderi technique for the treatment of bilateral rupture of QT in one case and immediately started the exercises. At the end of 5 years of follow up a complete range of motion and strength of quadriceps were obtained.

Circular casting was performed to all of the

patients while knee was at extension. Straight leg lifting and exercises for quadriceps were started 1 week later. Castings were removed 6 weeks later and exercises for the range of motion and strengthening were started. Some surgeons advocated for early start of the exercises.<sup>[15]</sup> Thus, in a trial with 53 patients with ruptures of QT, no difference was found between the early or late start of exercise.<sup>[24]</sup>

Lack of motion is the most frequently seen complication after the repairing of the tendon of quadriceps. In our study, the range of motion was 0-119° in the postoperative follow-ups. No significant muscle atrophy, re-rupturing or sensitivity of patellofemoral joint was observed in any of the patients.

In conclusion, ruptures of QT are the injuries need early diagnose and surgical treatment. They are seen generally after 40 year-of-age and concomitant disease may exist leading to rupture. Most of the traumatic ruptures occur by indirect forcing. Surgical treatment is needed for a good functional result.

## References

1. Stern RE, Harwin SF. Spontaneous and simultaneous rupture of both quadriceps tendons. *Clin Orthop Relat Res* 1980;(147): 188-9.
2. Larsen E, Lund PM. Ruptures of the extensor mechanism of the knee joint. Clinical results and patellofemoral articulation. *Clin Orthop Relat Res* 1986;(213):150-3.
3. Rasul AT Jr, Fischer DA. Primary repair of quadriceps tendon ruptures. Results of treatment. *Clin Orthop Relat Res* 1993;(289):205-7.
4. O'Shea K, Kenny P, Donovan J, Condon F, McElwain JP. Outcomes following quadriceps tendon ruptures. *Injury* 2002; 33:257-60.
5. Bhole R, Flynn JC, Marbury TC. Quadriceps tendon ruptures in uremia. *Clin Orthop Relat Res* 1985;(195):200-6.
6. Razzano CD, Wilde AH, Phalen GS. Bilateral rupture of the infrapatellar tendon in rheumatoid arthritis. *Clin Orthop Relat Res* 1973;91:158-61.
7. MacEachern AG, Plewes JL. Bilateral simultaneous spontaneous rupture of the quadriceps tendons. Five case reports and a review of the literature. *J Bone Joint Surg [Br]* 1984; 66:81-3.
8. Levy M, Seelenfreund M, Maor P, Fried A, Lurie M. Bilateral spontaneous and simultaneous rupture of the quadriceps tendons in gout. *J Bone Joint Surg [Br]* 1971;53:510-3.
9. Benecke P, Krug F, Wohlschlager C, Psathakis D. A rare cause of rupture of the quadriceps tendon. *Lancet* 2000; 356:1236.
10. Aprin H, Broukhim B. Early diagnosis of acute rupture of the quadriceps tendon by arthrography. *Clin Orthop Relat Res* 1985;(195):185-90.
11. Ehman RL, Berquist TH. Magnetic resonance imaging of musculoskeletal trauma. *Radiol Clin North Am* 1986;24:

- 291-319.
12. Kuivila TE, Brems JJ. Diagnosis of acute rupture of the quadriceps tendon by magnetic resonance imaging. A case report. *Clin Orthop Relat Res* 1991;(262):236-41.
  13. Ramsey RH, Muller GE. Quadriceps tendon rupture: a diagnostic trap. *Clin Orthop Relat Res* 1970;70:161-4.
  14. Richards DP, Barber FA. Repair of quadriceps tendon ruptures using suture anchors. *Arthroscopy* 2002;18:556-9.
  15. Maniscalco P, Bertone C, Rivera F, Bocchi L. A new method of repair for quadriceps tendon ruptures. A case report. *Panminerva Med* 2000;42:223-5.
  16. Huberti HH, Hayes WC, Stone JL, Shybut GT. Force ratios in the quadriceps tendon and ligamentum patellae. *J Orthop Res* 1984;2:49-54.
  17. Raatikainen T, Karpakka J, Orava S. Repair of partial quadriceps tendon rupture. Observations in 28 cases. *Acta Orthop Scand* 1994;65:154-6.
  18. Kelly DW, Carter VS, Jobe FW, Kerlan RK. Patellar and quadriceps tendon ruptures-jumper's knee. *Am J Sports Med* 1984;12:375-80.
  19. Fujikawa K, Ohtani T, Matsumoto H, Seedhom BB. Reconstruction of the extensor apparatus of the knee with the Leeds-Keio ligament. *J Bone Joint Surg [Br]* 1994;76:200-3.
  20. Levy M, Goldstein J, Rosner M. A method of repair for quadriceps tendon or patellar ligament (tendon) ruptures without cast immobilization. Preliminary report. *Clin Orthop Relat Res* 1987;(218):297-301.
  21. Miskew DB, Pearson RL, Pankovich AM. Mersilene strip suture in repair of disruptions of the quadriceps and patellar tendons. *J Trauma* 1980;20:867-72.
  22. Keogh P, Shanker SJ, Burke T, O'Connell RJ. Bilateral simultaneous rupture of the quadriceps tendons. A report of four cases and review of the literature. *Clin Orthop Relat Res* 1988;(234):139-41.
  23. Yilmaz C, Binnet MS, Narman S. Tendon lengthening repair and early mobilization in treatment of neglected bilateral simultaneous traumatic rupture of the quadriceps tendon. *Knee Surg Sports Traumatol Arthrosc* 2001;9:163-6.
  24. Rougraff BT, Reeck CC, Essenmacher J. Complete quadriceps tendon ruptures. *Orthopedics* 1996;19:509-14.