



## The use of magnetic resonance imaging in the diagnosis of plantar fibromatosis: a case report

### *Plantar fibromatozis tanısında manyetik rezonans görüntülemenin yeri: Olgu sunumu*

Ahmet Mesrur HALEFOGLU

*Sisli Etfal Training and Research Hospital Radiology Department*

Plantar fibromatozis benign fakat infiltratif özellik taşıyan bir neoplazidir ve en sık plantar aponevrozun orta bölümü içinde yavaş büyüyen nodüler bir kalınlaşma şeklinde ortaya çıkar. Bu yazıda, iki yıldan beri sağ ayak tabanında ağrılı bir nodül bulunan 43 yaşında bir erkek hasta sunuldu. Manyetik rezonans görüntüleme lezyonun yeri ve sinyal özellikleri ayırıcı tanıda plantar fibromatozisi düşünmemize neden oldu. İnsizyonel biyopsiden sonra tanı histolojik olarak doğrulandı. Bu yazıda, manyetik rezonans görüntülemenin klinik olarak plantar fibromatozis tanısının doğrulanmasında invaziv olmayan bir yöntem olarak kullanılabilirliği ve lezyonun sınırlarını ortaya koyarak cerrahi tedavinin planlanmasında önemli rol oynadığı vurgulandı.

**Anahtar sözcükler:** Fibrom/patoloji/radyografi; ayak hastalığı/patoloji/radyografi; manyetik rezonans görüntüleme; yumuşak doku neoplazisi/patoloji.

Plantar fibromatosis is a benign but infiltrative neoplasm, presenting as a slow-growing nodular thickening most often within the central band of the plantar aponeurosis. In this case report, we presented a 43-year-old male patient who had a tender nodule in the sole of the right foot for two years. On magnetic resonance images, the location and signal intensity characteristics of the lesion were suggestive of plantar fibromatosis, which was histologically confirmed following an incisional biopsy. Magnetic resonance imaging is a noninvasive method for confirmation of the clinical diagnosis of plantar fibromatosis and also has an important role in planning surgical treatment by delineating the extent of the lesion.

**Key words:** Fibroma/pathology/radiography; foot diseases/pathology/radiography; magnetic resonance imaging; soft tissue neoplasms/pathology.

Plantar fibromatosis (Ledderhose disease) is a benign but infiltrative neoplasm, and is a slow growing nodular thickening that occurs most often within the central band of the plantar aponeurosis. This infiltrative fibrous tissue may be locally invasive, but does not metastasize.

Fibromatosis is classified as either superficial or deep: Superficial fibromatosis affects the fascia but does not extend into the muscle. But deep fibromatosis affects the aponeurosis and muscles and rarely extends up to the subcutis.

Although the etiology of plantar fibromatosis is unknown, an increased incidence has been reported with hyperlipidemia, diabetes, chronic liver disease, and seizure disorders.<sup>(1)</sup> A family history has been reported in 13 % of patients, suggesting an inherited risk.<sup>(2)</sup> Also trauma may be an inciting cause in genetically predisposed patients.<sup>(1)</sup>

Magnetic resonance imaging (MRI) is an especially useful modality in terms of planning surgical treatment by showing the exact location and extent of the lesion.

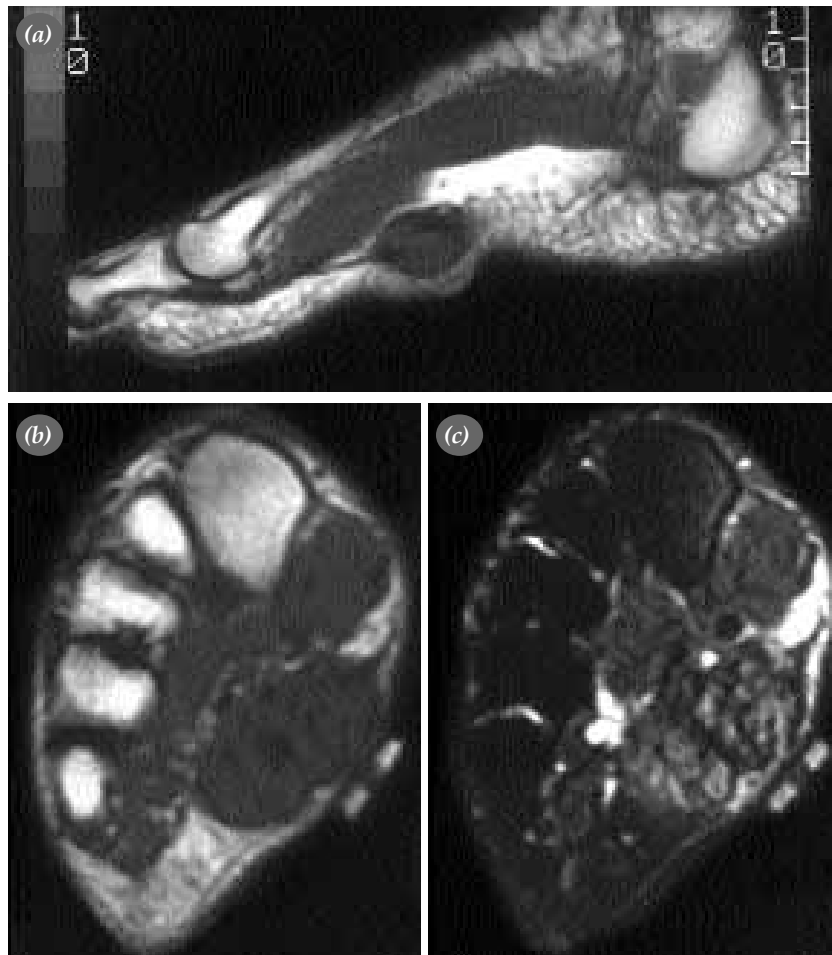
## Case report

A 43 year old male patient applied to the orthopedics clinic complaining of a tender nodule in the sole of his right foot and was referred for an MRI examination. Personal history presented diabetes mellitus and hyperlipidemia, and no significant finding was found in his familial history and physical examination. He only complained of this very slowly enlarging nodule which had existed for 2 years.

In MRI examination, sagittal and axial plane SE (spin - echo)  $T_1$  and FSE (fast spin - echo) fat - suppressed  $T_2$  weighted; following intravenous contrast agent (gadolinium DTPA) post - contrast

SE  $T_1$  weighted images were obtained by a 1.5 tesla superconducting magnet. A soft tissue nodule of 3.3 x 3.2 x 2.2 cm dimensions was detected on the aponeurosis level in close proximity to the plantar surface of the intrinsic muscles on these images. This lesion presented isointense signal intensity with the adjacent muscles on the  $T_1$  weighted images (Figure 1a, b), but showed hyperintensity on the  $T_2$  weighted images. (Figure 1c). There was no contrast enhancement on the SE  $T_1$  weighted images following intravenous contrast administration.

The pathological examination of the material obtained by incisional biopsy from the lesion supported the diagnosis of plantar fibromatosis.



**Figure 1.** **a)** Sagittal SE  $T_1$  weighted image showing nodular mass of 3.3 x 3.2 x 2.2 cm dimensions similar signal intensity with adjacent muscles in the plantar aponeurosis level. **b)** Axial SE  $T_1$  weighted image showing nodular lesion of isointense signal with the muscle. **c)** Axial FSE fat - suppressed  $T_2$  weighted image showing mass of heterogeneous high signal intensity.

## Discussion

In 1897 Ledderhose demonstrated that plantar fibromatosis presents similiar histological features with the Dupuytren contracture fibromatosis appearing in the hand.<sup>(3)</sup> In plantar fibromatosis cases, it has been reported that there is an approximate 28 % occurrence of Dupuytren contracture in the hand.<sup>(4)</sup>

Plantar fibromatosis typically presents as a well-demarcated nodular thickening over the medial band of the plantar fascia. This nodule may be adherent to the overlying skin and single (70 %) or multiple (30 %). Nodules may be bilateral in 13 % of patients.<sup>(2)</sup> In our case, there was a single nodule in the sole of the right foot.

There are two stages of this lesion, namely early and late. The fibroblastic activity which develops in the active stage results in cellular and perivascular proliferation with infiltration thus leading to nodularity, pain and tension in the sole of the foot. In later stage, as the fibrosis progresses, a hard and well-demarcated fibrous nodule develops.<sup>(5,6)</sup>

In plantar fibromatosis, direct roentgenogram reveals a nonspecific soft tissue mass. In ultrasonography, a nonhomogenous soft tissue mass is observed which has isoechogenity with the surrounding muscles. On CT, a nodular lesion of soft tissue density is seen as well.

Logan et al<sup>(7)</sup> reviewed the common radiographic appearances of benign soft tissue tumors of the foot. In this study, plantar fibromatosis appeared as a nodular thickening of the soft tissues superficial to the plantar fascia with low signal intensity on T<sub>1</sub> weighted images, low to intermediate signal intensity on T<sub>2</sub> weighted images, and high signal intensity on fat-suppressed sequences.

The high content of collagen may explain the low signal intensity characteristic of plantar fibromas on T<sub>2</sub> weighted images. In some cases, following intravenous contrast administration, some enhancement may be observed. It has been reported that this enhancement is related to the histological stage and appears in the early stage plantar fibromatosis.<sup>(8)</sup> In our case, the fact that the

complaints had been going on for two years may account for the lack of contrast enhancement due to the lesion being in the late stage.

Morrison et al<sup>(9)</sup> conclude that the consistency of location and the unique signal intensity characteristics allow diagnosis of plantar fibromatosis with reasonable confidence by MRI alone, with the rare exception of clear cell sarcoma of the foot, which may have a similiar radiographic appearance.

In foot plantar fibromatosis, it has been reported that the location and extension of the lesion can be specifically defined through MRI, thus rendering it possible for surgical excision and also diminishing the risk of surgery.<sup>(9,10)</sup> Although the differential diagnosis should cover ganglion, neurofibroma and fibrosarcoma, these pathologies can be easily distinguished because they present high signal intensity especially on T<sub>2</sub> weighted images. However, there are two exceptions where MRI can not be helpful in differentiating plantar fibromatosis due to similiar signal intensity characteristics: one of these pathologies is clear cell sarcoma which frequently occurs in the vicinity of the foot and ankle tendons and aponeuroses, and the other is desmoid tumor (aggressive fibromatosis) which presents as a poorly defined, nonhomogenous soft tissue lesion and is accepted to be a benign fibrous proliferation. Biopsy is recommended for definite diagnosis if clinically aggressive (infiltrative rather than nodular) fibromatosis or clear cell sarcoma are suspected.<sup>(11)</sup>

The most preferred treatment of plantar fibromatosis is local excision. However, since recurrence has been observed some cases in spite of surgical resection<sup>(2)</sup>, recently chemotherapy (methotrexate) and radiotherapy are being considered in addition to surgical resection.<sup>(12)</sup>

In conclusion, we can say that MRI can be used as a noninvasive method for confirmation of the clinical diagnosis of plantar fibromatosis and has an important role in planning surgical treatment by delineating the extent of the lesion.

## References

1. Farmer ER, Hood AF, editors. Pathology of the skin. 2nd ed. New York: McGraw-Hill; 2000.
2. Aluisio FV, Mair SD, Hall RL. Plantar fibromatosis: treat-

- ment of primary and recurrent lesions and factors associated with recurrence. *Foot Ankle Int* 1996;17:672-8.
3. Enzinger FM, Weiss SW, editors. *Fibromatoses*. In: *Soft tissue tumors*. 3rd ed. St. Louis: Mosby Year Book; 1995. p. 201-29.
  4. Sammarco GJ, Mangone PG. Classification and treatment of plantar fibromatosis. *Foot Ankle Int* 2000;21:563-9.
  5. Donato RR, Morrison WA. Dupuytren's disease in the feet causing flexion contractures in the toes. *J Hand Surg [Br]* 1996;21:364-6.
  6. Timins ME. MR imaging of the foot and ankle. *Foot Ankle Clin* 2000;5:83-101.
  7. Logan PM, Janzen DL, O'Connell JX, Munk PL, Connell DG. Magnetic resonance imaging and histopathologic appearances of benign soft-tissue masses of the foot. *Can Assoc Radiol J* 1996;47:36-43.
  8. Narvaez JA, Narvaez J, Ortega R, Aguilera C, Sanchez A, Andia E. Painful heel: MR imaging findings. *Radiographics* 2000;20:333-52.
  9. Morrison WB, Schweitzer ME, Wapner KL, Lackman RD. Plantar fibromatosis: a benign aggressive neoplasm with a characteristic appearance on MR images. *Radiology* 1994;193:841-5.
  10. Pasternack WA, Davison GA. Plantar fibromatosis: staging by magnetic resonance imaging. *J Foot Ankle Surg* 1993;32:390-6.
  11. Watson-Ramirez L, Rasmussen SE, Warschaw KE, Mulloy JP, Elston DM. Plantar fibromatosis: use of magnetic resonance imaging in diagnosis. *Cutis* 2001;68:219-22.
  12. Lee TH, Wapner KL, Hecht PJ. Plantar fibromatosis. *J Bone Joint Surg [Am]* 1993;75:1080-4.