



Surgical treatment of isolated post-traumatic subscapularis tendon ruptures

Travma sonrası oluşan izole subskapularis tendon yırtıklarının cerrahi tedavisi

Mehmet Ugur OZBAYDAR,¹ Egemen ALTAN,¹ Cem Zeki ESENYEL,² Okan YALAMAN¹

¹Okmeydanı Training Hospital, Orthopaedics and Traumatology Clinic;

²Bezm-i Alem Valide Sultan Vakıf Gureba Training and Research Hospital Orthopaedics and Traumatology Clinic

Amaç: Travma sonrası oluşan izole subskapularis tendon yırtığı tanısıyla ameliyat edilen hastaların fonksiyonel sonuçları geriye dönük olarak incelendi.

Çalışma planı: Çalışmaya travma sonrası oluşan izole subskapularis tendon yırtığı tanısıyla ameliyat edilen ve son kontrolleri yapılan altı hasta (5 erkek, 1 kadın; ort. yaş 63.3; dağılım 53-70) alındı. Bulguların ortaya çıkışı ile ameliyat arasında geçen süre ortalama 4.3 aydı (dağılım 1-9 ay). Hastaların yaralanma şekli, yakınmaları, klinik bulguları, artroskopik ve cerrahi bulgular, kullanılan görüntüleme yöntemleri, tamir tekniği ve ameliyat sonrası takipleri değerlendirildi. Değerlendirmede fizik muayene ve radyografi bulguları ve UCLA (University of California at Los Angeles) omuz skoru göz önüne alındı. Ortalama takip süresi 29.6 ay (dağılım 13-53 ay) idi.

Sonuçlar: Ameliyat öncesi ortalaması 11.3 (dağılım 9-14) olan UCLA skoru, son kontrollerde 25.8 (dağılım 12-31) bulundu ($p<0.05$). Dört hastada iyi, bir hastada orta, bir hastada ise kötü sonuç elde edildi. Son kontrollerde altı hastanın beşinde yapılan manyetik rezonans görüntüleme, kötü sonuç alınan hastada tamkat yeniden yırtık geliştiği, orta sonuç alınan hastada kısmi yırtık bulunduğu, diğer hastalarda ise tendon bütünlüğünün korunduğu görüldü.

Çıkarımlar: Subskapularis tendon yırtıklarının tanısı dikkatli bir muayeneyle klinik olarak konabilir. Manyetik rezonans görüntülemeyle ek bilgiler elde edilebilir. Aksiller sinir korunarak ve uygun mobilizasyonla tendonun tamiri çoğu hastada mümkündür.

Anahtar sözcükler: Manyetik rezonans görüntüleme; yırtılma; omuz eklemi/cerrahi; tendon yaralanması/tanı/cerrahi.

Objectives: We retrospectively evaluated the functional results of patients who were treated surgically for post-traumatic isolated subscapularis tendon ruptures.

Methods: The study included six patients (5 males, 1 female; mean age 63.3 years; range 53 to 70 years) who were operated on for isolated post-traumatic subscapularis ruptures. The mean interval between the development of symptoms due to trauma and operation was 4.3 months (range 1 to 9 months). Mechanism of injury, complaints, clinical findings, imaging methods, arthroscopic and surgical findings, repair techniques, and postoperative follow-up data were assessed. Evaluations were based on physical assessment, radiographic examination, and the UCLA (University of California at Los Angeles) score. The mean follow-up was 29.6 months (range 13 to 53 months).

Results: The mean UCLA score was 11.3 (range 9 to 14) preoperatively. It increased to 25.8 (range 12 to 31) postoperatively ($p<0.05$). The results were good in four patients, fair in one patient, and poor in one patient. Magnetic resonance images obtained in five patients at the final follow-up showed total rupture in the patient with poor outcome, partial rupture in the patient with fair outcome, and maintenance of tendon integrity in the remaining patients.

Conclusion: A careful clinical examination may enable the diagnosis of subscapularis tendon ruptures. Magnetic resonance imaging may provide additional information. In most patients, the repair of the tendon is possible by proper protection of the axillary nerve and appropriate mobilization.

Key words: Magnetic resonance imaging; rupture; shoulder joint/surgery; tendon injuries/diagnosis/surgery.

Despite rotator cuff tear is a common clinical entity in elderly people, isolated subscapularis tendon ruptures are relatively rare. This entity can be overlooked when it is not examined carefully and its surgical treatment is difficult. Recently, the number of the articles published on this subject were limited. After Gerber and Krushell identified the clinical characteristics of 16 patients treated surgically due to isolated traumatic subscapularis tendon rupture, they were begun to be diagnosed and treated more commonly.

In this study, functional results of the patients who underwent surgery due to isolated traumatic subscapularis tendon rupture and then followed up, reviewed retrospectively.

Material and method

In this study, 6 patients (5 males, 1 female; mean age 63.3; range 53-70 years) who were operated due to isolated post-traumatic subscapularis tendon rupture and followed up between February 2001 and June 2004 were included. All operations were performed by the same surgeon. Mechanism of injury, complaints, clinical findings, imaging methods, arthroscopic and surgical findings, repair techniques, and postoperative follow-up data were assessed.

In all patients the tendon rupture was on the active shoulder except for one. Complaints were existed following trauma in all patients. Ruptures were occurred due to excessive extension of abducted arm in 4 patients, adducted arm forced to external rotation in 1 patient and falling on shoulder in 1 patient. All patients complained of pain during using their arms over or below their heads. 2 patients couldn't use their arms due to severe pain. In all patients, muscular weakness was present at injured shoulder. The mean period between the manifestation of the symptoms and surgery was 4.3 months (range 1-9 months).

Range of motion of the shoulder was measured with a goniometer while the patient was sitting and the values were compared with the opposite side. Active anterior elevations were limited due to pain in 2 patients; and were measured meanly as 136.6° and 158.3° (range 90°-160°/150°-160°). In any patients, passive anterior elevation wasn't limited. In

5 patients, passive external rotation was increased compared to the opposite side. Passive external rotation was measured meanly as 67.5°/55.8° (range 50°-75°/40°-70°). In all patients, internal rotation was decreased. It was measured in 1 patient at the level of T₁₂, in 1 at the level of L₁, in 2 at the level of L₅, and in 2 patients at the level of PSIS (posterior superior iliac spina). Muscular strengths were examined manually and graded between 0 and 5. While anterior elevation and external rotation strengths were normal in all patients, internal rotation strength was decreased (3/5). Also, the lift off test which was specific to subscapularis ruptures and improved by Gerber and Krushell^[1] was performed in its modified form. In modified lift-off test, the patient's hand was positioned at the highest degree of extension and internal rotation and then the patient was asked to stay in that position. The test was considered positive if the hand fell down on lower back level, due to being unable to continue internal rotating because of subscapularis insufficiency. In all patients, the lift-off test was positive. Furthermore, belly press test was performed. In this test, while elbow was 90 degrees flexed and in coronal plan hand was positioned over the belly and the patient was asked to press his hand on his belly. The test was considered positive if the patient couldn't accomplish this, the shoulder rotates externally or the elbow fell on the flank. In all patients, the belly press test was positive. To assess the long head of biceps muscle, speed test was performed.^[3] Speed test was performed when the shoulder was 90° flexed, elbow was extended, forearm was supinated and forced downwards. The test result was considered as positive if pain was present at biceps tendon or its adhesion site. Speed test was positive in 3 patients. Pre-post operative antero posterior, axillary outlet and supraspinatus outlet radiographies were obtained and to assess the condition of rotator cuff preoperatively, magnetic resonance imaging (MRI) was performed. For subscapularis tendon rupture, tendon signal intensity and morphological appearance were used as criterions. The total absence of the continuity of tendons was interpreted as total rupture whether a retraction was present or not. The presence of biceps tendon and its condition between the tubercles and if present its medial subluxation was noted.

In preoperative radiographies, any osseous pathology wasn't seen. In all patients, there were findings of subscapularis tendon rupture on MR images. In 3 patients, the subscapularis rupture was seen retracted. When sagittally sloped cross-sections were assessed, fatty degeneration which was less than muscle mass was reported in 2 patients. The long head of biceps tendon was seen as subluxated in 1 patient and luxated in 2.

Surgery indications and the technique

The active patients that have been diagnosed as isolated subscapularis rupture following trauma that happened in last one year, that have muscle strength loss that does not respond to conservative treatment, resulting as shoulder pain and functional disorder, and that have not fatty degeneration more than muscle mass in sagittally sloped MR images, underwent surgical repairment.

Operations were performed under general anesthesia in semi-supine position. 4 patients underwent diagnostic arthroscopy before open repairment.

The bone borders of the acromion and coracoid process were traced during diagnostic arthroscopy. A standard posterior approach, 2 cm inferior and 2 cm medial through posterolateral margin of acromion, was used for arthroscopy. Glenohumeral joint was examined by a prob inserted through the port that is in front of the acromioclavicular joint and over the biceps tendon. Then, using the same port, subacromial bursoscopy was carried out.

In all patients, deltopectoral approach was used. Total subscapularis tendon rupture was confirmed (figure 1). Tendons of supraspinatus and infraspinatus were examined inside and outside the joint. The condition of the long head of the biceps tendon inside the bicipital notch was noted. Subscapular tendon was fixed under tendo conjoint and mobilized after fixation suture. For this purpose, subscapular tendon was released from coracohumeral ligaman on the top, from tendon conjoint above, from the glenoid labrum inside the joint and from the axillary nerve in axilla. To this end, axillary nerve was found and preserved. The repairment was made by using No: 2 Etibond sutures (Ethicon) and stitching the tendon on the lesser tubercule with sutures through the bone. The sutures through bone were put using modified Mason-Allen technique to the lateral side of the bicipital notch as cortical bone

remain to act as a bridge. Furthermore, in 4 patients, hook sutures were used. In 3 patients, in whom tendon of biceps was degenerated and luxated inside the joint, tenodesis was done using hook sutures after a bleeding surface was obtained in the intertubercular sulcus.

Perioperative findings

In 4 patients, diagnostic arthroscopy was performed. In all, full-thickness subscapularis tendon rupture and in addition to this in 3 of them, biceps tendon pathology (subluxation in one and luxation in 2) were seen.

During open surgery, in 3 patients, only subscapularis rupture, in 2 subscapularis rupture with luxation of the long head of biceps tendon was determined. In all patients, subscapularis tendon was full-thickness ruptured and in 3, there was retraction on the tendon.

In 2 patients, subscapularis tendon rupture was fixed only by using sutures through bone and in 4 using those and additional hook sutures. For this purpose, in 1 patient two and in 3 patients one hook sutures were used. In 3 patients with biceps instability using an additional hook suture biceps tenodesis was performed after intertubercular sulcus was prepared.

Complications

Perioperatively, any complication wasn't observed. A patient was treated due to a cerebrovascular incident occurred on the second postoperative day.

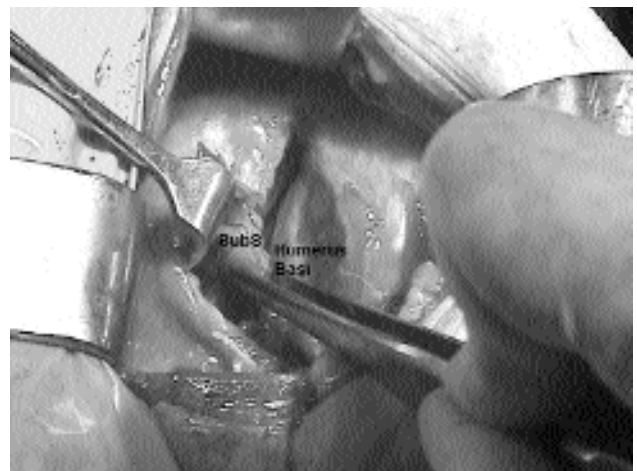

Figure 1. Appearance of subscapularis tendon tear

Postoperative care

The operated shoulders of the patients were fixed with an arm bandage for 6 weeks. Passive range of motion exercises were immediately given. At the end of the 6th week, arm bandage was removed, active assisted movements and isometrical strengthening exercises for the muscles except for subscapularis were given. By the 12th week, internal rotation strengthening exercises were begun. All of the cases were assessed post-operatively by physical examination, findings of the imaging methods and UCLA (University of California at Los Angeles) shoulder rating scale.¹⁴ UCLA scale (with 35 points as top score) included pain (10 points), function (10 points), active anterior elevation (5 points), strength of anterior flexion (5 points) and patient satisfaction (5 points). According to this, 34-35 points were considered as perfect, 28-33 points as good, 21-27 points as

moderate and 0-20 points were considered as bad. The mean follow-up period was 29.6 months (range;013-530months).

Statistical evaluation

Pre-post operative values were evaluated by Wilcoxon Rank-Sum nonparametric test for paired examination.

Results

UCLA score measured as 11.3 meanly (range 9-14) before surgery was measured as 25.8 (12-31) during last controls ($p < 0.05$). Results were scored as good in 4 patients, moderate in 1 patient and bad in 1 patient.

5 of the 6 patients stated that pain that they suffered before surgery was alleviated during their last controls. 1 of the patients stated that he had a pain which required analgetics and is constant but possible to bear.

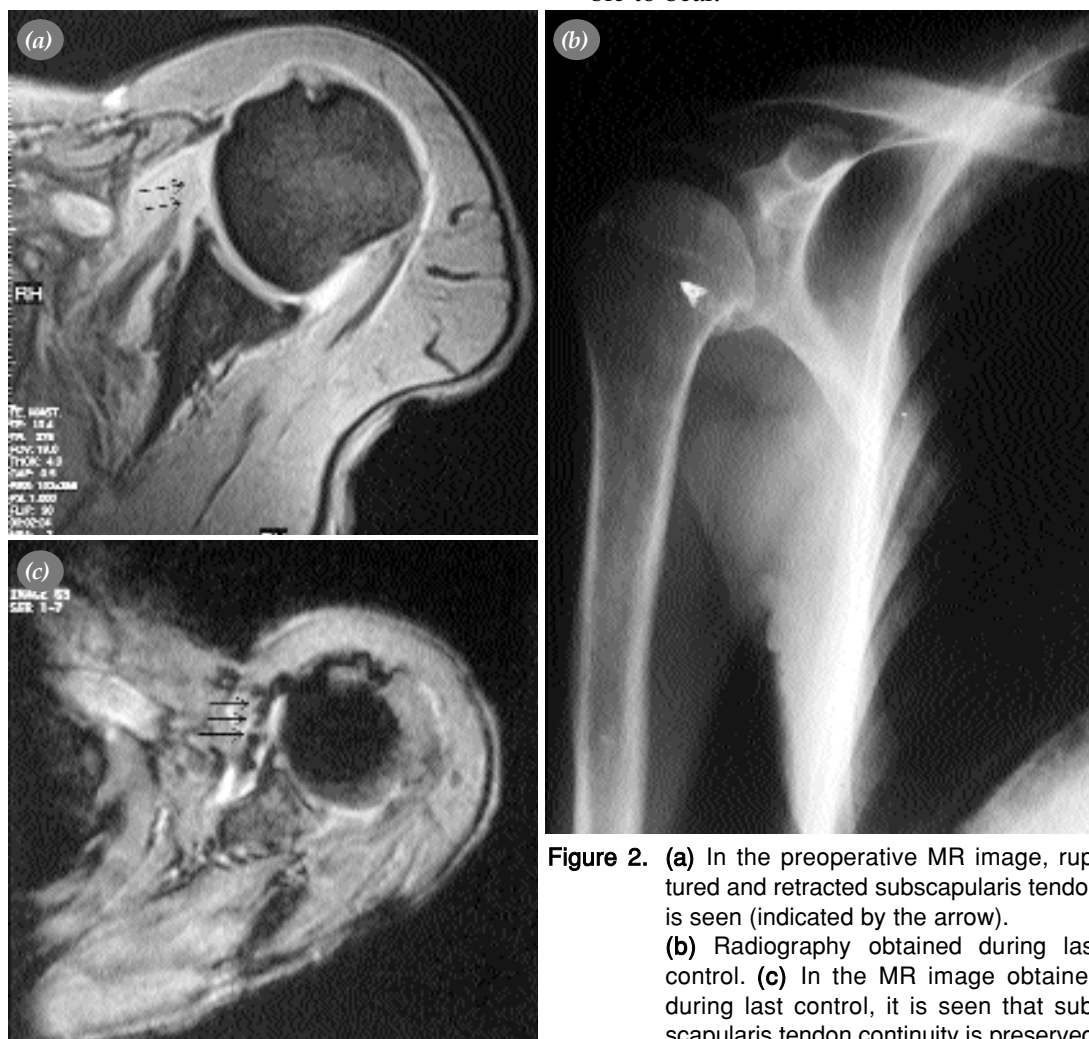

Figure 2. (a) In the preoperative MR image, ruptured and retracted subscapularis tendon is seen (indicated by the arrow). (b) Radiography obtained during last control. (c) In the MR image obtained during last control, it is seen that subscapularis tendon continuity is preserved.

Lift-off test was found positive in 5 patient during physical examination. Test was still positive in one patient at shoulder internal rotation. When compared with the opposite shoulder, anterior elevation motion was decreased 10 degrees in 3 patients. Anterior elevation was measured $153.3^{\circ}/158.3^{\circ}$ in average value (range; 140° - $160^{\circ}/150^{\circ}$ - 160°). When compared with the opposite shoulder, range of external rotation was decreased 10 degrees in 1 patient. External rotation was measured $54.1^{\circ}/55.8^{\circ}$ in average value (range;

40° - $70^{\circ}/40^{\circ}$ - 70°). When compared with the opposite shoulder, only one patient suffered from limited internal rotation. While internal rotation was T_{12} on the opposite shoulder, it was L_5 on the operated shoulder.

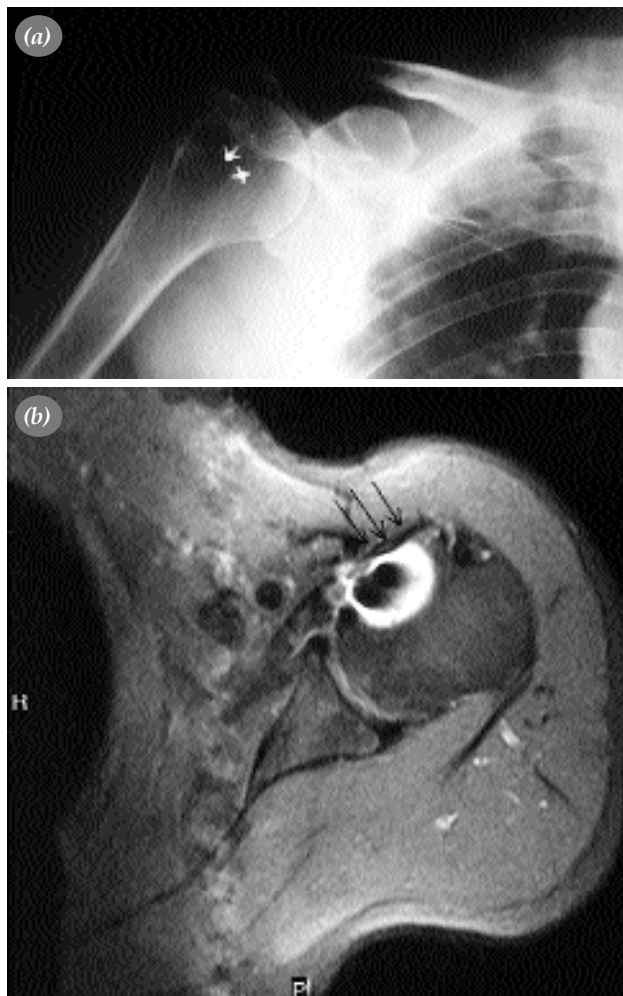


Figure 3. (a) Radiography obtained during last control (b) In the MR image, it is seen that the subscapularis tendon continuity is preserved.

Anterior elevation and external rotation strengths found normal during muscle strength examination. External rotation strength was decreased in 2 patients and was normal in the others. External rotation strength was found 4.5 averagely (range 3-5).

During last controls, on MR images obtained from 5 of the 6 patients, it was seen that again a full-thickness rupture was occurred in the patient with the bad result, that a partial rupture was present in the patient with moderate result and that tendon continuity was preserved in the other remaining patients (Figure 2,3).

Discussion

Despite of not being found so often, subscapularis tendon ruptures are not very rare. According to the almost all studies done it was reported that these ruptures occurred following trauma.^[1,5-7] The most common mechanism is external rotation of the arm in extremely extended or adducted position.^[6] In most of our cases (5 of the 6 cases) injury was due to one of these 2 mechanisms. These kind of ruptures were reported to occur at younger ages unlikely rotator cuff (supraspinatus and infraspinatus) tears.^[8] Gerber and Krushell^[1] reported the mean age of the patients as 51. Warner et al^[6] reported that all of their patients were under 60 years old. Mean age of our patients were 63 years. In all of our patients rupture was due to trauma and there was no history of shoulder problem before trauma in any of them. Subscapularis tendon rupture causes significant functional loss. Because of this reason, relatively old patients who are still active and don't respond conservative treatment underwent surgery. Subscapularis ruptures are often overlooked. All of our patients could be diagnosed by physical examination.

In all of the cases positive lift-off and belly press tests assisted to diagnose. In preoperative MR images, in all patients subscapularis rupture was confirmed and in 3 patients subluxation and luxation was seen in biceps tendon. In addition to this, we were informed about tendon retraction and also about fatty degeneration on sagittal sloped sections. Deutsch et al^[7] performed arthroscopy on 14 shoulders of 13 patients due to traumatic subscapularis tendon rupture before surgical repair. Authors reported that arthroscopy was a useful first stage application for surgical repairment of such cases.

Gerber et al⁽⁵⁾ didn't perform arthroscopy to any of the 16 patient who underwent surgery due to isolated subscapularis tendon rupture. We performed arthroscopy to 4 of our patients before open repairment. But we couldn't obtain extra data in addition to physical examination and imaging methods by this application. Thus we don't perform arthroscopy anymore if we plan open repairment. Before treating subscapularis tendon rupture surgically, to gain appropriate mobilisation especially in the patients with significant retraction, massive dissection and soft tissue release are required. Doing this axillary nerve should be mobilised and preserved. Tear on the rotator cuff is advised to be stitched by sutures passing through cortical bone.⁽⁶⁾ On animal models, Demirhan et al⁽⁹⁾ reported that they gained the strongest fixation by using hook sutures with sutures passing through the bone. We also used sutures passing through bone, in all of our patients, to repair tendon as well as we used hook sutures additional hook sutures in 4 patients. Gerber et al⁽⁵⁾ deepened the bicipital sulcus and reinserted the tendon into that in 4 cases in whom biceps tendon was luxated medially with subscapularis rupture. In addition to this Deutsch et al⁽⁷⁾ performed tenodesis on biceps tendon to the bicipital sulcus by using hook sutures after obtaining a bloody surface. Ticker and Warner⁽⁸⁾ reported that clinical finding of pain in biceps remained in the cases that biceps subluxation was treated by reinserting the tendon into the bicipital sulcus. For this reason tenodesis by hook sutures was performed in 3 cases in our study. Repairment of isolated ruptures of subscapularis tendon was determined less successful when compared with repairments of isolated supraspinatus tendon or supraspinatus tendon ruptur accompanied by infraspinatus tendon rupture. Deutsch et al⁽⁷⁾ obtained full recovery in 10 of the 14 patients in their study with a mean follow-up period of 2 years. Gerber et al⁽⁵⁾ reported good-very good result in 13 of 16 patients that they followed –up for a mean period of 43 months. We obtained good result in 4 patients and bad result in 1 patient. When the 2 patients with unsuccessful results were searched it was deter-

mined that the periods between the trauma and the surgery were the longest (8 and 9 months) of all and fatty degeneration was present in MR images. Also the cerebrovascular incident, occurred post operatively, acted as a factor for having bad result in one of the patients because of not being able to rehabilitate the patient.

As a result, subscapularis tendon ruptures may be diagnosed by a careful physical examination. Additional data may be obtained with MR imaging. Repairment of the tendon in appropriate mobilisation, preserving the axillary nerve, is possible. In our cases, the most essential factors which affected our results were found as the period between the trauma and the surgery and presence of fatty degeneration in MR images. It is difficult to gain successful results even with correct diagnosis and treatment in this group of patients when compared with the repairment of the other parts of the rotator cuff.

References

1. Gerber C, Krushell RJ. Isolated rupture of the tendon of the subscapularis muscle. Clinical features in 16 cases. *J Bone Joint Surg [Br]* 1991;73:389-94.
2. Edwards TB, Walch G, Nove-Josserand L, Gerber C. Anterior superior rotator cuff tears: repairable and irreparable tears. In: Warner JP, Ianotti JP, Flatow EL, editors. *Complex and revision problems in shoulder surgery*. 2nd ed. Philadelphia: Lippincott Williams & Wilkins; 2005. p.107-29.
3. Magee DJ. Shoulder. In: *Orthopaedic physical assessment*. 3rd ed. Philadelphia: W. B. Saunders; 1997. p. 175-240.
4. Ellman H, Hanker G, Bayer M. Repair of the rotator cuff. End-result study of factors influencing reconstruction. *J Bone Joint Surg [Am]* 1986;68:1136-44.
5. Gerber C, Hersche O, Farron A. Isolated rupture of the subscapularis tendon. *J Bone Joint Surg [Am]* 1996;78:1015-23.
6. Warner JP, Answorth A, Gerber C. Diagnosis and management of subscapularis tendon tears. *Tech Orthop* 1994;9:116-25.
7. Deutsch A, Altchek DW, Veltri DM, Potter HG, Warren RF. Traumatic tears of the subscapularis tendon. Clinical diagnosis, magnetic resonance imaging findings, and operative treatment. *Am J Sports Med* 1997;25:13-22.
8. Ticker JB, Warner JJ. Single-tendon tears of the rotator cuff. Evaluation and treatment of subscapularis tears and principles of treatment for supraspinatus tears. *Orthop Clin North Am* 1997;28:99-116.
9. Demirhan M, Atalar AC, Kilicoglu O. Primary fixation strength of rotator cuff repair techniques: a comparative study. *Arthroscopy* 2003;19:572-6.