



Thumb duplication: An analysis of 72 thumbs

Çift başparmak anomalisi: 72 olgunun değerlendirilmesi

Tackin OZALP,¹ Erhan COSKUNOL,² Oguz OZDEMIR²

¹Celal Bayar University, Medical Faculty, Department of Orthopedics and Traumatology;

²Ege University, Medical Faculty, Department of Orthopedics and Traumatology

Amaç: Çift başparmak anomalisi nedeniyle ameliyat edilen olgular değerlendirildi.

Çalışma planı: 1982-2003 yılları arasında 67 hastanın (4 kadın, 26 erkek; ort. yaş 2.5; dağılım 6 ay-20 yıl) 72 parmağı çift başparmak anomalisi nedeniyle ameliyat edildi. Beş olguda iki taraflı tutulum vardı. Anomali 39 olguda sağ, 33 olguda sol elde idi. Olgular klinik ve radyografik olarak Wassel sınıflandırmasına göre değerlendirildi. Ameliyat tekniği olarak, simetrik başparmak olan 13 olguda Bilhaut-Cloquet işlemi uygulandı; diğer olgularda daha küçük ve kullanışsız olan kısım eksize edildi. Hasta memnuniyeti görsel analog skala ile değerlendirildi. Takip süresi ortalama 3.6 yıl (dağılım 1-10 yıl) idi.

Sonuçlar: Bilhaut-Cloquet ameliyatı uygulanan olgularda tırnak deformitesi gelişti; bu parmaklarda gelişme geriliği gözlenmezken, beşinde interfalangeal eklemdede kısıtlılık, yedisinde karşı başparmağa göre irilik izlendi. Sekiz olguda (%11.9) eklem hareket kısıtlılığı görüldü; bunların birinde kısıtlılık metakarpofalangeal eklemdede, diğerlerinde interfalangeal eklemdeydi. On yedi hastada (%25.4) başparmak sırasında 10° üzerinde açı bozukluğu gözlemlendi. Yirmi beş olguda (%37.3) ikincil cerrahi işlem gerekti. On iki olguda (%17.9) kollateral bağ rekonstrüksiyonu, üç olguda (%4.5) tendon hizalaması, beş olguda (%7.5) düzeltici osteotomi, beş olguda interfalangeal ekleme artrodez uygulandı. Hastaların %85'i (n=57) cerrahi ile elde edilen sonuçtan memnundu.

Çıkarımlar: Çift başparmak tedavisinde komplikasyonları ve ikincil cerrahi uygulamaları azaltmak, iyi bir rekonstrüksiyon sağlamak için, cilt, tırnak, kemik ve bağların birlikte değerlendirilmesi ve tamiri gerekir.

Anahtar sözcükler: Çocuk; polidaktili/cerrahi; hareket açıklığı, eklem; rekonstrüktif cerrahi presedür/yöntem; başparmak/anormallik/cerrahi.

Objectives: The aim of this study was to evaluate patients who were operated on for a duplicated thumb.

Methods: Sixty-seven patients (41 females, 26 males; mean age 2.5 years; range 6 months to 20 years) underwent surgery for a total of 72 duplicated thumbs between 1982 and 2003. Five patients had bilateral involvement. The anomaly was on the right in 39 cases, and on the left in 33 cases. Clinical and radiographic evaluations were made according to the Wassel classification. The Bilhaut-Cloquet technique was used in 13 symmetrically duplicated thumbs, while simple excision of the unserviceable part was performed in the remaining. Patient satisfaction was assessed with the use of a visual analog scale after a mean follow-up period of 3.6 years (range 1 to 10 years).

Results: Nail deformity was present in all cases treated by the Bilhaut-Cloquet technique. These thumbs did not exhibit growth retardation, but interphalangeal joint motion was limited in five, while seven had a larger size compared to the normal side. Limited range of motion was detected in eight cases (11.9%), affecting the metacarpophalangeal joint in one, and the interphalangeal joint in the others. Seventeen patients (25.4%) developed an angulation of more than 10° in the alignment of the thumb. Secondary procedures were necessary in 25 cases (37.3%), including collateral ligament reconstruction (n=12; 17.9%), tendon rerouting (n=3; 4.5%), corrective osteotomy (n=5; 7.5%), and arthrodesis of the interphalangeal joint (n=5; 7.5%). Patient satisfaction with the surgical outcome was 85% (n=57).

Conclusion: It is important to evaluate and treat the skin, nail, bone, and the ligaments in a simultaneous manner in order to obtain a good reconstruction and to decrease both the complications and the need for subsequent operations.

Key words: Child; polydactyly/surgery; range of motion, articular; reconstructive surgical procedures/methods; thumb/abnormalities/surgery.

Bifid thumb is the most common congenital anomaly between the upper extremity anomalies¹. It's analysed in a large spectrum from the simple division of distal phalanx while the proximal part is unique (bifid) to the double formation of metacarpals (duplication). Double thumb anomaly is also called as bifid thumb, duplication, radial polydactily, preaxial polydactily. Thumb polydactily is classified according to the radiologic and clinical properties. Wassel classification is the one of the most commonly used in which the cases are evaluated considering the longitudinal axe². Type 4 cases are most frequently seen.

In this study the assessment of the secondary surgical procedure frequency, the concomitant organ anomaly and the patient's satisfaction are aimed in the surgically treated bifid thumb cases.

Material and method

Seventy two thumb of the 67 patients (41 female and 26 male; mean age 2,5; 6 months – 20 years) with bifid thumb anomalies between 1982 – 2003. Five cases were bilaterally involved. Anomaly was at the right hand in thirty-nine cases and at the left hand in thirty-three cases. The cases were evaluated clinically and radiologically according to the Wassel classification. Patients' complaints, family histories were examined. Thumb longitudinal axe angles were measured with a goniometer and the restrictions of range of motion and the nail deformities were recorded. The Bilhaut-Cloquet technique was used in 13 symmetrically duplicated thumbs, while simple excision of the unserviceable part was performed in the others. In the simple excision practiced cases, the collateral ligament repairs, reinsertions of the flexor and extensor tendons to the remnant and the correctives osteotomies were added to the surgical procedure when necessary.

Patient satisfaction was assessed with the use of a visual analog scale between 0 and 100. The follow-up period was 3,6 years (1-10 years).

Results

The distribution of the types of the cases according to Wassel classification from 1 to 7 were by order of 3,18,6,20,8,3 and 10. Family history was positif in 11 cases an blood relationship in 17 cases. Cardiovascular system anomalies in three cases,

gastrointestinal anomalies in two cases and musculoskeletal anomalies in two cases were also noted.

Nail deformity was present in thirty cases treated by the Bilhaut-Cloquet technique (Fig. 1). These thumbs did not exhibit growth retardation, but interphalangeal joint motion was limited in five, while seven had a larger size compared to the normal side. Limited range of motion was detected in eight cases (11.9%), affecting the metacarpophalangeal joint in one (type four), and the interphalangeal joint in the others. Five of them were type II, one case type IV and two cases type VII. An anglulation up to 10° was seen on the thumb ray in seventeen cases and in nine of them the angle was up to 20°. But secondary corrective osteotomy necessitated in only five cases.

Secondary procedures were necessary in 25 cases (37.3%), including collateral ligament reconstruction (n=12; 17.9%), tendon rerouting (n=3; 4.5%), corrective osteotomy (n=5; 7.5%), and arthrodesis of the interphalangeal joint (n=5; 7.5%).

Patient satisfaction with the surgical outcome was 85% (n=57). Some of the patients were unsatisfied by the limitation of motion and some of the others by the esthetic appearance. No patient complained about the nail deformity. But three cases were unsatisfied of a larger thumb compared to the normal side. Finally twelve cases complained about the longitudinal axe deformity.

Discussion

Bifid thumb anomaly is the one of the most common congenital upper extremity anomalies. The thumb is growing about the mesenchymal condensation of the radial sided hand pedicle. Duplication

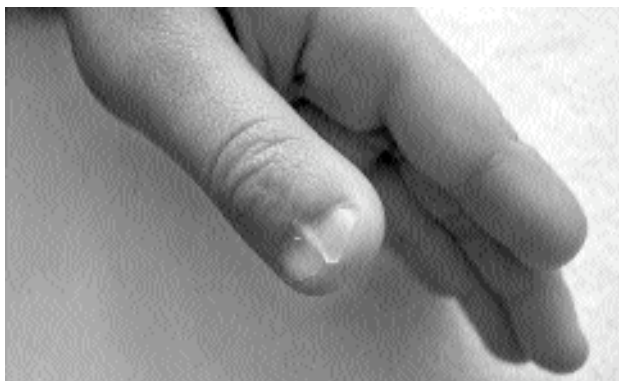

Figure 1. The nail deformity after the Bilhaut-Cloquet procedure

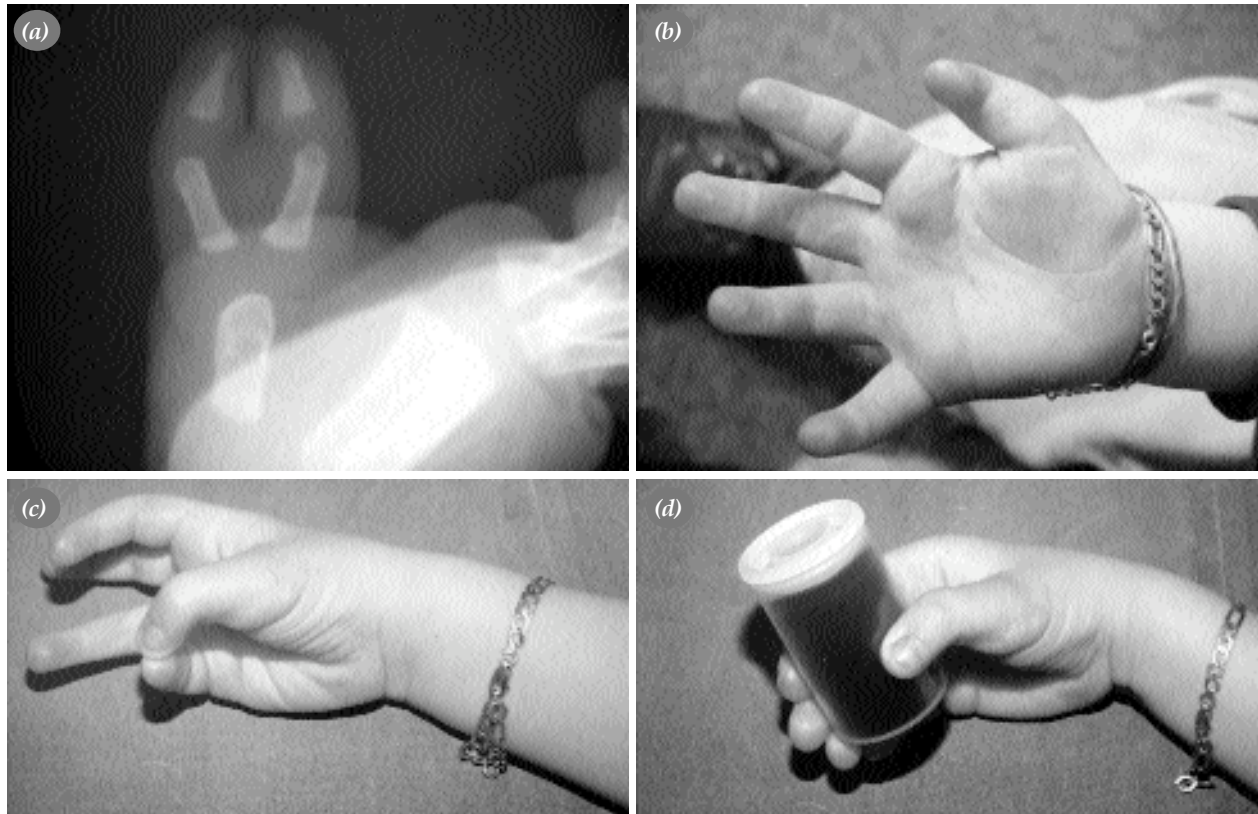


Figure 2. (a-d) In a one-year-old girl with type 4 thumb duplication the radial sided part was excised, the extensor pollicis longus tendon transferred to the remaining thumb and the collateral ligament repair was applied. In the fourth year postoperatively the esthetic appearance was poor despite a very good function.

takes root from the unsuitable division of this condensation. All of the divided thumbs are smaller than normal.

The surgical treatment must be both functional and cosmetic. Because of the possible psychologic and social effects of the anomaly over the child and the parents, it's suggested to complete the treatment before two years of age³. The aim of the treatment is not only to excise the thumb in excess but also to maintain the function or to bring in it a good function. For this reason, reconstruction of the collateral ligaments, centralization of the eccentric flexor and the extensor tendons, transfer of the thenar muscles must be realized in the same session. Wedge osteotomies to correct skeletal morphology, the segmental transposition of the proximal and distal phalanx must also be done in one stage⁴. A minimal axial deviation will be more evident when the child grow up, so the deflection angle must be considered during the operation. Despite a good function, some patients can be unsatisfied because of the esthetic reasons (Fig. 2a-d).

Either excision of the hypoplastic thumb and reconstruction with the preplanned skin flap is realised or the Bilhaut-Cloquet operation is applied in the treatment. The Bilhaut-Cloquet technique is advised in the duplication treatment especially in Wassel type 1 and 2 but also is applied in type 3 and 4^{5,6}. This technique is based to the excision of the excess parts of the skin, the nail, the nail bed and the bone from the middle part of the duplicated thumb. Thus, it's possible to obtain a thumb appearance close to the other side. The epiphyseal parts must not be included in the extracted segments because of the possible risk of growth arrest. The remaining parts of the thumb are tied to each other with sutures or transvers Kirshner wires. The difficulties of this technique are to obtain the conformity of the articular lines and to prevent the nail bed deformities. The articular incongruity can lead an intraarticular synovitis and degeneration⁷. Five cases are exposed to arthrodesis for the pain and arthrosis caused by the joint line incongruity. After the nail matrix excision, a longitudinal mark is frequently seen at the midline.

Despite the good results in some cases of Bilhaut-Cloquet procedure, the complication rate is high. Especially the joint motion restrictions and the nail deformities can cause an unsatisfaction of the patients in the late period. For this reason, even if the duplicated parts are symmetricals, the bone and soft tissue excision from the radial side and the collateral ligament repair are recently applied in this serie. An acceptable thumb is gained with saving the nail piece in the remaining part and a soft tissue transfer from the radial side of the excised fragment. In this way the nail deformities are precluded (Cheng modifications)⁸. Classic Bilhaut-Cloquet technique is only applied for the cases in which two nails are adherents. In such a case, to assure the juxtaposition of the nails under magnification and to stitch carefully with delicate sutures (7/0 monoprotylen – chromic catgut) can prevent the deformities. Kato et al. repaired the nail bed with 8-9/0 nylon under microscope magnification and noted good results⁹.

In the other duplication cases, the excision of the little and cumbersome component is routinely practised. If the duplicated parts are equals, to preserve the ulnar sided part is suggested for the pinch¹⁰. In this study type 2 and 4 cases composed the majority. In the type 4 cases the metacarpophalangeal joints are followed, the excess parts on the metacarpal heads are excised and the collateral ligaments are fixed to the remaining phalanx. Thus the possible deformities were prevented. However in some cases the neglected repair of the collateral ligaments required secondary procedures.

Secondary procedures are applied in 37,3 % of the cases. The high level of this rate signpost that

the treatment of this frequently seen congenital anomaly is not consisting of the excision of the cumbersome part but also the complicated procedures are required. The experience of the surgeon in the congenital anomalies is incontestable. The skin, the bone and the ligaments must be evaluated and repaired concurrently for to reduce the complication rate and secondary procedure necessity and to provide a good reconstruction.

References

1. Buck-Gramcko D. Congenital malformations of the hand and forearm. *Chir Main* 2002;21:70-101.
2. Wassel HD. The results of surgery for polydactyly of the thumb. *Clin Orthop Relat Res* 1969;(64):175-93.
3. Kozin SH. Deformities of the thumb. In: Green DP, Hotchkiss RN, Pederson WC, Wolfe SW, editors. *Green's operative hand surgery*. 5th ed. Philadelphia: Churchill Livingstone; 2005. p. 1445-68.
4. Cetik O, Uslu M, Cirpar M, Eksioğlu F. Experience with the surgical treatment of radial polydactyly in adults. *Ann Plast Surg* 2005;55:363-6.
5. Samson P, Salazard B, Magalon G. The "Bilhaut-Cloquet" technique for treatment of thumb duplication. *Handchir Mikrochir Plast Chir* 2004;36:141-5.
6. Kemnitz S, De SL. Pre-axial polydactyly: outcome of the surgical treatment. *J Pediatr Orthop B* 2002;11:79-84.
7. Ogino T, Ishii S, Takahata S, Kato H. Long-term results of surgical treatment of thumb polydactyly. *J Hand Surg [Am]* 1996;21:478-86.
8. Leclercq C, Gilbert A. Duplication du pouce. In: Gilbert A, Buck-Gramcko D, Lister G, editors. *Les malformations congénitales du membre supérieur*. Paris: Expansion Scientifique Française; 1991. p. 147-54.
9. Cheng JC, Chan KM, Ma GF, Leung PC. Polydactyly of the thumb: a surgical plan based on ninety-five cases. *J Hand Surg [Am]* 1984;9:155-64.
10. Kato S, Ogino T, Minami A. Etude à long terme de l'intervention de Bilhaut-Cloquet pour la polydactylie du pouce. In: Gilbert A, Buck-Gramcko D, Lister G, editors. *Les malformations congénitales du membre supérieur*. Paris: Expansion Scientifique Française; 1991. p 139-46.