



All-inside meniscal repair using the RapidLoc device

RapidLoc fiksatorü ile menisküs tamiri

Cengiz SEN,¹ Mehmet ASIK, Feridun YUMRUKCAL, Ata Can ATALAR, Mehmet ERDIL, Omer F. TASER

¹Department of Orthopaedics and Traumatology, Medical School of Gaziosmanpasa University;
Department of Orthopaedics and Traumatology, Medical School of Istanbul, University of Istanbul

Amaç: Menisküs tamirlerinde konvansiyonel dikiş yöntemleri ile oldukça tatminkar sonuçlar elde edilmesine karşın, bu yöntemlerde ameliyat süresi uzun ve komplikasyon oranı yüksektir. Bu çalışmada, RapidLoc fiksatorü kullanılarak yapılan menisküs tamirlerinin klinik sonuçları değerlendirildi.

Çalışma planı: Çalışmaya RapidLoc fiksatorü ile menisküs tamiri yapılan ardışık 57 hasta (hepsi erkek; ort. yaş 24; dağılım 17-33) alındı. Travma ile ameliyat arasında geçen süre ortalama 20 gün (dağılım 7-60 gün) idi. Ortalama yırtık uzunluğu 25 mm (dağılım 10-35 mm) idi. Her bir yırtık için ortalama iki adet (dağılım 1-3) RapidLoc fiksatorü kullanıldı. Ön çapraz bağ (ÖÇB) yırtığı olan 30 hastanın 17'sine, menisküs tamiri ile beraber hamstring otoplasti ile ÖÇB rekonstrüksiyonu yapıldı; 13 hastaya ise rekonstrüksiyon istemedikleri için sadece menisküs tamiri yapıldı. Hastalar Tegner aktivite skoru, Lysholm skoru ve IKDC (International Knee Documentation Committee) subjektif diz değerlendirme formuna göre değerlendirildi. Klinik değerlendirmede Barrett ölçütleri kullanıldı. Ortalama takip süresi 39 ay (dağılım 18-66 ay) idi.

Sonuçlar: Menisküs tamiri sırasında tanınal ve cerrahi artroskopiyi içeren toplam ameliyat süresi ortalama 25 dakika (dağılım 15-35 dk) idi. Ameliyat öncesine göre tüm fonksiyonel sonuçlarda anlamlı düzelme görüldü ($p<0.001$). Lysholm skoru 58.8 ± 13.7 'den 93.3 ± 7.7 'ye, Tegner aktivite skoru 3.5 ± 1.0 'dan 6.0 ± 1.6 'ya, IKDC skoru 52.8 ± 10.5 'ten 91.4 ± 4.0 'a yükseldi. Barrett ölçütlerine göre, tamir edilen tüm menisküslerin iyileştiği saptandı. Bir hastada ağrı ve şişlik nedeniyle ikincil artroskopi gerekti; bu hastada kullanılan iki RapidLoc'dan birinin başlığının erimedığı görüldü.

Çıkarımlar: Kısa dönemdeki tatmin edici sonuçları, kolay uygulanabilmesi, kısa ameliyat süresi ve düşük komplikasyon oranı nedeniyle, RapidLoc fiksatorünün uygun olgularda iyi bir seçim olduğu sonucuna varıldı.

Anahtar sözcükler: Ön çapraz bağ/yaralanma/cerrahi; artroskopi; menisküs, tibial/yaralanma/cerrahi; yırtık.

Objectives: Although conventional suture techniques yield satisfactory results in the treatment of meniscal ruptures, they are inherent with long operative time and high complication rates. The purpose of this study was to evaluate the results of meniscal repair with the use of the RapidLoc device.

Methods: The study included 57 consecutive patients (all males; mean age 24 years; range 17 to 33 years) who underwent meniscal repair with the RapidLoc device. The mean time from injury to surgery was 20 days (range 7 to 60 days). The mean length of meniscal ruptures was 25 mm (range 10 to 35 mm). A mean of two RapidLoc fixators were used for each rupture. Thirty patients had associated anterior cruciate ligament (ACL) rupture; of whom 17 patients underwent ACL reconstruction with hamstring autografts. Thirteen patients refused ACL reconstruction and underwent only meniscal repair. Functional results were evaluated using the Tegner activity score, Lysholm score, and IKDC (International Knee Documentation Committee) subjective knee evaluation form. Clinical assessments were made using the Barrett criteria. The mean follow-up was 39 months (range 18 to 66 months).

Results: The mean operation time including diagnostic and surgical arthroscopy was 25 minutes (range 15 to 35 min). Compared to the preoperative scores, all functional scores showed significant improvements ($p<0.001$) with the following increases: Lysholm score from 58.8 ± 13.7 to 93.3 ± 7.7 , Tegner activity score from 3.5 ± 1.0 to 6.0 ± 1.6 , and IKDC score from 52.8 ± 10.5 to 91.4 ± 4.0 . According to the Barrett criteria, meniscal healing was achieved in all the patients. Second-look arthroscopy was performed in one patient due to pain and swelling, which showed an unabsorbed tophat of the RapidLoc device.

Conclusion: Our findings suggest that the RapidLoc meniscal repair device may be an appropriate choice in selected cases because of satisfactory short-term clinical results, ease of applicability, short operation time, and low complication rate.

Key words: Anterior cruciate ligament/injuries/surgery; arthroscopy; menisci, tibial/injuries/surgery; rupture.

As the role of menisci in load transmission, shock absorption, lubrication, joint stability, and articular cartilage nutrition is well-understood, more interest is focused on meniscal repair^[1] and techniques have evolved since the early reports of open meniscal repair by DeHaven.² After the first arthroscopic meniscal repair was performed by Ikeuchi in 1969,^[3] different techniques were described and the last generation arthroscopic meniscal repair technique, the all-inside technique, was first performed by Morgan in 1988.^[4] In time different all-inside meniscal repair devices have been developed to lessen the operative time and to avoid injury to the neurovascular structures and these devices are divided into generations. Although the results achieved by the rigid all-inside devices were quite successful,^[5-7] long-term results were not so satisfying.^[8,9]

The last evolved all-inside meniscal repair devices are combined systems of sutures and biodegradable materials. The RapidLoc (Mitek, Products, Westwood, MA) is one of them and it is a combination of either 2-0 Ethibond or 2-0 Panacryl suture with a poly-L-lactic acid (PLLA) 'backstop' and either a PLLA or polydioxanone (PDS) 'tophat'.

We designed this retrospective study to evaluate the clinical results and complications of meniscal repair using the RapidLoc.

Patients and method

Our study group consisted of 63 patients (mean age 24.2 years, range 17-33; all men) with meniscal lesions who had undergone meniscal repair using the RapidLoc device between September 2002 and December 2006. Six of them, were excluded from the study because they did not visit clinic for last control. 30 of the patients had also Anterior Cruciate Ligament (ACL) ruptures and 17 of these underwent concomitant ACL Reconstruction and 13 patients refused ACL reconstruction and underwent only meniscal repair. All ACLR was performed using hamstring (HS) autograft. Meniscal repairs were performed on 39 right and 18 left knees. There were 57 meniscal tears repaired; 21 on medial, 24 on lateral and 6 on both menisci. The average interval between trauma and surgery was 20 (range 7-60) days.

The mean length of tears was 25 (range, 10-35) mm and all were unstable. There were 43 red-red zone and 14 red-white zone tears and localized between posterior horn and corpus. One of them was on

discoid meniscus. An average of two (1-3) RapidLoc devices were used on a single tear. 64 of the delivery needles used were 0 degree, 34 were 12 degree and 46 were 27 degree with a total number of 144. All the meniscal tears were decided to be amenable to repair according to length, stability and zone of tear.

Operative indications were vertical tears longer than 1 cm, patient age under 40 years, and lesions localized on posterior horn and corpus. Preoperative diagnosis of meniscal tears was established using physical examination; subjective signs included local pain, swelling, difficulty in climbing stairs, patellar cracking sounds, delay in returning to work or daily exercise and local pain, walking, running, jumping with one leg and squatting, local symptoms of knee joint, locking, muscular strength, diameter of calf, and range of movements were accepted as objective findings. Besides, we took radiographic view and MRI in all patients.

Postoperatively, patients were evaluated using Lysholm knee score,^[10] Tegner activity score,^[11] and International Knee Documentation Committee (IKDC) score.^[12] In addition, we used Barrett's criteria to evaluate healing of repaired meniscus.^[13] A repaired meniscus was accepted healed if there was no joint line tenderness, effusion, and a negative McMurray's test at the latest follow-up. If one or more of these parameters were present, the result was considered as a failure.

The technique

The meniscal repairs of all the patients were carried out using RapidLoc device (Mitek, Westwood, MA) (Figure 1). To optimize healing an arthroscopic rasp was used on both the superior and inferior parameniscal capsule. The implant is preloaded onto a needle. There are three available needle angles (0°, 12°, and 27°). The delivery needle was passed through the meniscal tear to the pericapsular soft tissue by the help of the applier (a gun shaped device) and the trigger on the applier was pulled to open the backstop. The suture was then pulled to ensure the fixation of



Figure 1. RapidLoc device

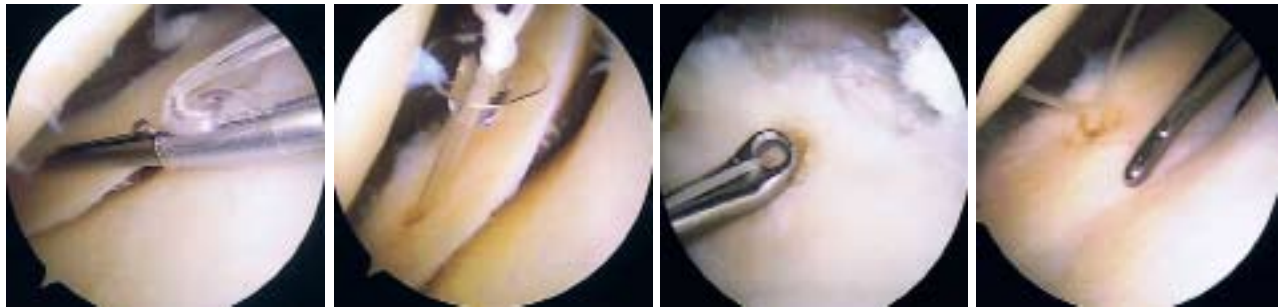


Figure 2. The technique for RapidLoc insertion

the backstop and the tophat was then advanced over the suture by the help of the knot pusher and after the reduction of the meniscus was ensured, enough compression was placed on the meniscus using the knots placed on the tophat (Figure 2a, b, c, and d).

In the postoperative period a cryocuff was applied immediately and partial weight bearing using crutches was permitted. For the first 2 weeks isometric quadriceps and hamstring exercises were initiated using a brace that held the knee at full extension. After 2 weeks movements between 0° and 90° were allowed. After 6 weeks the patient was switched to full range of motion, and after 8 weeks full weight bearing without any support was permitted. If patient’s muscular strength recovered completely, they were allowed to return to their sports activities at the end of the 4th month. In cases in which ACL reconstructions combined with meniscal repairs were performed, accelerated ACL rehabilitation protocols consisting of partial weight bearing and restricted flexion exercises of 6-8 weeks duration were used. The mean follow-up was 39 (range, 18-66) months.

Evaluation of statistical data

SPSS 8.0 (SPSS Inc. Chicago, IL, USA), two paired sample test, t-test and Chi-square test were used for statistical analysis. Non-parametric Wilcoxon Signed Ranks test was used when a significant difference was found. Differences between groups ANOVA and Bonferroni multiple comparison test were evaluated. P<0.05 with 95% confidence interval was accepted as significant for all tests.

Results

The mean operative time including diagnosis and surgery was 25 (range, 15-35) minutes. All functional results significantly demonstrated an improvement (Table 1). In addition, we evaluated our results in three groups: group A (repaired meniscus+ACL reconstruction), group B (only repaired meniscus), and group C (only repaired meniscus, reluctant for ACL reconstruction even though ACL rupture exists). Regarding the statistical comparison among the three groups, we found less satisfactory results if the ruptured ACL was not reconstructed (Table 1).

Table 1. Functional results

Evaluation method	Preoperative scores	Postoperative scores	<i>p</i>	<i>p</i> (A-B)	(A-C)	(B-C)
Lysholm	58.8±13.7	93.3±7.7	<0.001	>0.05	<0.001	<0.001
Group A	52.4	92.9				
Group B	58.7	97.0				
Group C	65.5	90.0				
Tegner	3.5±1.0	6.0±1.6	<0.001	>0.05	<0.001	<0.001
Group A	3.3	6.2				
Group B	3.2	6.2				
Group C	4.0	5.5				
IKDC	52.8±10.5	91.4±4.0	<0.001	<0.001	<0.001	>0.05
Group A	46.3	92.9				
Group B	56.7	90.3				
Group C	53.3	91.0				

IKDC:International Knee Documentation Committee

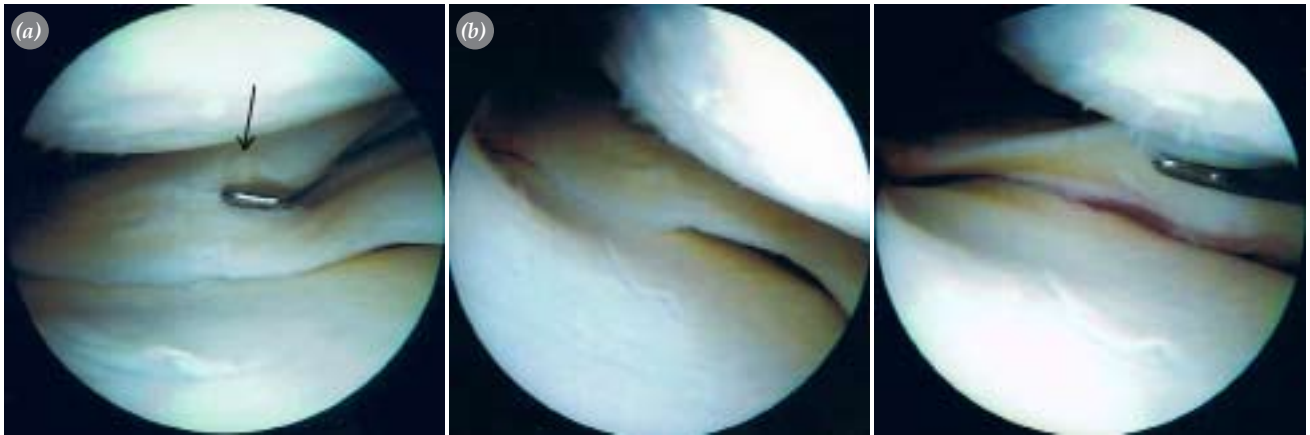


Figure 3. (a) The unabsorbed tophat. (b) Intraoperative photographs showing the healed meniscus.

All the patients were asked to return for clinical examination. They were evaluated according to Barrett's criteria. All repaired menisci demonstrated healing using these criteria. Only one of the patients who underwent meniscal repair for a red-red posterior horn tear with concomitant ACLR complained of persisting pain and swelling. A second-look arthroscopy was performed for this patient and it was seen that one of the tophats of two RapidLoc was not absorbed (Figure 3a and b). However, we observed that repaired meniscus was healed. After the arthroscopic removal of the unabsorbed tophat, the complaints of the patient discontinued. The knees of the 13 patients with ACL lesions that did not undergo ACLR were not unstable and functional outcome after the surgery for these patients was considered to be good.

None of the patients had neurovascular or infectious complication.

Discussion

Before deciding for meniscal repair; the location and stability of the tear, presence of an ACL rupture, patient's age and a good candidate for the rehabilitation protocol are of much importance to be kept in mind. [1,2,8,9,14,15] In our series of 57 patients, the youngest 17 and oldest 33, all the tears ranged between 10 to 35 mm in length and were vertical. All our patients fulfilled the criteria for meniscal repair. We believe that the period between injury and surgery is important for the healing of the repaired meniscus as the degeneration that might deteriorate with time has an unfavorable impact.

The clinical healing rate for meniscal repairs range between 82% to 93% using the suture techniques and

the new meniscal repair devices used for all-inside meniscal repair should be compared with these. [5-7,16-21] All-inside meniscal repair is favoured nowadays as it is easier to perform, has a shorter surgery time and pose less risk to the neurovascular structures. [5-7,16,18,20,21] RapidLock is one of the all-inside repair device and it has a success rate of 65-90% in meniscus repair. [22-26]

However, higher cost, a chondral injury and synovitis due to non-absorption of implant are the important disadvantages of rigid fixators. [27-29] Although rigid fixation devices demonstrated short-term success; the results were not as expected in longer follow-up durations. [8,9] Complications like inflammatory reactions, cyst formation, migration, breakage and chondral injury are also more likely to be faced with the rigid second-generation devices. [7-9,18,27-29]

RapidLoc device revealed characteristics findings compared with the horizontal inside-out suture technique and biomechanical analysis of the design demonstrated to be a good alternative to conventional suture techniques. [30-32] There are some complications related to the two most commonly used all-inside meniscal repair devices, Fast-Fix and RapidLock. [33-34] However, we did not experience complications like these and consider that this could be attributed to the flexible design of the device and to performing this procedure meticulously.

In our series of 57 patients none of them complained of ongoing symptoms when invited for clinical examination except one patient. His complaints were swelling, pain with hyperflexion. 6 months after the repair, we performed a second-look arthroscopy

and detected that one of the two tophats used was not absorbed but there was not any chondral injury. The unabsorbed tophat was removed arthroscopically and as the patient was free of symptoms 3 months after the second-look arthroscopy, we assumed the unabsorbed tophat to be the reason.

We had a concern about the 13 patients who did not undergo ACL reconstruction because they refused it. As there are unsatisfying results reported for meniscal repairs performed in ACL deficient knees,^[9,16-18] but our patients did not have any complaints even though statistical analysis for these patients demonstrated a reduced satisfaction. Our previous reports demonstrated that meniscus repair had better results if it's performed simultaneously with ACL reconstruction.^[17,18] Many study reported that fibrin clot from tunnels during drilling, contributes meniscal healing. In contrast, some studies reported different results in this context.^[5,21,23,35-38] The most important one was reported by Lapprell et al.^[20] In this study, meniscus repair was performed for 17 patients, then ACL rupture was reconstructed 6-8 after meniscus repair. Meniscus was found as healed and stable on second operation. Therefore, they concluded that meniscus healing is high even in unstable knees. In addition, we proposed that there were three possibilities for meniscal healing for those 13 patients in our study. The first possibility is that the patients had no complaints because their knees were stable and the shearing stresses on the repair were not as much as frighened. Second, despite the clinical findings, there might be only partial healing and these patients can be come symptomatic in the future. Third and most important one is that their meniscus ruptures were placed on meniscocapsular junction of lateral meniscus, meniscus tears in patients with an average of 24 age, and those ruptures repaired within three weeks. Therefore, we believe that meniscus healing might be high even though ACL reconstruction is not performed.

On the other hand, evaluation of meniscal healing by clinic examination is a weak point of this study. However, MRI sometimes gives a false positive or false negative result. Although arthro-MRI is known more useful, it's specificity and reliability is not 100%.^[39-41] In addition, a very good relationship is necessary between radiologist and surgeon. Unfortunately, we did not have a good cooperatooon because of impos-

sibility. Although second-look arthroscopy is a gold standart to evaluate the meniscal healing, it could not be performed due to ethic and economic reason. Therefore, meniscal healing is evaluated by clinic scores^[5,7,9,16,20-25] except a few study.^[20,36] We also used Barret scores for the evaluation of meniscal healing.

The importance of meniscal preservation and repairing the torn menisci if possible, is clearly illustrated by different authors previously.^[5-7,13-17,19] In this retrospective study, we aimed at determining whether this flexible all-inside meniscal repair device could be a good choice for repair or not. As very well known meniscal repairs using double-vertical mattress suture technique have the highest healing rates and is still the gold-standard for meniscal repair.^[17,18,30-32] The results should be compared with this suture technique. According to the intermediate term results we achieved, RapidLoc is as reliable as suture techniques. The results we achieved 100% healing even though unstable knees exists, and isolated meniscal repair was performed for some patients, is the best results compared to literature. However, it should be kept in mind that this results obtained from clinical scores and we believe that it should be supported by second-look arthroscopy and that should be waited for longer term follow-up.

The inside-out and outside-in suture techniques need more experience and may result in more complications for the less-experienced surgeons. In addition, meniscal repair with the conventional suture techniques, operation time is longer compared to all-inside meniscal fixators. Albrecht-Olsen et al reported that meniscus repair with arrows is 50% faster than conventional sutures technique.^[5] Hantes et al reported that meniscal repair with conventional suture techniques was significantly longer.^[23] Laprell et al stated that the average time of 29 (range, 18-39) minutes with all inside meniscal fixation.^[20] Steenbrugge et al reported that a short operation time, easy application, and less complication rate are the advantages of all-inside meniscal fixation.^[21] Authors stated that an average of operation time was 25 (range, 15-35) minutes in this study. Meniscal repair with RapidLock is shorter compared to conventional suture techniques according to literature. Moreover, as there is no need for posterolateral and posteromedial portals with this all-inside technique, the risk for neurovascular injury is less and the operative time is shortened.

A clinical evaluation of the meniscus healing according to Barrett's criteria, is one of the weak points in our study. We believe that second-look arthroscopy should be performed if it is possible. Unfortunately, we could not perform a second look arthroscopy for all patients except one because of cost and ethical considerations. However, based on Barrett's criteria and successful functional results, we consider that a repaired meniscus is completely or at least partially healed when the patient is asymptomatic. A second issue is that this study is not comparative to either conventional suture techniques or all inside materials. There is an excellent study reported by Kalliakmanis et al in this context.^[25] According to their results, there were no significant differences among the three different (Fast-Fix, T-Fix, and RapidLock) all-inside meniscal fixators regarding meniscal healing with an average of 24.5 months follow-up.

Despite the lack of long-term follow-up results, we believe that RapidLoc device is a good choice for the treatment of meniscal rupture in selected cases because of easy application compared to conventional suture techniques, satisfactory short-term clinical results, comparable biomechanical strength, shorter operative time, and low complication rate.

References

1. Cannon WD Jr. Arthroscopic meniscal repair. In: Insall JN, Scott WN, editors. *Surgery of the knee*. 3rd ed. Philadelphia: Churchill Livingstone; 2001. p. 521-44.
2. DeHaven KE. Meniscus repair-open vs. arthroscopic. *Arthroscopy* 1985;1:173-4.
3. Ikeuchi H. Arthroscopic treatment of the discoid lateral meniscus. Technique and long-term results. *Clin Orthop Relat Res* 1982;(167):19-28.
4. Morgan CD. The "all-inside" meniscus repair. *Arthroscopy* 1991;7:120-5.
5. Albrecht-Olsen P, Kristensen G, Burgaard P, Joergensen U, Toerholm C. The arrow versus horizontal suture in arthroscopic meniscus repair. A prospective randomized study with arthroscopic evaluation. *Knee Surg Sports Traumatol Arthrosc* 1999;7:268-73.
6. Petsche TS, Selesnick H, Rochman A. Arthroscopic meniscus repair with bioabsorbable arrows. *Arthroscopy* 2002;18:246-53.
7. Sarimo J, Rantanen J, Tarvainen T, Härkönen M, Orava S. Evaluation of the second-generation meniscus arrow in the fixation of bucket-handle tears in the vascular area of the meniscus. A prospective study of 20 patients with a mean follow-up of 26 months. *Knee Surg Sports Traumatol Arthrosc* 2005;13:614-8.
8. Kurzweil PR, Tifford CD, Ignacio EM. Unsatisfactory clinical results of meniscal repair using the meniscus arrow. *Arthroscopy* 2005;21:905.
9. Lee GP, Diduch DR. Deteriorating outcomes after meniscal repair using the Meniscus Arrow in knees undergoing concurrent anterior cruciate ligament reconstruction: increased failure rate with long-term follow-up. *Am J Sports Med* 2005;33:1138-41.
10. Lysholm J, Gillquist J. Evaluation of knee ligament surgery results with special emphasis on use of a scoring scale. *Am J Sports Med* 1982;10:150-4.
11. Tegner Y, Lysholm J, Lysholm M, Gillquist J. A performance test to monitor rehabilitation and evaluate anterior cruciate ligament injuries. *Am J Sports Med* 1986;14:156-9.
12. Irrgang JJ, Ho H, Harner CD, Fu FH. Use of the International Knee Documentation Committee guidelines to assess outcome following anterior cruciate ligament reconstruction. *Knee Surg Sports Traumatol Arthrosc* 1998;6:107-14.
13. Barrett GR, Field MH, Treacy SH, Ruff CG. Clinical results of meniscus repair in patients 40 years and older. *Arthroscopy* 1998;14:824-9.
14. Arnoczky SP, Bullough PG. Healing of knee ligaments and menisci. In: Insall JN, Scott WN, editors. *Surgery of the knee*. 3rd ed. Philadelphia: Churchill Livingstone; 2001. p. 457-71.
15. Easley ME, Cushner FD, Scott WN. Arthroscopic meniscal resection. In: Insall JN, Scott WN, editors. *Surgery of the knee*. 3rd ed. Philadelphia: Churchill Livingstone; 2001. p. 473-520.
16. Ahn JH, Wang JH, Yoo JC. Arthroscopic all-inside suture repair of medial meniscus lesion in anterior cruciate ligament-deficient knees: results of second-look arthroscopies in 39 cases. *Arthroscopy* 2004;20:936-45.
17. Aşık M, Şen C, Taşer ÖF, Sözen YV, Alturfan AK. Arthroscopic meniscal repair with the use of conventional suturing materials. [Article in Turkish] *Acta Orthop Traumatol Turc* 2002;36:228-35.
18. Aşık M, Şen C, Erginsu M. Arthroscopic meniscal repair using T-fix. *Knee Surg Sports Traumatol Arthrosc* 2002;10:284-8.
19. McCarty EC, Marx RG, DeHaven KE. Meniscus repair: considerations in treatment and update of clinical results. *Clin Orthop Relat Res* 2002;(402):122-34.
20. Laprell H, Stein V, Petersen W. Arthroscopic all-inside meniscus repair using a new refixation device: a prospective study. *Arthroscopy* 2002;18:387-93.
21. Steenbrugge F, Verdonk R, Hürel C, Verstraete K. Arthroscopic meniscus repair: inside-out technique vs. Bio-fix meniscus arrow. *Knee Surg Sports Traumatol Arthrosc* 2004;12:43-9.
22. Barber FA, Coons DA, Ruiz-Suarez M. Meniscal repair with the RapidLoc meniscal repair device. *Arthroscopy* 2006;22:962-6.

23. Hantes ME, Zachos VC, Varitimidis SE, Dailiana ZH, Karachalios T, Malizos KN. Arthroscopic meniscal repair: a comparative study between three different surgical techniques. *Knee Surg Sports Traumatol Arthrosc* 2006;14:1232-7.
24. Quinby JS, Golish SR, Hart JA, Diduch DR. All-inside meniscal repair using a new flexible, tensionable device. *Am J Sports Med* 2006;34:1281-6.
25. Kalliakmanis A, Zourntos S, Bousgas D, Nikolaou P. Comparison of arthroscopic meniscal repair results using 3 different meniscal repair devices in anterior cruciate ligament reconstruction patients. *Arthroscopy* 2008;24:810-6.
26. Billante MJ, Diduch DR, Lunardini DJ, Treme GP, Miller MD, Hart JM. Meniscal repair using an all-inside, rapidly absorbing, tensionable device. *Arthroscopy* 2008;24:779-85.
27. Aşık M, Atalar AC. Failed resorption of bioabsorbable meniscus repair devices. *Knee Surg Sports Traumatol Arthrosc* 2002;10:300-4.
28. LaPrade RF, Wills NJ. Kissing cartilage lesions of the knee caused by a bioabsorbable meniscal repair device: a case report. *Am J Sports Med* 2004;32:1751-4.
29. Gliatis J, Kouzelis A, Panagopoulos A, Lambiris E. Chondral injury due to migration of a Mitek RapidLoc meniscal repair implant after successful meniscal repair: a case report. *Knee Surg Sports Traumatol Arthrosc* 2005;13:280-2.
30. Miller MD, Blessey PB, Chhabra A, Kline AJ, Diduch DR. Meniscal repair with the Rapid Loc device: a cadaveric study. *J Knee Surg* 2003;16:79-82.
31. Kocabay Y, Chang HC, Brand JC Jr, Nawab A, Nyland J, Caborn DN. A biomechanical comparison of the FasT-Fix meniscal repair suture system and the RapidLoc device in cadaver meniscus. *Arthroscopy* 2006;22:406-13.
32. Naqui SZ, Thiryayi WA, Hopgood P, Ryan WG. A biomechanical comparison of the Mitek RapidLoc, Mitek Meniscal repair system, clearfix screws and vertical PDS and Ti-Cron sutures. *Knee* 2006;13:151-7.
33. Miller MD, Kline AJ, Gonzales J, Beach WR. Pitfalls associated with FasT-Fix meniscal repair. *Arthroscopy* 2002;18:939-43.
34. Cohen SB, Boyd L, Miller MD. Vascular risk associated with meniscal repair using Rapidloc versus FasT-Fix: comparison of two all-inside meniscal devices. *J Knee Surg* 2007;20:235-40.
35. Hanks GA, Gause TM, Handal JA, Kalenak A. Meniscus repair in the anterior cruciate deficient knee. *Am J Sports Med* 1990;18:606-11.
36. Horibe S, Shino K, Nakata K, Maeda A, Nakamura N, Matsumoto N. Second-look arthroscopy after meniscal repair. Review of 132 menisci repaired by an arthroscopic inside-out technique. *J Bone Joint Surg [Br]* 1995;77:245-9.
37. Tsai AM, McAllister DR, Chow S, Young CR, Hame SL. Results of meniscal repair using a bioabsorbable screw. *Arthroscopy* 2004;20:586-90.
38. Doral MN, Leblebecioğlu G, Atay A. Ön çapraz bağ yaralanması olan dizlerde menisküs yırtıklarının tedavisine yaklaşım. *Acta Orthop Traumatol Turc* 1999;33:426-9.
39. Applegate GR, Flannigan BD, Tolin BS, Fox JM, Del Pizzo W. MR diagnosis of recurrent tears in the knee: value of intraarticular contrast material. *AJR Am J Roentgenol* 1993;161:821-5.
40. Cılız D, Cılız A, Elverici E, Sakman B, Yüksel E, Akbulut O. Evaluation of postoperative menisci with MR arthrography and routine conventional MRI. *Clin Imaging* 2008;32:212-9.
41. Mathieu L, Bouchard A, Marchaland JP, Potet J, Fraboulet B, Danguy-des-Deserts M, et al. Knee MR-arthrography in assessment of meniscal and chondral lesions. *Orthop Traumatol Surg Res* 2009;95:40-7.