



## Evaluation of soft tissue reactions to three nonabsorbable suture materials in a rabbit model

### Üç değişik emilmeyen dikiş malzemesine karşı oluşan doku yanıtının tavşan modelinde incelenmesi

Cem Zeki ESENYEL,<sup>1</sup> Mehmet DEMIRHAN,<sup>2</sup> Onder KILICOGLU,<sup>2</sup> Oktay ADANIR,<sup>3</sup>  
Bilge BILGIC,<sup>4</sup> Ozlem GUZEL,<sup>5</sup> Serhat OZSOY<sup>5</sup>

<sup>1</sup>Vakıf Gureba Research and Training Hospital, Orthopedics and Traumatology Department,; <sup>2</sup>Istanbul University, Faculty of Medicine, Orthopedics and Traumatology Department, <sup>4</sup>Istanbul University, Faculty of Medicine, Pathology Department; <sup>3</sup>Bagcılar Research and Training hospital, Orthopedics and Traumatology Department Ortopedi ve Travmatoloji Kliniği; <sup>5</sup>Istanbul University, Faculty of Veterinary Medicine

**Amaç:** Sık kullanılan üç emilmeyen dikiş malzemesinin dokuda oluşturduğu enflamatuvar yanıtlar tavşan modelinde değerlendirildi.

**Çalışma planı:** Çalışmada, örgülü polyester (Ethibond), monofilaman polipropilen (Polypropylene) ve örgülü polietilen ve polyester karışımı (FiberWire) dikiş malzemesi kullanıldı. Otuz altı adet tavşan, kullanılan dikiş materyaline göre, eşit sayıda üç gruba ayrıldı. Her bir dikiş malzemesi tavşanın her iki bacağındaki kuadriseps kasına, patellar tendona, diz eklem kapsülüne ve Aşil tendonuna uygulandı. Her gruptaki altışar tavşan üçüncü ve altıncı haftalarda öldürüldü. Dikiş malzemesinin oluşturduğu enflamatuvar yanıt ışık mikroskobu kullanılarak değerlendirildi ve enflamatuvar alanın genişliği ölçüldü.

**Sonuçlar:** Üçüncü haftada kas ve tendonda en şiddetli enflamatuvar yanıtı Ethibond oluştururken, Ethibond'a bağlı yanıt altıncı haftada tüm dokularda en az düzeydeydi. Üçüncü haftada Propilen'in oluşturduğu yanıt orta düzeyde iken, altıncı haftada tüm dokularda en geniş enflamatuvar alana sahipti. Altıncı haftada kasta Propilen'in oluşturduğu enflamatuvar alan genişliği (6.6±2.1 mm) Ethibond'un oluşturduğundan (1.6±0.9 mm) anlamlı derecede fazlaydı (p<0.05). FiberWire üçüncü haftada eklem kapsülünde en geniş enflamatuvar yanıtı oluşturdu, fakat diğer dokularda üçüncü ve altıncı haftalarda oluşan enflamatuvar yanıt düşük veya orta düzeydeydi. İki kas ve bir tendon örneğinde FiberWire'a bağlı bazı nekrotik alanlar görüldü.

**Çıkarımlar:** Emilmeyen dikiş malzemelerine karşı oluşan enflamatuvar yanıt, materyalin cinsine, doku tipine ve ameliyat sonrası geçen süreye bağlıdır.

**Anahtar sözcükler:** Yabancı cisim reaksiyonu; enflamasyon; eklem kapsülü; kas; polipropilen; ameliyat sonrası komplikasyon; tavşan; dikiş/yan etki; tendon.

**Objectives:** We evaluated the inflammatory reactions induced by three commonly used nonabsorbable suture materials in a rabbit model.

**Methods:** Three suture materials were tested: braided polyester suture (Ethibond), braided blend of polyester and polyethylene suture (FiberWire), and monofilament polypropylene suture (Polypropylene). Thirty-six rabbits were randomly allocated to three suture groups, equal in number. Each suture type was placed bilaterally in the quadriceps muscle, patellar tendon, knee joint capsule, and Achilles tendon. Six animals in each group were sacrificed in the third and sixth weeks. The inflammation induced by each suture was assessed using light microscopy and the width of the inflammation zone (WIZ) was measured.

**Results:** Ethibond was found to cause the most severe reaction in the muscle and tendon in the third week; in the sixth week, however, it showed the lowest inflammatory reaction in all tissue types. Reaction to Propylene was moderate in the third week, whereas it caused the largest WIZ in all tissue types in the sixth week, such that the eventual size of the WIZ induced by Propylene (6.6±2.1 mm) was significantly greater than that of Ethibond (1.6±0.9 mm) in muscle specimens (p<0.05). Except for the largest WIZ seen in joint capsule specimens in the third week, inflammatory reactions associated with FiberWire were low or moderate in all tissue specimens throughout the study. FiberWire was associated with some necrotic areas in two muscle and one tendon specimens.

**Conclusion:** The extent of inflammatory reaction to nonabsorbable suture materials depends on the type of suture material, tissue type, and the duration of postoperative time.

**Key words:** Foreign-body reaction/complications; inflammation; joint capsule; muscles; polypropylenes; postoperative complications; rabbits; sutures/adverse effects; tendons.

**Correspondence / Yazışma adresi:** Dr. Cem Zeki Esenyel. Vakıf Gureba Research and Training Hospital, Orthopedics and Traumatology Department, Adnan Menderes Bulvarı, 34296 Fatih, İstanbul. Phone: +90212 - 534 69 00 / 1689 e-mail: esenyel@yahoo.com

**Submitted / Başvuru tarihi:** 29.07.2008 **Accepted / Kabul tarihi:** 06.05.2009

© 2009 Türk Ortopedi ve Travmatoloji Derneği / © 2009 Turkish Association of Orthopaedics and Traumatology

Suture materials are indispensable implants of all types of surgeries. While choosing a suture material, some basic criteria should be taken into consideration: <sup>[1]</sup> Initial fixation strength should provide adequate tissue fixation, <sup>[2]</sup> the suture materials should provide adequate fixation strength during the critical healing period too and <sup>[3]</sup> tissue reaction to the suture material should not interfere with tissue healing and suture holding capacity.<sup>[1, 2, 3]</sup>

All surgical suture materials cause some degree of inflammatory reaction. The extent of reaction zone around a suture material is inversely proportional to the holding power of tissue and suture material.<sup>[4,5, 6]</sup> If the reaction zone is narrow, there will still be undamaged tissue left on both sides of the incision. On the contrary, if the reaction zone is wide, tissues on the both sides of the incision and tissues around the suture loop won't be able to resist traction on the sutures.<sup>[4]</sup> Also, suture material that elicits a severe and prolonged inflammatory reaction can affect negatively the healing process and render a wound more susceptible to infection. Therefore, the ideal suture material should remain there only long enough for tissue tensile strength to be regained, and inflammatory response that it produce should be acceptable in duration and severity.<sup>[7]</sup>

In this *in vivo* study; inflammatory response induced by three commonly used non absorbable suture materials (Two sutures are braided and the third one is mono filament.) in various tissues of rabbits on the third and sixth weeks were examined.

## Materials and methods

In this study three different 2-0 non absorbable suture material were used. These were <sup>[1]</sup> polypropylene (polypropylene 2/0, 3/8 circle–19mm taper cut needle; DemeTech, Miami, FL, USA),<sup>[2]</sup> a braided polyester (Ethibond 2/0, green coated, with a 3/8 circle–19 mm taper cut needle; Ethicon, Somerville, N.J., USA) and <sup>[3]</sup> a new blend of ultra high molecular weight polyethylene cored with braided polyester covering (FiberWire 2/0, blue coated, with a 3/8 circle – 18 mm taper cut needle; Arthrex, Naples, FL, USA). All sutures were atraumatic.

The study was performed on 36 New Zealand rabbits, weighing between 2000 to 2900 g, which were approximately eight months old. Animals were obtained from DETAE; (DTAE Experimental Medici-

ne Research Enstitute, Istanbul University, Istanbul, Turkey). The study protocol was approved by the Ethic Committee of the Istanbul University. All rabbits were cared according to the rules published by Ethic Committee for Experimental Studies.

The animals were randomly classified into three groups according to the suture material used, each consisting of 12 rabbits: polypropylene group, Ethibond group and the FiberWire group. Each group was further divided into two subgroups (as A and B). In each subgroup there were six rabbits. Animals in subgroup A were killed in the third postoperative week and animals in subgroup B were killed in the sixth postoperative week.

### Operative procedure

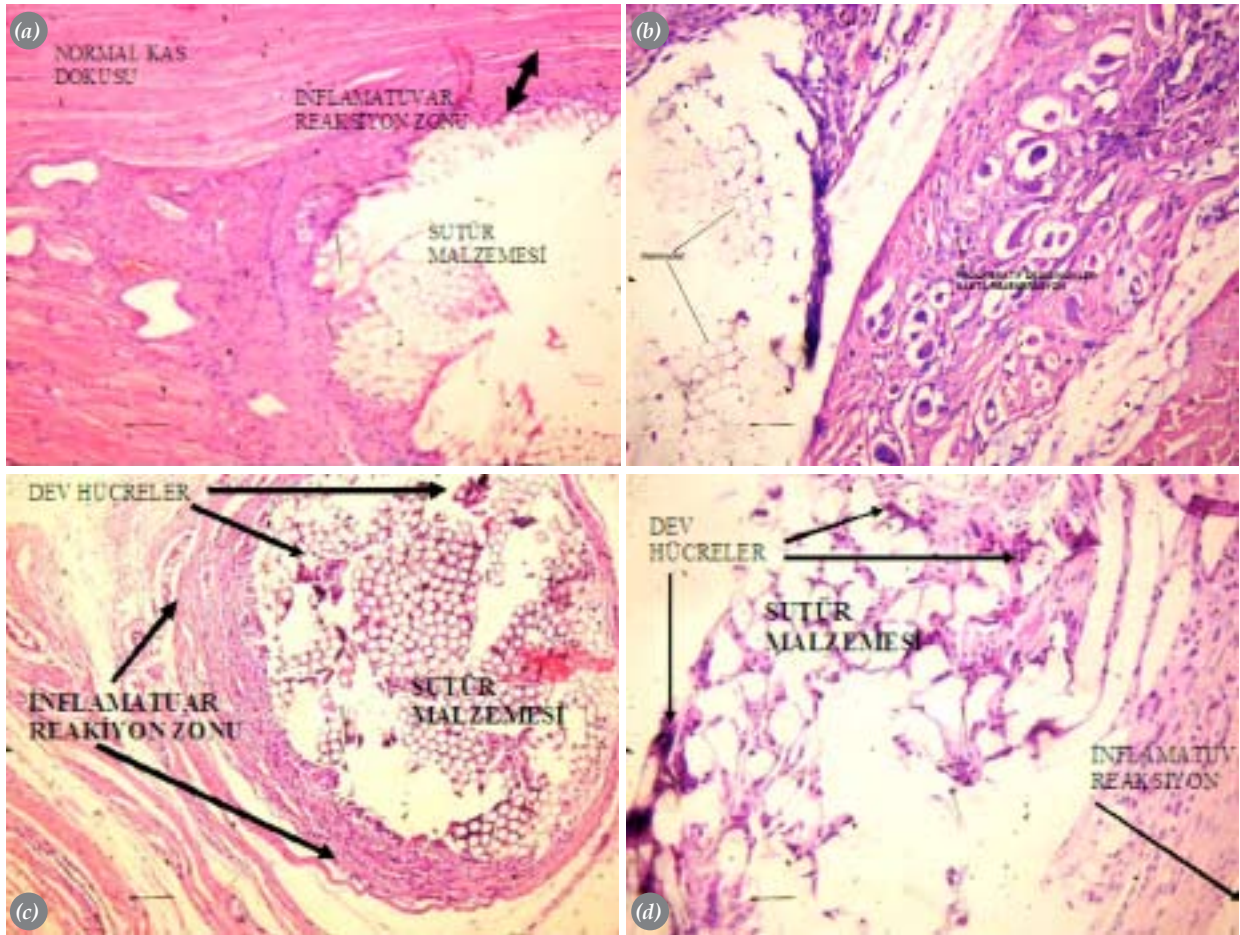
A 22G catheter was placed in the lateral ear vein for intravenous injection. For anesthesia 10mg/kg induction dose of propofol was used, then a continuous propofol infusion of 30 ml/h (10 mg/ml) was given during the surgery.

Both lower extremity of the rabbits were shaved and disinfected with 10% iodine solution. The operation field was prepared under sterile conditions. Using a 2 cm long anterior longitudinal skin incision and subcutaneous blunt dissection; the quadriceps muscle, knee joint capsule and the patellar tendon were reached. The sutures were placed and tied transversely through the quadriceps muscle, the anterior of knee joint capsule, and the patellar tendon from medial to lateral direction.

After a second skin incision was made through both Achilles tendons, Achilles tendon was reached, then sutures were placed and tied transversly in the same direction.

Each suture was knotted five times, without any compression at the soft tissue. The skin was closed by using 2-0 silk sutures. The rabbits were fed by a regular diet and complications were evaluated daily for morbidity and mortality.

Animals in subgroups A were killed at the third week and animals in subgroups B were killed at the sixth week after the surgery with an over dose of sodium pentobarbital. Skin of both lower extremity was dissected and removed. Material was sent to the pathology laboratory in %10 formaline solution to be examined.



**Figure 1.** Images of the haematoxylin-eosin stained samples which shows the inflammatory reaction and suture material under light microscope (x50 magnification) (a) Images of muscle sample at sixth week and suture material ethibond and (b) fiberwire. (c) Image of achilles tendon sample at the third week. Ethibond was used as a suture material. (d) Image of patellar tendon sample at the sixth week. Fiberwire was used as a suture material. Also a few number of giant cell can be seen around the suture material.

### Histopathological examination

After placing in paraplast, specimens were obtained by serial cuts of 5  $\mu$ m. Then it was stained with haematoxylin-eosin and van Gieson-Hansen methods. Histopathological evaluations were performed by the pathology specialist under a light microscope.

In evaluation of the inflammatory reaction, previously described techniques were utilized [5, 6, 8] Width of the inflammatory zone was used for evaluation. Distance from the suture material to the end of the reaction zone was marked and measured in millimeters (figures 1).

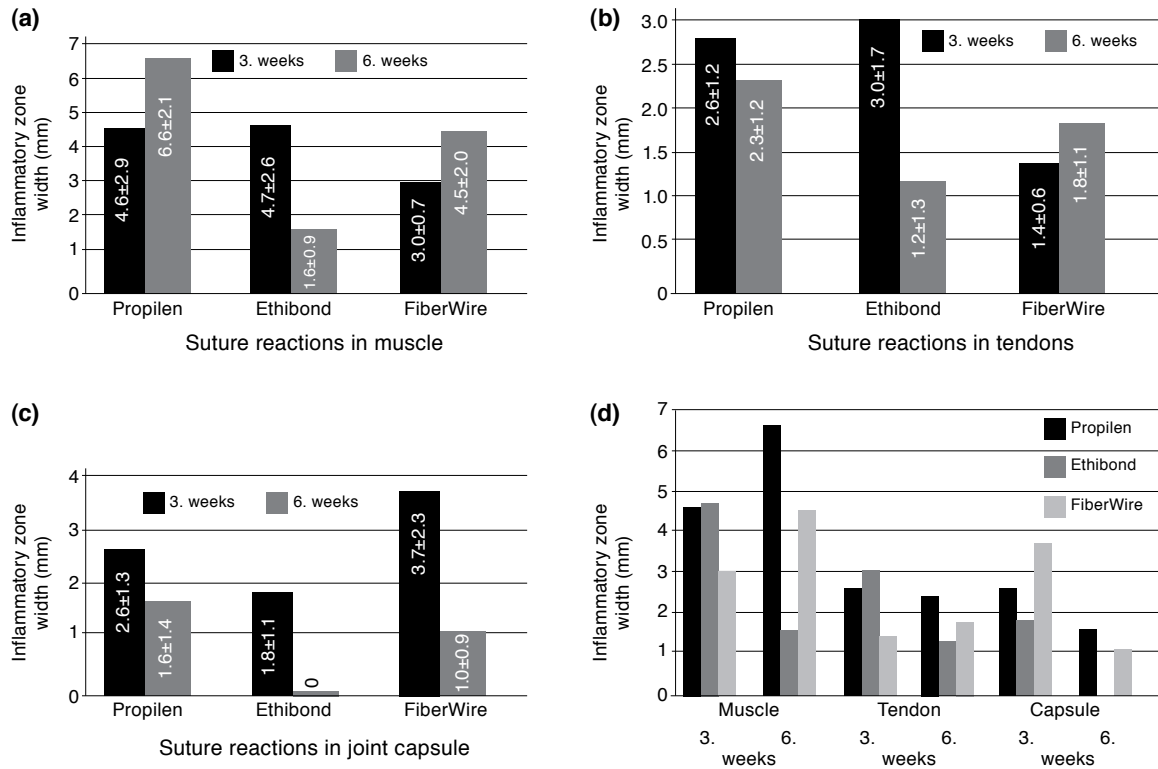
Presence of inflammation and types of inflammatory cells were also recorded for each specimen.

### Statistical evaluation

Kruskal Wallis variance analysis test was used to assess any difference between tissue reactions against all three suture materials at third and sixth weeks. Mann Whitney U test was used to identify which specific groups were significantly different. P values less than 0.05 were considered as statistically significant. All statistical analyses were performed with SPSS for Windows standard version 10.0.1 software. .

### Results

An animal in polypropylene group died nine days after surgery and an animal from fiberwire group died twelve days after surgery. The cause of death was disseminated infection for both of the animals. These animals were not replaced. No other complications



**Figure 2.** Inflammatory reactions against three different suture material at the third and sixth week in (a) muscle (b) tendon and (c) joint capsule (d) suture reactions in muscle, tendon and capsule at third and sixth weeks.

were observed in the postoperative period.

Results according to the investigated suture type on muscle, joint capsule and tendon samples are summarized in figure 2.

### Polypropylene

Polypropylene caused a moderate inflammatory response in all tissue groups in the third week. In the sixth week, a slight decrease in width of inflammatory zone (WIZ) was observed in tendon and capsule samples and a statistically significant increase in the muscle samples ( $p < 0,05$ ). This increase was also accompanied by fibrotic changes. Polypropylene was found to cause the most severe inflammatory response in all tissue types in the sixth week (Figure 2d). In the sixth week, there was a statistically significant difference between the inflammatory reaction against polypropylene ( $6,6 \pm 2,1$  mm) and the Ethibond suture materials ( $1,6 \pm 0,9$  mm) in the muscle specimens ( $p < 0,05$ ) (Figure 2a).

### Ethibond

While Ethibond caused the most severe inflammatory reaction in the muscle and tendon speci-

mens at the third week, it showed the least inflammatory reaction in all tissue types at the sixth week. This change was due to the obvious decrease in the inflammation against the Ethibond ( $p > 0,05$  for all tissue types). Ethibond also was the suture material which caused the least reaction in the joint capsule and synovium both in the third and sixth weeks. On the sixth week, nearly no reaction was observed by Ethibond in the joint capsule. At the third week, the WIZ in the joint capsule caused by FiberWire ( $3,7 \pm 2,3$  mm) was significantly wider compared to Ethibond group ( $1,8 \pm 1,1$  mm) ( $p < 0,05$ ).

Neutrophilic polymorphonuclear leukocytes, plasmacytes and giant cells were seen in the microscopic evaluation of the inflammatory response. Together with fibrosis degenerative and regenerative changes were observed in muscle samples. These findings were very low at sixth week.

### FiberWire

FiberWire had the lowest WIZ values in the muscle and tendon samples at the third week, but it produced the most severe inflammatory reaction ( $3,7 \pm 2,3$  mm) in the joint capsule. Compared to inflammatory

reaction against Ethibond, the inflammatory reaction against FiberWire was significantly higher. At the sixth week, the WIZ against FiberWire was narrower compared to polypropylene, but still wider than the Ethibond in all tissue types. The sixth week results of FiberWire were found to be significantly decreased compared to the third week results in the joint capsule ( $p < 0,05$ ).

Furthermore interestingly, necrotic areas were observed in two muscle and one tendon specimens at the third week.

## Discussion

All three suture material used in this study showed inflammatory reaction in muscle, tendon and joint capsule. Although fiberwire showed the most severe reaction in joint in the first weeks; significant decrease in the inflammatory reaction was observed at the sixth week. Ethibond was the suture material that produced the least inflammatory reaction in all weeks.

All three suture material produced significant inflammatory reaction in tendon. Although the reaction against ethibond was the most in third week, ethibond was the suture material which showed the least inflammatory response in sixth week. Although the inflammatory reaction against fiberwire seem to be increasing, this increase was not statistically significant at the sixth week.

But in muscle inflammatory reaction against propilen and fiberwire increased by time. Only inflammatory reaction against ethibond was decreased by time. This decrease was statistically significant in sixth week compared to third week.

The search for the ideal suture has continued for years.<sup>[9]</sup> The ideal suture material should be strong enough to withstand physiological loads during postoperative healing and rehabilitation periods.<sup>[10]</sup> Retarded healing might result from inflammatory reactions caused by suture material themselves. Therefore tissue reaction to these materials is one of the crucial factors that affects the success of surgery.

The preferred technique to determine the severity of the reaction quantitatively was used in previous similar studies.<sup>[5, 6, 8]</sup> This technique allow to measure the width of the inflammation zone from the periphery of the suture outward, independent of the

shape of the suture. The size of the material does not influence the analysis, allowing comparison between suture types with different diameters.<sup>[12]</sup>

Three types of nonabsorbable suture materials, which are frequently used in orthopaedic surgery, were tested in the study. The third and sixth weeks were selected as the experimental intervals because these periods are frequently used in clinical practice of tendon and capsule operations.

Propilen suture is a monofilament, synthetic, non-absorbable, sterile surgical suture composed of polypropylene.<sup>[11, 12]</sup> Polypropylene sutures are often used in cardiovascular, ophthalmic, neurologic and orthopaedic surgery for soft tissue approximation and ligation.<sup>[13]</sup> Polypropylene suture material has been successfully used in contaminated and infected wounds to eliminate or minimize later sinus formation and suture extrusion.<sup>[12]</sup> Polypropylene is reported to elicit a minimal acute inflammatory reaction in tissues, which is followed by gradual encapsulation of the suture material by a fibrous connective tissue.<sup>[12, 14]</sup> Studies has shown that monofilament suture materials produce less tissue reaction than multifilament suture materials.<sup>[16]</sup> In contrast to these reports, our results indicate a significant inflammatory reaction against polypropylene in all tissue types both in the third and sixth weeks.

Ethibond is a non-absorbable and braided surgical suture. It consists of high molecular weight, long-chain, linear polyesters having recurrent aromatic rings as an integral component and coated with polybutylate. Comparing with uncoated braided polyesters; with the help of its firm outer coating it produces relatively less tissue reaction and its mechanical properties became better. For better visibility in the surgical field it died to green.<sup>[12]</sup>

Ethibond is often used for repair of the capsule, tendons, and muscles in orthopaedic surgeries. Although Ethibond caused the most severe inflammatory reaction in the muscle and tendon at the third week, the least severe inflammatory reaction was seen against the Ethibond in all tissues at the sixth week. At the sixth week nearly no inflammatory reaction was seen in joint capsule and synovial tissue.

FiberWire is a braided, nonabsorbable, polyblend suture that has been marketed as an alternative to Ethibond. This polyblend suture showed significantly

higher ultimate failure load and a different mechanism of failure compared to Ethibond suture.<sup>[15-18]</sup>

In our study, FiberWire caused the least inflammatory reaction in the muscle and tendon at third week, but the inflammatory reaction against the suture was increased in tendon and muscle at sixth week. The inflammatory reaction seen at sixth week was less than polypropylene, but more than Ethibond. FiberWire caused the most severe inflammatory reaction in the joint capsule at third week but this inflammatory reaction was significantly reduced at sixth week. Produced reaction was higher than the inflammatory reaction produced by Ethibond but there wasn't any statistically significance.

Necrotic areas were observed in two muscle specimens and one tendon specimen in the FiberWire group. Review of recent literature did not reveal any necrosis as a response to FiberWire suture. In general, two types of foreign body tissue reactions can occur. One is the typical nonallergic, foreign-body giant-cell reaction in which the predominant cells are multinucleated giant cells and histiocytes, where necrosis is not present. The other is an allergic hypersensitivity reaction that may cause tissue necrosis. Suture materials usually produce a nonallergic giant cell reaction with no necrotic changes.<sup>[19, 20, 21]</sup> Although the foreign body associated necrobiotic granulomas may be caused by direct toxic action of the foreign material, more commonly they are the result of a hypersensitivity reaction to foreign material or to altered collagen. The fact that nonabsorbable suture material can induce necrobiotic granulomas is not commonly known.<sup>[19]</sup> Marcus et al described two cases of silk sutures triggering a hypersensitivity response with necrobiotic granulomas of periarticular soft tissue, eroding into bone and joint.<sup>[21]</sup>

In general, suture granulomas are more commonly seen with nonabsorbable sutures. Among the multifilament nonabsorbable sutures, granulomas are more commonly seen in response to polyester. However, suture granulomas have been associated with other suture materials.<sup>[12, 14, 22-26]</sup>

A limitation of the study that needs to be mentioned is that the biomechanical properties of the soft tissues were not investigated; but this is not a major limitation of the present study, because the study was designed to investigate the inflammatory response to

various non-absorbable suture materials.

As a conclusion; the results of this study showed that reaction against non absorbable suture materials are dependent on the suture and tissue type and also postoperative time. Results also indicated several important findings:

-In muscle and tendon specimens, the inflammatory reaction against Ethibond was higher than FiberWire and Propilen at the third week.

-Ethibond showed less tissue reaction when compared to FiberWire and polypropylene in all tissues at the sixth week.

-In the joint capsule and synovium, Ethibond showed the weakest inflammatory reaction in all tissues at third and sixth weeks.

-In the joint capsule and synovium, FiberWire produced the most severe inflammatory reaction at the third week, while, this reaction was remarkable reduced to the level of Ethibond at the sixth week.

Under the light of these results; Ethibond was the suture material that produces the least inflammatory response in muscle, tendon and joint capsule at the sixth week. At the sixth week ethibond can be preferred in muscle and tendon surgeries against propylene, because the inflammatory reaction against propylene seem to be increasing through third to sixth week. The inflammatory response against fiberwire increases with time both in muscle and tendon specimens. Also necrotic areas were observed against fiberwire in muscle and tendon specimens. Nearly no reaction was observed at the late period in joint capsule against Ethibond; but some degree of inflammatory reaction was observed against the other two suture material. So we can say that Ethibond is a safe material in intraarticular procedures.

## References

1. Altman GH, Diaz F, Jakuba C, Calabro T, Horan RL, Chen J, et al. Silk-based biomaterials. *Biomaterials* 2003; 24:401-16.
2. Bakkum EA, Dalmeijer RA, Verdel MJ, Hermans J, van Blitterswijk CA, Trimbos JB. Quantitative analysis of the inflammatory reaction surrounding sutures commonly used in operative procedures and the relation to postsurgical adhesion formation. *Biomaterials* 1995;16:1283-9.
3. Barber FA, Herbert MA, Richards DP. Sutures and suture anchors: update 2003. *Arthroscopy* 2003;19:985-90.

4. Madsen ET. An experimental and clinical evaluation of surgical suture materials. *Surg Gynecol Obstet* 1953;97:73-80.
5. van Rijssel EJ, Brand R, Admiraal C, Smit I, Trimbos JB. Tissue reaction and surgical knots: the effect of suture size, knot configuration, and knot volume. *Obstet Gynecol* 1989;74:64-8.
6. van Rijssel EJ, Trimbos JB, da Costa A, Fleuren GJ, Brand R. Assessment of tissue reaction at suture knots; an adaptation of Sewell's scoring system. *Eur J Obstet Gynecol Reprod Biol* 1988;27:165-72.
7. Runk A, Allen SW, Mahaffey EA. Tissue reactivity to poliglecaprone 25 in the feline linea alba. *Vet Surg* 1999;28:466-71.
8. Sewell WR, Wiland J, Craver BN. A new method of comparing sutures of ovine catgut with sutures of bovine catgut in three species. *Surg Gynecol Obstet* 1955;100:483-94.
9. Setzen G, Williams EF 3rd. Tissue response to suture materials implanted subcutaneously in a rabbit model. *Plast Reconstr Surg* 1997;100:1788-95.
10. Rupp S, Georg T, Gauss C, Kohn D, Seil R. Fatigue testing of suture anchors. *Am J Sports Med* 2002;30:239-47.
11. Beauchamp PJ, Guzik DS, Held B, Schmidt WA. Histologic response to microsuture materials. *J Reprod Med* 1988;33:615-23.
12. Capperauld I. Suture materials: a review. *Clin Mater* 1989;4:3-12.
13. Sánchez-Morillas L, Reaño Martos M, Rodríguez Mosquera M, Iglesias Cadarso A, Pérez Pimiento A, Domínguez Lázaro AR. Delayed sensitivity to Prolene. *Contact Dermatitis* 2003;48:338-9.
14. Skrypuch OW, Willis NR. Giant papillary conjunctivitis from an exposed prolene suture. *Can J Ophthalmol* 1986;21:189-92.
15. De Carli A, Vadalà A, Monaco E, Labianca L, Zanzotto E, Ferretti A. Effect of cyclic loading on new polyblend suture coupled with different anchors. *Am J Sports Med* 2005;33:214-9.
16. Lawrence TM, Davis TR. A biomechanical analysis of suture materials and their influence on a four-strand flexor tendon repair. *J Hand Surg [Am]* 2005;30:836-41.
17. Lo IK, Burkhart SS, Chan KC, Athanasiou K. Arthroscopic knots: determining the optimal balance of loop security and knot security. *Arthroscopy* 2004;20:489-502.
18. Lo IK, Burkhart SS, Athanasiou K. Abrasion resistance of two types of nonabsorbable braided suture. *Arthroscopy* 2004;20:407-13.
19. Alguacil-Garcia A. Necrobiotic palisading suture granulomas simulating rheumatoid nodule. *Am J Surg Pathol* 1993;17:920-3.
20. Lynch TH, Waymont B, Beacock CJ, Wallace DM. Paravesical suture granuloma: a problem following herniorrhaphy. *J Urol* 1992;147:460-2.
21. Marcus VA, Roy I, Sullivan JD, Sutton JR. Necrobiotic palisading suture granulomas involving bone and joint: report of two cases. *Am J Surg Pathol* 1997;21:563-5.
22. Evans CS, Goldman RL, Klein HZ, Kohout ND. Necrobiotic granulomas of the uterine cervix. A probable postoperative reaction. *Am J Surg Pathol* 1984;8:841-4.
23. Mies C, Balogh K, Stadecker M. Palisading prostate granulomas following surgery. *Am J Surg Pathol* 1984;8:217-21.
24. Mozaffar T, Lopate G, Pestronk A. Clinical correlates of granulomas in muscle. *J Neurol* 1998;245:519-24.
25. Spagnolo DV, Waring PM. Bladder granulomata after bladder surgery. *Am J Clin Pathol* 1986;86:430-7.
26. Williams GT, Williams WJ. Granulomatous inflammation-a review. *J Clin Pathol* 1983;36:723-33.