



Hyperphalangism accompanied by brachydactyly of the feet: a case report

S.S. SURESH, Raju ABRAHAM

Ibri Regional Referral Hospital, Ibri, Sultanate of Oman

Asymptomatic symmetrical hyperphalangism of the fingers accompanied by foot anomalies is very rare. We present a 21-year-old man with anomalies in both hands and feet. He had short little, index, and middle fingers, long ring fingers, and clinodactyly of the little finger. He also had symmetrical brachydactyly of both feet. There were no other skeletal anomalies and his family members were normal. Radiographic examination of the hand showed oblique articulation of the metacarpophalangeal joint of the index finger with ulnar deviation, hyperphalangism of the middle finger, brachydactyly of the middle phalanx of the little finger, and long proximal phalanx of the ring finger. Foot radiography showed dysplastic middle phalanx of the middle toe, with the remaining lesser toes having only two phalanges. The two feet were radiographically similar except for a dysplastic middle phalanx in the second and third toes of the right foot. Since the patient was not physically challenged, no treatment was offered.

Key words: Finger phalanges/abnormalities; fingers/abnormalities; toes/abnormalities.

Hyperphalangism is the presence of an extra phalanx between the phalanges, without an extra digit, and has been classified as brachydactyly C.^[1,2] There are five distinguishing features including an extra phalanx with four phalanges almost always in the index finger, short phalanges, long ring finger, oblique articulation of the metacarpophalangeal joint in the index finger, and small index, ring, and little fingers.^[1] Association with foot anomalies, though rare, has been described in the literature,^[1-3] but symmetrical brachydactyly of the toes has not been described before. Surgery is indicated only for cosmetic reasons or if the long ring finger interferes with hand function.^[1]

We present a male patient with anomalies in both hands and feet.

Case report

A 21-year-old man presented to the orthopedic clinic with trauma to his right knee, and was found to have anomalies in both hands and feet (Fig 1). He had

short little, index, and middle fingers, and long ring fingers. In addition, he had clinodactyly of the little finger. The grip was strong. He also had brachydactyly of both feet. There were no other skeletal anomalies. His parents and other siblings in the family were normal.

Radiographic examination of the hand showed oblique articulation of the metacarpophalangeal joint of the index finger with ulnar deviation, hyperphalangism of the middle finger, and brachydactyly of the middle phalanx of the little finger. The proximal phalanx of the ring finger was found long. A foot X-ray showed dysplastic middle phalanx of the middle toe, with the remaining lesser toes having only two phalanges. The two feet were radiographically similar except for a dysplastic middle phalanx in the second and third toes of the right foot.

Since the patient was not concerned about the deformity and was not physically challenged, no treatment was offered.

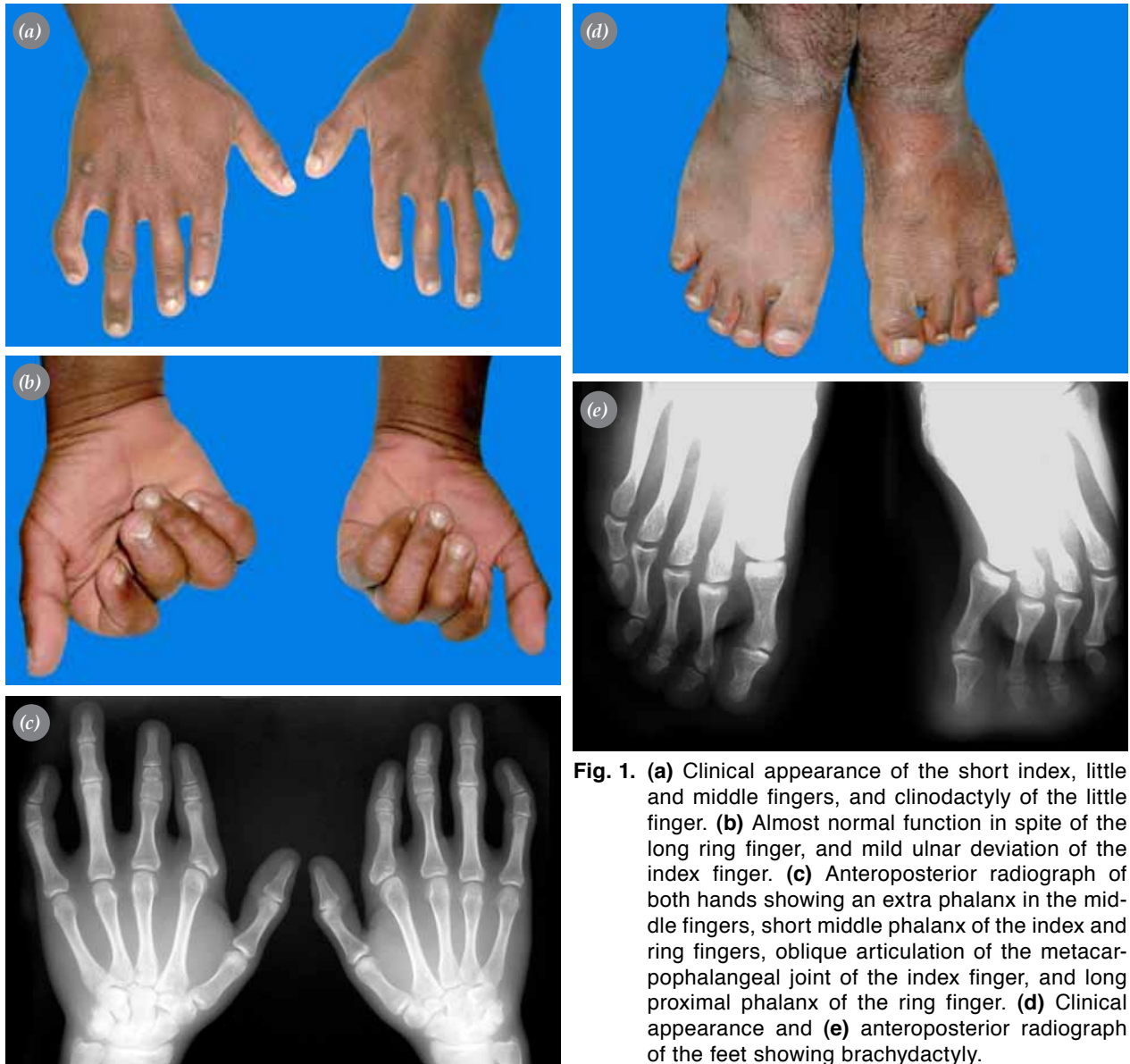


Fig. 1. (a) Clinical appearance of the short index, little and middle fingers, and clinodactyly of the little finger. (b) Almost normal function in spite of the long ring finger, and mild ulnar deviation of the index finger. (c) Anteroposterior radiograph of both hands showing an extra phalanx in the middle fingers, short middle phalanx of the index and ring fingers, oblique articulation of the metacarpophalangeal joint of the index finger, and long proximal phalanx of the ring finger. (d) Clinical appearance and (e) anteroposterior radiograph of the feet showing brachydactyly.

Discussion

Hyperphalangism is characterized by an extra phalanx between the phalanges of a finger excluding the thumb.^[4,5] Over 100 cases of hyperphalangism have been described in the literature.^[4,6] This autosomal dominant anomaly is classified as brachydactyly type C.^[1,2]

There are five distinguishing features, including hyperphalangism with four phalanges almost always in the index finger, short phalanges, long ring finger, oblique articulation of the metacarpophalangeal joint in the index finger, and small index, middle, and little fingers which are almost the same length as the thumb.^[1,4] Clinodactyly is a consistent feature.

Foot anomalies that are occasionally associated with hyperphalangism are clubfoot, brachyphalangism, and clinodactyly of the little toe.^[1-3]

Brachyphalangism of all the toes has not been reported before. Günel et al.^[4] did not find any foot anomaly in an analysis of 42 patients.

Hypoplasia of the first metacarpal with irregular outline of the proximal phalanges of the thumb has been reported.^[2] In our case, the first metacarpal was a bit short.

Most of the patients are functionally not incapacitated and do not require any treatment.^[1] Treatment is warranted only if the long ring finger interferes with

function because of ulnar deviation and overlapping of other digits.^[6] If so, shortening of ring finger is recommended.^[1]

References

1. Wood VE. Different manifestations of hyperphalangism. *J Hand Surg [Am]* 1988;13:883-7.
2. Rowe-Jones JM, Moss AL, Patton MA. Brachydactyly type C associated with shortening of the hallux. *J Med Genet* 1992;29:346-8.
3. Haws DV. Inherited brachydactyly and hypoplasia of the bones of the extremities. *Ann Hum Genet* 1963;26:201-12.
4. Günal I, Durak T, Öztuna V, Seber S. Various manifestations of hyperphalangism. *J Hand Surg [Br]* 1996;21:405-7.
5. Almasi A, Solgaard S. Polyphalangism-a rare anomaly. [Article in Danish] *Ugeskr Laeger* 2006;168:2472-3.
6. Wood VE. Hyperphalangism. In: Green DP, Hotchkiss RN, Pederson WC, editors. *Green's operative hand surgery*. Vol. 1, 4th ed. New York: Churchill Livingstone; 1998. p. 501-10.