



Unusual coalition of the carpal bones with simian crease: a case report

Saraswathivilasam S. SURESH

Department of Orthopaedics, Ibri Regional Referral Hospital, Sultanate of Oman

We present a case of scapholunate coalition with absent fifth metacarpal on one hand, and scapholunate triquetral coalition on the other hand. The patient was asymptomatic, though he was aware of the deformity of the little and ring fingers on the right hand. No treatment was offered as the deformity was not incapacitating and the syndactyly did not interfere with hand function.

Key words: Carpal coalition; congenital anomaly; hand; simian crease.

Coalition occurs because of failure of segmentation of the cartilaginous precursors of two bones.^[1] Carpal fusion may be complete, partial with a notch, or with a narrowing of the joint space between the carpal bones.^[2] They are usually found incidentally in radiographs performed for unrelated reasons, but may become symptomatic due to fractures, degenerative arthritis, or pain due to soft tissue stretching.^[1-5] Scapholunate coalition (SLC) and scapholunate triquetral coalition (SLTC) are extremely rare.^[6,7]

Case report

A 19-year-old male was seen in the clinic for an assessment of disability for social security benefits. He was found to have deformity of both hands. Both hands were broader than usual; there was syndactyly of the proximal part of the little and ring fingers on the right hand and a flexion deformity of the terminal interphalangeal joint of the index finger. Clinically, the thumbs were found to be hypoplastic. Movements of the wrist and forearm were normal (Fig. 1). The patient was found to have simian crease on both hands (Fig. 2) and absent creases over the

thumbs. Other than the hand deformity, there were no features of any associated syndromes.

Radiographs of the hand showed SLC (Minaar 3) on the right side. In addition to this, the fifth ray was found to be absent and the head of the fourth ray was articulated with the proximal phalanges of the ring and the rudimentary little finger. On the left hand there was fusion of the scapholunate triquetrum (pseudarthrosis, Minaar 1). The ulnar styloid was absent on both sides (Figs. 3 and 4).

Discussion

Coalition occurs because of failure of segmentation of the cartilaginous precursors of two bones.^[1] Carpal fusion may be complete, partial with a notch, or with narrowing of the joint space between the carpal bones.^[2] The most common carpal coalition is lunotriquetral (88.9%), followed by capitohamate (5.6%).^[1-3,5,8]

Various syndromes like Ellis-van Creveld syndrome, symphalangism, arthrogryposis multiplex congenital, Holt-Oram syndrome, and oto-palato-digital syndrome are associated.^[2] Carpal coalition

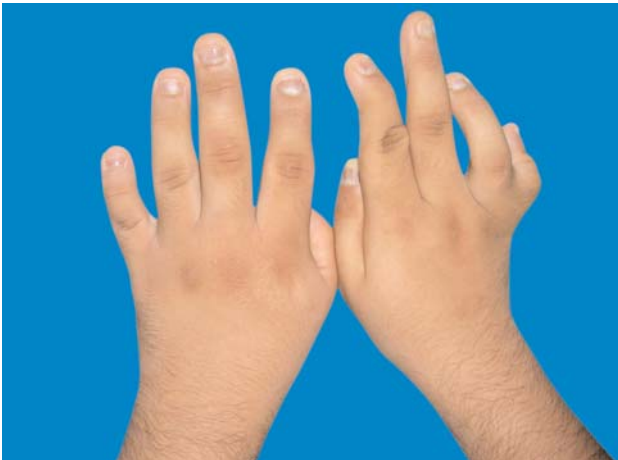

Fig. 1. Dorsal view of the hand, showing the flexion deformity of the index finger on the right hand and syndactyly of the little and ring fingers. [Color figure can be viewed in the online issue, which is available at www.aott.org.tr]

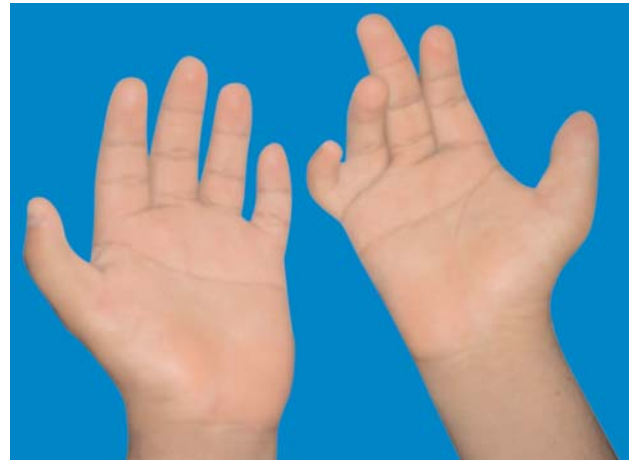


Fig 2. Volar view of the hands, showing the simian crease and absent flexion creases of the thumb. [Color figure can be viewed in the online issue, which is available at www.aott.org.tr]

can occur as part of a generalized syndrome^[9] or as isolated cases detected accidentally. Syndrome-associated carpal coalitions are massive and are usually accompanied by tarsal coalition.^[2] Moreover, isolated carpal fusions involve two bones of the same row, whereas syndrome-associated fusions are usually multiple.^[2]

Lunotriquetral coalition has been classified by Minaar into four types which can be used to classify other coalitions as well.^[6,9] Type 1 is an incomplete fusion resembling a pseudarthrosis, Type 2 is a proximal osseous bridge with a distal notch, Type 3 is a complete fusion of the lunotriquetral, and Type 4 is a complete fusion associated with other carpal

anomalies.^[6] More common are those on the ulnar side or that occupy the same row.^[2] Carpal coalitions have an incidence of 0.1-0.2% in the white population and 8.8% in black Africans.^[4]

Unless syndrome related, carpal coalitions are usually an incidental finding. However, carpal coalitions may become symptomatic. Since there is no possibility of movements of the fused bones, pain may be caused by increased compensatory movements of the adjacent joints and soft tissue.^[1,2] In incomplete coalition, because of the absence of intra-articular cartilage, there is a likelihood of degenerative arthritis due to stress loading.^[3] Occasionally, patients may present with fracture of

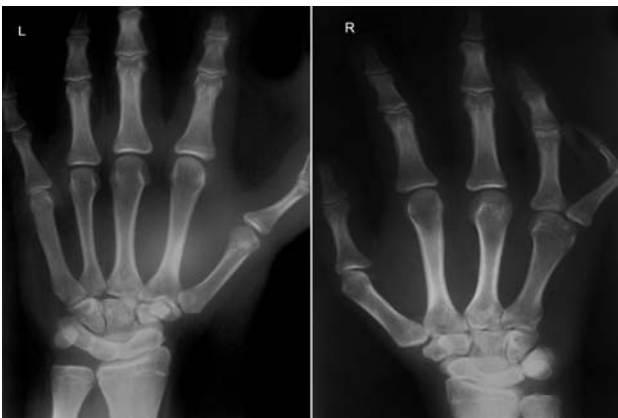

Fig. 3. Posteroanterior radiograph of the hands, showing the SLTC on the left and SLC with absent fifth ray on the right.

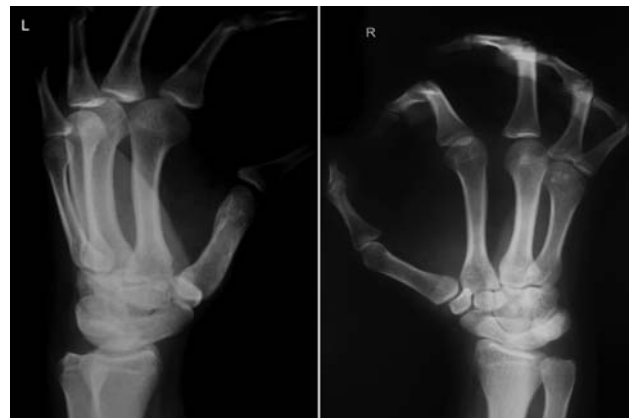

Fig. 4. Oblique view of the wrist showing the coalitions.

the coalition^[3,4] or with wrist pain due to deranged carpal biomechanics.^[1] Patients with pisiform-hamate coalition may present with ulnar neuropathy, in which the ulnar nerve is decompressed by excision of the pisiform.^[5]

Fusion of the SLT has been reported twice before by Knezevich and Gottesman (1990), as quoted by Ingram et al.^[8] and Gómez Robledo,^[6] Ingram et al. reported a rare presentation of coalition of the scaphoid, trapezium, trapezoid, and capitate.^[8]

Sferopoulos and Tsitouridis presented a similar case to ours that described the absence of the fifth metacarpal.^[7] The authors classified ulnar deficient hand into two types; Type 1a – ulnar deficient hand (hand without the fourth and/or fifth ray) with a normal ulna and Type 1b with a hypoplastic ulna.^[7]

In our patient, in addition to the SLC with absent little finger ray and syndactyly of the little and ring finger, there was SLTC on the left side.

Our patient was found to have an absent ulnar styloid on both hands. Gómez Robledo reported a case of SLT fusion with a short fifth metacarpal which was fused with the fourth metacarpal, brachydactyly of the little finger, and absence of the ulnar styloid.^[6] Absence of the fifth metacarpal with SL coalition (right) and the presence of SLT coalition on the other side (left) made our case exceptional, though similar in pattern to that of Gómez Robledo.^[6]

In conclusion, we present a patient with an unusual, nonsyndromic coalition of the carpal bones with simian crease, which has not been previously reported.

Conflicts of Interest: No conflicts declared.

References

1. Boya H, Özcan Ö, Araç Ş, Tandoğan R. Incomplete scapholunate and trapeziotrapezoid coalitions with an accessory carpal bone. *J Orthop Sci* 2005;10:99-102.
2. Singh P, Tuli A, Choudhry R, Mangal A. Intercarpal fusion - A review. *J Anat Soc India* 2003;52:183-8.
3. Laurencin CT, Cummings RS, Jones TR, Martin L. Fracture-dislocation of the lunotriquetral coalition. *J Natl Med Assoc* 1998;90:779-81.
4. Nooman M, Mehdizade A, Carron P, Bianchi S. Quiz case of the month. Bilateral fracture of the luno-triquetral coalition associated with Colles fracture. *European Radiol* 2002;12:1594-6.
5. Silverman AT, Shin SS, Paksima N. Asymptomatic pisiform-hamate coalition: A case report. *Am J Orthop (Belle Mead NJ)* 2007;36:E88-90.
6. Gómez Robledo J. An unusual carpal coalition associated with fifth ray anomalies in the hand. *J Hand Surg Br* 1998; 23:537-8.
7. Sferopoulos NK, Tsitouridis I. Carpal coalition: a rare coincidence of hand deficiencies. *Acta Orthop Belg* 2003; 69:317-20.
8. Ingram C, Hall RF, Gonzalez M. Congenital fusion of the scaphoid, trapezium, trapezoid and capitate. *J Hand Surg Br* 1997;22:167-8.
9. Carlson DH. Coalition of the carpal bones. *Skeletal Radiol* 1981;7:125-7.