



## The effect of excisional arthroplasty with palmaris longus tendon on carpal height ratio in Stage 3 Kienböck's disease

Levent KÜÇÜK, Oğuz ÖZDEMİR, Erhan COŞKUNOL, Tahir S. SÜĞÜN, Kemal ÖZAKSAR

*Department of Orthopedics and Traumatology, Faculty of Medicine, Ege University, İzmir, Turkey*

**Objective:** Treatment methods in Kienböck's disease remain controversial despite the long-term awareness of the disease by orthopedic surgeons. Currently, excisional arthroplasty with a palmaris longus tendon ball is one of the most frequently used treatment methods. The aim of this study was to evaluate the long-term results of thirty-eight patients who had been treated with excisional arthroplasty and palmaris longus tendon ball, as well as the effect of this method on carpal height.

**Methods:** In this study, we retrospectively evaluated 38 patients (mean age: 30.4 years; range: 17-64 years) with Stage 3 Kienböck's disease who underwent excisional arthroplasty between 1978 and 2008. According to the Lichtman classification, 8 patients were classified as Stage 3a and 30 patients were classified as Stage 3b in Kienböck's disease. The mean duration of follow-up after surgery was 81.3 (range: 25 to 264) months. The outcomes were evaluated with joint range of motion, grip strength and functional assessment of Nakamura and radiographic changes in carpal height.

**Results:** According to the Nakamura's scoring system the results were excellent in 22 (57.9%) patients, good in 13 (34.2%) and moderate in 3 (7.9%). Comparison of pre- and postoperative range of motion of the wrist revealed an average increase in wrist extension of 10° (p<0.05), and an average decrease in ulnar deviation of 4° (p<0.05) after the operation. No significant difference was observed when comparing other joint range of motion parameters. Dynamometric grip strength measurements revealed significant differences between the healthy and operated sides (67.6 kgf vs. 45.9 kgf, respectively; p<0.05). The decrease in the revised carpal height ratio were significant.

**Conclusion:** According to patient satisfaction rate and clinical results, the outcome of excisional arthroplasty with palmaris longus tendon ball in Stage 3 Kienböck's disease is satisfactory. However, carpal height reduction and development of degenerative changes may be expected in long-term follow-up.

**Key words:** Carpal height; excisional arthroplasty; Kienböck's disease.

Despite its original description over a century ago, the etiopathology and treatment methods for Kienböck's disease remain controversial. Robert Kienböck reported the cause to be a previous wrist trauma, where the ligaments of the wrist joint and adjoining blood vessels are damaged, leading to a disruption of the blood sup-

ply to the lunate, and subsequent avascular necrosis.<sup>[1,2]</sup> Other mechanical factors considered to cause excessive load on the lunate have since been blamed as well.<sup>[3,4]</sup> Some researchers have emphasized that disturbances in the arterial and venous system are predominant factors involved in the etiology of the disease.<sup>[5,6]</sup>

**Correspondence:** Levent Küçük, MD. Ege Üniversitesi Tıp Fakültesi, Ortopedi ve Travmatoloji Anabilim Dalı, Bornova, İzmir, Turkey.  
Tel: +90 505 - 525 02 77 e-mail: kucuklevent@yahoo.com

**Submitted:** October 26, 2010 **Accepted:** August 12, 2011

©2011 Turkish Association of Orthopaedics and Traumatology

Treatment options include conservative management with prolonged cast immobilization, vascularized bone grafting for revascularization of the lunate, radial shortening or ulnar lengthening, partial capitate shortening, autologous tendon grafting following excision of the lunate, implant arthroplasty, limited intercarpal arthrodesis, and salvage procedures for the wrist.<sup>[7-18]</sup> The application of these methods by different researchers to insufficient numbers of patients at different stages of the disease and the lack of comparison of treatment outcomes form the basis of the controversy over the appropriate treatment method.

Various types of autologous tendon grafts have been utilized as tendon balls to fill the resultant space following excision of the lunate in Stage 3 Kienböck's disease. The most commonly used tendon for grafting is the palmaris longus, although the use of the plantaris tendon or a bone core to create the tendon ball has also been reported. However, as the use of the tendon ball alone has not been shown to be sufficient in maintaining carpal height; some studies have supplemented grafts with a temporary external fixator or intercarpal, radiocarpal Kirschner wire.<sup>[11-13]</sup>

In the present study, we evaluated the long-term outcomes of patients with Stage 3 Kienböck's disease who underwent excision of the lunate followed by autologous palmaris longus tendon grafting and Kirschner wire fixation. Also evaluated was the ability of the procedure to maintain carpal height.

## Patients and methods

We retrospectively evaluated patients who underwent lunate excision and space-filling with palmaris longus tendon ball following the diagnosis of Stage 3 Kienböck's disease between 1978 and 2008. Included in the study were 38 patients (mean age: 30.4 years; range: 17-64 years) who attended the final follow-up and whose preoperative radiographs and clinical evaluations were available.

Eleven (28.9%) of the patients were male and 27 (71.1%) were female. Mean age was 30.4 (range: 17 to 64) years. Nine (23.7%) patients had involvement of the left wrist and 29 (76.3%) of the right wrist. Twenty-nine (76.3%) patients had a history of wrist trauma.

The average time elapsed from the onset of complaints to the initiation of treatment was 27.2 (range:

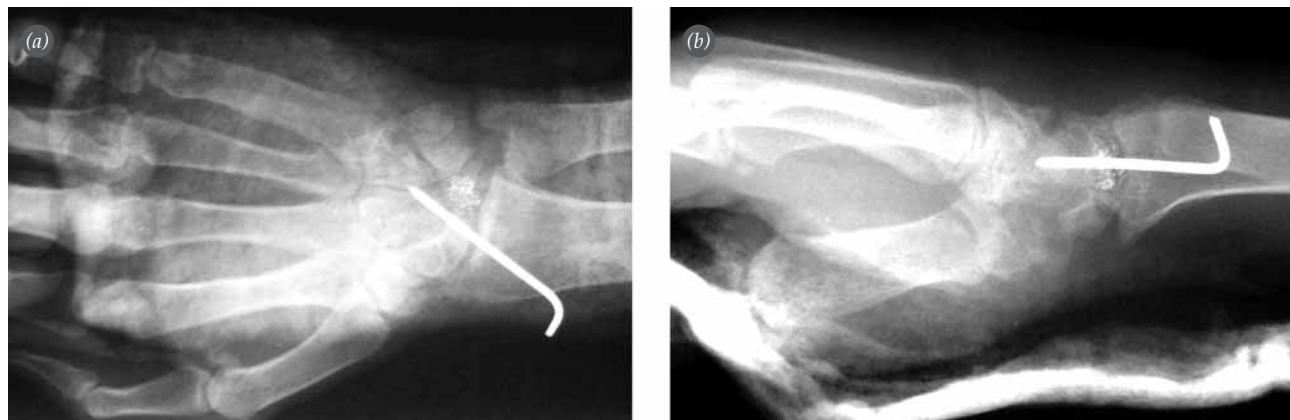
3 to 66) months. According to the Lichtman classification,<sup>[10]</sup> 8 patients were classified as having Stage 3a and 30 patients were classified as having Stage 3b Kienböck's disease. The mean duration of follow-up after surgery was 81.3 (range: 25 to 264) months.

The fourth extensor compartment was opened using a dorsal approach. The posterior interosseous nerve was dissected and a neurectomy was performed. The wrist capsule was opened and the lunate was then excised. Special care was given to avoid any damage to the palmar capsule of the wrist during excision. A palmaris longus tendon graft was taken from the palmar side, using multiple small transverse incisions and was rolled onto itself to form a tendon ball. The wire suture technique described by Çallı et al.<sup>[19]</sup> was used while preparing the tendon ball to allow for radiological follow-up. After placing the tendon ball into the excised space, radiocarpal fixation was performed using a single Kirschner wire (Figs. 1 and 2). Physiotherapy was initiated after six weeks of fixation.

In the clinical evaluation, joint range of motion was assessed using goniometric measurements, grip strength was evaluated with a dynamometer, and functional outcomes were assessed using the system developed by Nakamura et al.<sup>[20,21]</sup> The carpal height ratio (the ratio of the distance between the distal articular surface of the capitate and the distal articular surface of the radius to the length of the third metacarpal on a posterior-anterior radiograph) and revised carpal height ratio (the ratio of the distance between the distal articular surface of the capitate and distal articular surface of the radius to the longest axis length of the

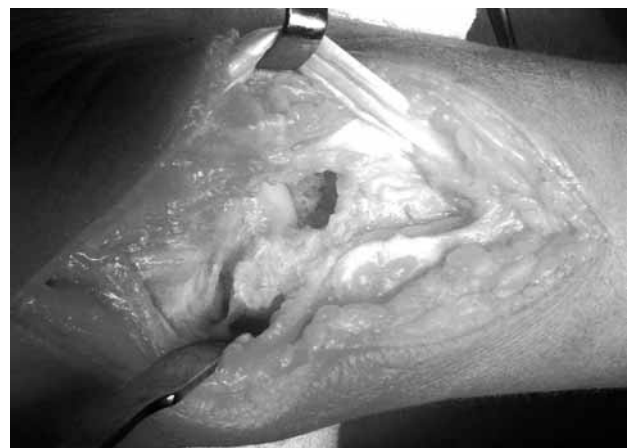

Fig. 1. Operative image after excision of the lunate bone.



**Fig. 2.** Postoperative (a) anteroposterior and (b) lateral radiographs.

capitate on a posterior-anterior radiograph) were compared using pre- and postoperative radiographs.<sup>[22,23]</sup>

Statistical analysis was carried out using the SPSS v13.0 (SPSS Inc., Chicago, IL, USA) software. In pre- and postoperative comparisons, a t-test was used to compare the healthy and affected sides. A p value less than 0.05 was considered statistically significant.

**Results**

The patients included in this study were followed for a minimum of 2 and a maximum of 22 years. According to the Nakamura's scoring system for Kienböck's disease, the results were excellent in 22 (57.9%) patients, good in 13 (34.2%) and moderate in 3 (7.9%).

Comparison of pre- and postoperative range of motion of the wrist revealed an average increase in wrist extension of 10° (p<0.05), and an average decrease in ulnar deviation of 4° (p<0.05) after the operation. No significant difference was observed when comparing other joint range of motion parameters (Table 1).

Dynamometric grip strength measurements revealed significant differences between the healthy and operated sides (67.6 kgf vs. 45.9 kgf respectively; p<0.05).

Although we determined decreases in both carpal height and revised carpal height ratios after the operation, only the decrease in the revised carpal height ratio were significant (Table 1) (Figs. 3 and 4).

In five patients, subluxation of the tendon ball to the dorsal aspect of the wrist was radiographically detected by means of the wire suture placed around the tendon. These patients had no significant complaints and did not require additional surgery. At the end of the follow-up period, degenerative joint changes were observed in all patients.

Subjective queries revealed that patients were satisfied with the surgical intervention and that the majority of the patients were able to return to work.

**Discussion**

In advanced stage Kienböck's disease, interposition of a palmaris longus tendon ball to the created defect

**Table 1.** Comparison of pre- and postoperative range of motion of the wrist and the carpal height ratios.

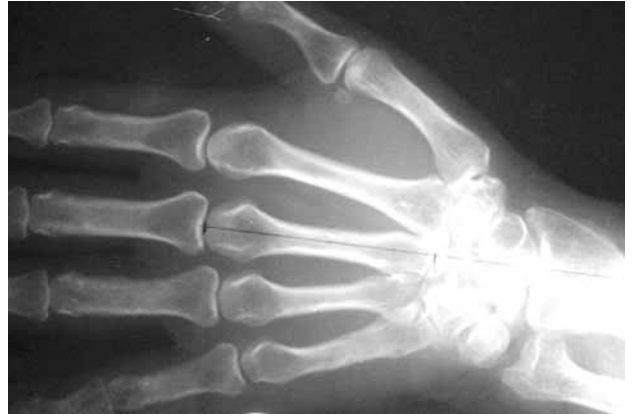	Preoperative (±SD)	Post-operative (±SD)	p value
Revised carpal height ratio	1.39 (±0.11)	1.35 (±0.07)	<b>0.022</b>
Carpal height ratio	0.48 (±0.05)	0.47 (±0.04)	0.196
Flexion	31.57 (±13.72)	32.36 (±9.13)	0.664
Extension	34.86 (±10.66)	44.47 (±10.18)	<b>0.000</b>
Radial deviation	10.52 (±5.35)	10.65 (±4.95)	0.864
Ulnar deviation	21.84 (±6.53)	18.55 (±6.14)	<b>0.002</b>

Significant p values are typed in bold.

following lunate excision is a reconstruction method which aims to prevent future synovitis and degeneration. This interposition may prevent proximal migration of the capitate, and thus the deterioration of wrist dynamics.<sup>[24,25]</sup>

Other methods to maintain carpal height include temporary intercarpal fixation and distraction methods. Yajima et al.<sup>[12]</sup> performed temporary fixation of the scaphotrapezio-trapezoidal or scaphocapitate joint with Kirschner wires, following excision of the lunate and interposition of the tendon ball. They reported that temporary fixation for a minimum of six weeks in the postoperative period was efficient in maintaining carpal height. Ueba et al.<sup>[13]</sup> applied external fixation distraction following excision and tendon grafting and reported successful results.

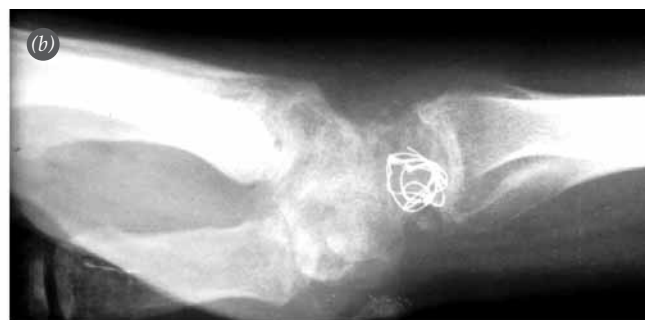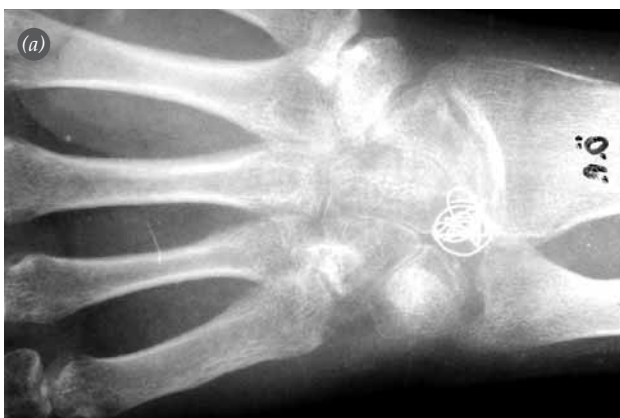The failure to maintain carpal height following lunate excision, and the development of arthrosis as a result of carpal collapse are the major criticisms related to this surgical method. Sakai et al.<sup>[11]</sup> applied lunate excision in two groups of patients. The first group was treated with replacement of the lunate with a palmaris longus tendon graft with a bone core placed in the tendon ball and the second group was treated with replacement of the lunate with a palmaris longus tendon graft without a bone core. The authors emphasized that at the end of the first postoperative year, the tendon ball with the bone core maintained carpal height while carpal height was significantly decreased and the rate of arthrosis development was significantly higher in the non-bone core group. However, there was no significant difference between the two groups with respect to the clinical outcomes despite the presence of carpal collapse.



**Fig. 3.** Preoperative anteroposterior radiograph of a Stage 3a patient and drawings to determine the carpal height ratio.

Carpal height ratio calculations and their reliability have been reported by different authors in the literature.<sup>[22,23]</sup> The carpal height ratio, as defined by Youm, is the ratio of the carpal height to the length of the third metacarpal.<sup>[22]</sup> However, Natrass et al.<sup>[23]</sup> reported that the use of the length of the capitate length and not the third metacarpal provided more accurate and precise results. The authors defined this new method of calculation as the revised carpal height ratio and reported that its average value in the normal population was  $1.57 \pm 0.05$ .

In addition to using a palmaris longus tendon ball, we used a Kirschner wire for fixation of the wrist joint for a period of six weeks following the surgery to prevent carpal collapse. However, despite this application and results from previous studies, follow-up evaluations showed significantly decreased carpal height ratio and carpal collapse. We are of the opin-



**Fig. 4.** The same patient's long-term follow-up (a) anteroposterior and (b) lateral radiographs.

ion that the use of a tendon graft to fill the excised space has only a limited ability to prevent proximal capitate migration and maintain carpal height.

Kato et al.<sup>[26]</sup> reported good clinical results in 13 patients with advanced stage (Stages 3 and 4) Kienböck's disease who were followed-up for an average period of 6 years. However, they reported that this method failed to prevent carpal collapse. Carroll reported that at an average of 17.9-year follow-up in 43 patients, outcomes were efficient and all patients were able to proceed with their preoperative activity and working life without problems.<sup>[27]</sup>

In our study on 38 patients with an average follow-up period of 81.3 months, no significant difference was observed between pre- and postoperative flexion and radial deviation range of motion values. However, extension and ulnar deviation range of motion values significantly differed between the pre- and postoperative periods. On clinical evaluation, it was noted that the majority of patients were satisfied with the surgical procedure; they had no significant pain complaints, and they returned to their preoperative activity levels. That 92.1% of the patients had excellent and good clinical outcomes according to the Nakamura's scoring system is remarkable. However, the lack of tools that display patients' subjective state, such as the Disabilities of the Arm, Shoulder and Hand (DASH) questionnaire or visual analogue scale (VAS) is a limitation of the present study.

In accordance with the literature, we found that there was a decrease in postoperative carpal height ratios. Our finding that only the decrease in the revised carpal height ratio reached a significant level suggests that, in agreement with the literature, revised carpal height ratio is more sensitive than carpal height ratio in determining carpal collapse.

Wrist denervation procedures are among the salvage procedures performed in patients with advanced stage Kienböck's disease. Posterior interosseous neurectomy was performed in our patients through the same incision. We are of the opinion that this neurectomy procedure was a strong factor in the high satisfaction rates and minimal pain complaints despite the presence of symptoms of advanced arthrosis. However, neurectomy's effect on the degenerative changes noted on the follow-up radiographs is open to discussion.

The use of a wire in the preparation of the tendon ball during surgery was helpful in determining complications during the follow-up period. In five patients, subluxation of the tendon graft to the dorsal side of the wrist was radiographically detected by means of the wire sutures used. As these patients had no clinical symptoms and complaints, they were simply monitored. As there is no technical difficulty in the use of wire sutures while preparing the tendon ball and their use does not prolong the duration of surgery or increase cost, we believe that this is a useful method to monitor complications.

In conclusion, lunate excision followed by palmaris longus tendon ball replacement in advanced stage Kienböck's disease produces satisfactory patient satisfaction rates and clinical outcomes. However, when choosing this method, it should be kept in mind that the carpal height ratio may be decreased and degenerative changes may occur.

**Conflicts of Interest:** No conflicts declared.

## References

- Alexander AH, Lichtman DM. Kienböck's disease. *Orthop Clin North Am* 1986;17:461-72.
- Lichtman DM, Alexander AH, Mack GR, Gunther SF. Kienböck's disease: update on silicone replacement arthroplasty. *J Hand Surg Am* 1982;7:343-7.
- Masear VR, Zook EG, Pichora DR, Krishnamurthy M, Russell RC, Lemons J, et al. Strain-gauge evaluation of lunate unloading procedures. *J Hand Surg Am* 1992;17:437-43.
- Garcia-Elias M, An KN, Cooney WP, Linscheid RL. Lateral closing wedge osteotomy for treatment of Kienböck's disease. A clinical and biomechanical study of the optimum correcting angle. *Chir Main* 1998;17:283-90.
- Pichler M, Putz R. The venous drainage of the lunate bone. *Surg Radiol Anat* 2003;24:372-6.
- Jensen CH. Intraosseous pressure in Kienböck's disease. *J Hand Surg Am* 1993;18:355-9.
- Keith PP, Nuttall D, Trail I. Long-term outcome of non-surgically managed Kienböck's disease. *J Hand Surg Am* 2004;29:63-7.
- Luo J, Diao E. Kienböck's disease: an approach to treatment. *Hand Clin* 2006;22:465-73.
- Simmons SP, Tobias B, Lichtman DM. Lunate revascularization with artery implantation and bone grafting. *J Hand Surg Am* 2009;34:155-60.
- Lichtman DM, Lesley NE, Simmons SP. The classification and treatment of Kienböck's disease: the state of the art and a look at the future. *J Hand Surg Eur* 2010;35:549-54.
- Sakai A, Toba N, Oshige T, Menuki K, Hirasawa H, Nakamura T. Kienböck disease treated by excisional arthroplasty with a palmaris longus tendon ball: a compar-

- ative study of cases with or without bone core. *Hand Surg* 2004;9:145-9.
12. Yajima H, Kobata Y, Yamauchi T, Takakura Y. Advanced Kienböck's disease treated with implantation of a tendon roll and temporary partial fixation of the wrist. *Scand J Plast Reconstr Surg Hand Surg* 2004;38:340-6.
  13. Ueba Y, Nosaka K, Seto Y, Ikeda N, Nakamura T. An operative procedure for advanced Kienböck's disease. Excision of the lunate and subsequent replacement with a tendon-ball implant. *J Orthop Sci* 1999;4:207-15.
  14. Salmon J, Stanley JK, Trail IA. Kienböck's disease. Conservative management versus radial shortening. *J Bone Joint Surg Br* 2000;82:820-3.
  15. Schuind F, Eslami S, Ledoux P. Aspects of current management. Kienböck's disease. *J Bone Joint Surg Br* 2008;90:133-9.
  16. Gunal I, Ozcan O, Uyulgan B, Baran O, Arman C, Karatosun V. Biomechanical analysis of load transmission characteristics of limited carpal fusions used to treat Kienböck's disease. *Acta Orthop Traumatol Turc* 2005;39:351-5.
  17. Rodop O, Kiral A, Akmaz I, Arpacioğlu MO. Scaphotrapezotrapezoid arthrodesis in the treatment of advanced-stage Kienböck's disease. [Article in Turkish] *Acta Orthop Traumatol Turc* 2001;35:329-35.
  18. Kayalar M, Ada S, Bora A, Ozerkan F, Kaplan I, Ademoglu Y. The results of surgical treatment in Kienböck's disease. [Article in Turkish] *Acta Orthop Traumatol Turc* 1999;33:51-7.
  19. Çallı İH, Özdemir O, Coşkunol E, Özcan MZ. Kienböck hastalığında palmaris longus tendon grefti ile replasman artroplastisi ve interkarpal artrodez. *İzmir Devlet Hastanesi Tıp Dergisi* 1995;3:389-92.
  20. Nakamura R, Tsuge S, Watanabe K, Tsunoda K. Radial wedge osteotomy for Kienböck disease. *J Bone Joint Surg Am* 1991;73:1391-6.
  21. Nakamura R, Imaeda T, Miura T. Radial shortening for Kienböck's disease: factors affecting the operative result. *J Hand Surg Br* 1990;15:40-5.
  22. Youm Y, McMurtry RY, Flatt AE, Gillespie TE. Kinematics of the wrist. I. An experimental study of radial-ulnar deviation and flexion extension. *J Bone Joint Surg Am* 1978;60:423-31.
  23. Nattrass GR, King GJW, McMurtry RY, Brant RF. An alternative method for determination of the carpal height ratio. *J Bone Joint Surg Am* 1994;76:88-94.
  24. Kawai H, Yamamoto K, Yamamoto T, Tada K, Kaga K. Excision of the lunate in Kienböck's disease. Results after long-term follow-up. *J Bone Joint Surg Br* 1988;70:287-92.
  25. Wheatley MJ, Finical SJ. A 32-year follow-up of lunate excision for Kienböck's disease: a case report and a review of results from excision and other treatment methods. *Ann Plast Surg* 1996;37:322-5.
  26. Kato H, Usui M, Minami A. Long-term results of Kienböck's disease treated by excisional arthroplasty with a silicone implant or coiled palmaris longus tendon. *J Hand Surg Am* 1986;11:645-53.
  27. Carroll RE. Long-term review of fascial replacement after excision of the carpal lunate bone. *Clin Orthop Relat Res* 1997;(342):59-63.