



## An effective treatment for hip instabilities: pelvic support osteotomy and femoral lengthening

Sarper GÜRSU, Bilal DEMİR, Timur YILDIRIM, Turgay ER, Ayşegül BURSALI, Vedat ŞAHİN

*Department of Orthopaedics and Traumatology, Baltalimanı Bone Diseases Training and Research Hospital, İstanbul, Turkey*

**Objective:** In this study, we evaluated the effectiveness of pelvic support osteotomy treatment in hip instabilities due to various etiologies.

**Methods:** We retrospectively evaluated 21 hips of 20 patients that underwent pelvic support osteotomy between 2005 and 2007. Hip instability was caused by a neglected congenital dislocation of the hip in 12 of the patients (13 hips), by septic arthritis in 7 and by an unsuccessful total hip arthroplasty due to infection in the last patient. The mean age of the patients was 22.6 (range: 12 to 34) years. Osteotomy sites were fixed using monolateral external fixators in 11 patients, Ilizarov circular fixators in 8, and locking plates for both hips of the remaining patient. The mean follow-up period was 33.45 (range: 16 to 45) months.

**Results:** The mean Harris score increased from 48.3 preoperatively to 80.1 postoperatively. Preoperative mean limb length discrepancy was 53.3 mm and mean proximal migration was 42.9 mm. Residual limb length discrepancy was reduced to 16 mm after an average lengthening of 63.3. The preoperative Trendelenburg gait disappeared completely in 13 of 21 hips and was improved in 8 hips. Sixteen of the 20 patients (17 hips) expressed satisfaction with the operation.

**Conclusion:** Pelvic support osteotomy is a good treatment option to overcome hip instability as it improves pain and equalizes limb length.

**Key words:** Hip instability; lengthening; osteotomy; pelvic support.

Hip instability occurring due to neglected congenital dysplasia of the hip (CDH) or septic diseases of the hip is an important concern for orthopedic surgeons. Various treatment options are described in the literature for both situations. Total hip arthroplasty for young adults with neglected CDH<sup>[1,2]</sup> and arthroplasty, arthrodesis or resection arthroplasty for patients with either sequelae of septic arthritis or failure of infected hip prosthesis<sup>[3,4]</sup> are suggested treatment methods.

The history of pelvic support osteotomy goes back many years. Bouvier in 1838 described the technique of proximal femoral osteotomy for CDH. Kirmisson<sup>[5]</sup> and Froelich and Bayer<sup>[6]</sup> developed new

methods similar to pelvic support osteotomy. The most important contributions to the technique were made by Lorenz,<sup>[7,8]</sup> Schanz,<sup>[9]</sup> Hass<sup>[10]</sup> and Milch.<sup>[11]</sup> In this study, we evaluated the results of Ilizarov's<sup>[12]</sup> pelvic support osteotomy technique in patients with hip instability due to various factors.

### Patients and methods

Pelvic support osteotomy and femoral lengthening were performed on 21 hips of 20 patients with hip instability due to various factors between March 2005 and May 2007. Seven patients were male and 13 were female. Patients' mean age was 22.6 (range:

12 to 34) years. Support osteotomy was performed for the right hip of 10 patients, for the left hip of 9 patients and for both hips of one patient with bilateral CDH. Mean follow-up period was 33.45 (range: 16 to 45) months. Written and informed patient consent was obtained and the study was approved by the institution's ethics committee.

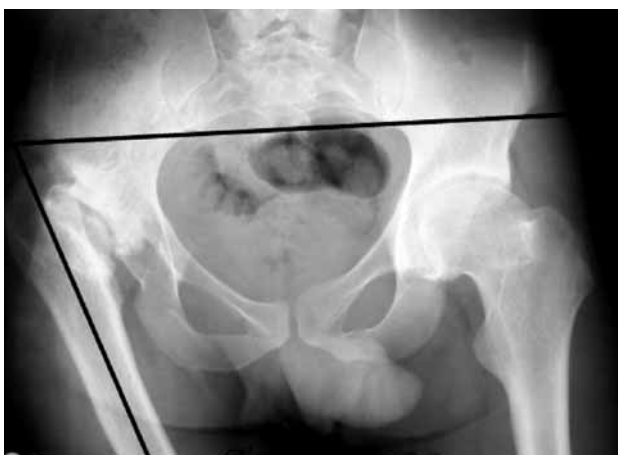The etiological factor was neglected CDH in 12 of the patients (13 hips), septic arthritis in 7 patients, and the extraction of total hip prosthesis due to antibiotherapy-resistant infection in the remaining patient. Ten patients had a history of previous surgical procedures. Two patients had undergone previous Schanz osteotomy, 1 total hip arthroplasty, 3 joint debridements because of septic arthritis and 4 various other procedures due to CDH.

Mean range of motion values of the knee and hip were recorded. Functional evaluation was made using the Harris Hip Scoring System.<sup>[13]</sup> Scoring was made by a surgeon who was not involved in the surgical procedure.

All patients, except that with bilateral CDH, experienced limping. The Trendelenburg sign was positive for all patients.

An anteroposterior (AP) radiograph of the pelvis including the iliac crests, an orthoroentgenogram of the lower limbs, a pelvis AP radiograph with the unstable leg in maximum adduction in front of the stable hip (Fig. 1), and a pelvis radiograph with the patient standing on his unstable leg were taken pre-operatively.

AP pelvis X-rays were used to determine etiological factors and measure the proximal migration of



**Fig 1.** Pelvis AP X-ray with unstable hip in maximum adduction.

the trochanter major. The orthoroentgenograms were used to diagnose limb length discrepancy. The standing radiograph was used to measure the angle between the adducted femur's anatomical axis and either a line connecting the upper ends of the iliac crest or a line connecting the lower ends of the sacroiliac joints. A valgus angulation with a similar angle plus a 15 degree overcorrection was made. In order to detect the level of the osteotomy site, radiographs with the unstable hip in maximum adduction were used. The point where the adducted femur crossed the tuber ischii was accepted as the level of osteotomy. The distal osteotomy was made at a level between the proximal osteotomy site and the knee joint line. Templates simulating the lower extremity were prepared; and after accomplishing the proposed degree of valgus at the proximal osteotomy site on the templates, the amount of varization at the distal osteotomy site required to correct the mechanical axis of the extremity was calculated.

Patients received general or regional anesthesia depending on the anesthesia specialist's choice. All osteotomies were made under fluoroscopy control, using osteotomes, after drilling the osteotomy site. Proximal osteotomy at the level of the tuber ischii was made first. The distal osteotomy was made at a level in between the proximal osteotomy site and the knee joint line. At the proximal osteotomy site, the pre-calculated valgus angulation was made and the varization required to correct the mechanical axis of the lower extremity was formed acutely at the distal osteotomy site. For patients with a contracture of the hip, extension was made at the proximal osteotomy site to overcome correction. In order to achieve the intended amount of extension, the plane of the Schanz screws in the proximal fragment were tilted anteriorly in the sagittal plane as much as the amount of the hip contracture, with the most proximal Schanz screw being placed more anteriorly than the distal screw. In the only patient with bilateral CDH and no limb length discrepancy, fixation of the osteotomy sites was made using angulated, locking, low contact dynamic compression plates (LC-DCP, Synthes, Famed, Ankara) (Fig. 2). In 11 of 19 patients for whom lengthening was indicated, mono-lateral external fixators (LRS, Tasarimmed, Istanbul) (Fig. 3) were used and in the other 8 patients Ilizarov type circular external fixators (Hipokrat, Istanbul) were used.

Mobilization using crutches was begun 2 days postoperatively. Patients with fixators were allowed weight-bearing as tolerated. The patient with plates was not allowed weight-bearing. All range of motion exercises for the hip and the knee were begun in all patients.

Antibiotics were used only in patients with pin site infection. Pin site infections were evaluated according to Paley's infection classification.<sup>[14]</sup>

Lengthening was initiated on the 7th postoperative day at a rate of 0.25 mm, 4 times daily. Amount of lengthening was decided according to orthoroentgenograms taken during the follow-ups (Fig. 4).

Fixators were removed only when three cortices could be seen on simultaneous radiographs and consolidation was thought to be sufficient. Extraction procedures were performed in the outpatient clinics or in the operating rooms under general anesthesia depending on the patient's condition.

Data obtained in the study was analyzed using SPSS 16.0 (SPSS Inc., IL, USA) system and the

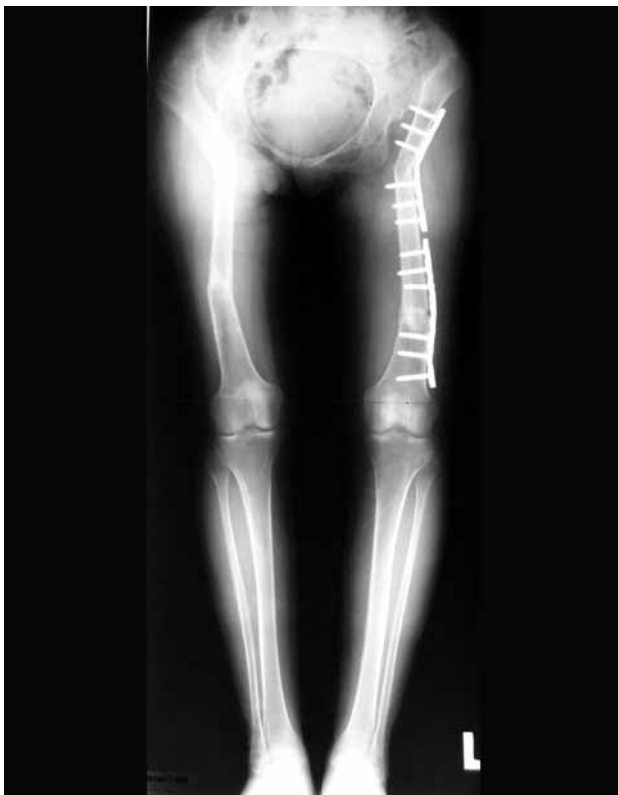increase in the Harris hip scores was evaluated with Wilcoxon test. P values less than 0.05 was considered significant.

## Results

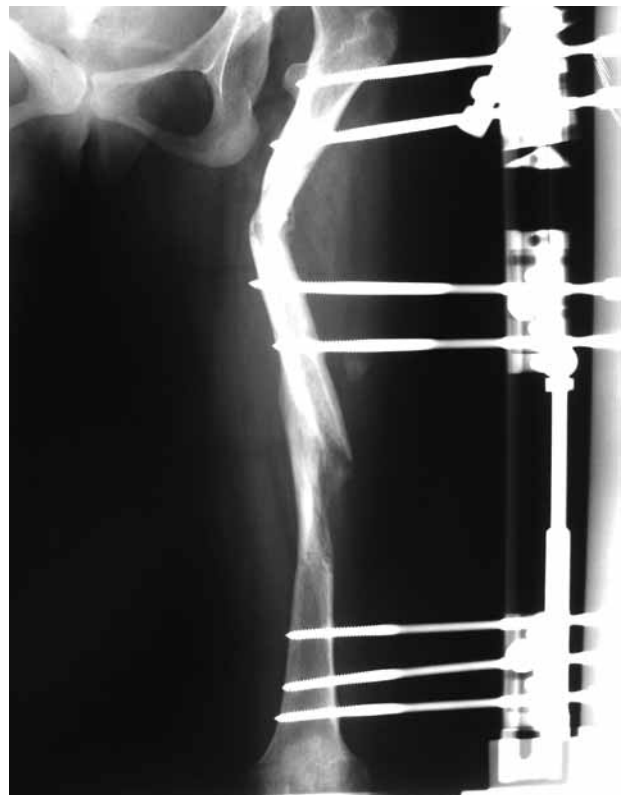The mean Harris hip score in the final follow-up was 80.1 (range: 60 to 93), whilst it was 48.3 (range: 28 to 79) prior to surgical treatment (Table 1). The increase in the Harris Hip Score was statistically significant ( $p < 0.05$ ).

All patients except the two youngest (12 and 16 years old) suffered from pain pre-treatment, and following treatment, only 6 patients still experienced pain to some extent. Before the osteotomies, all patients had positive Trendelenburg sign but following treatment the Trendelenburg sign was lost completely in 13 hips of 12 patients (Fig. 5) and partially in the remaining patients.

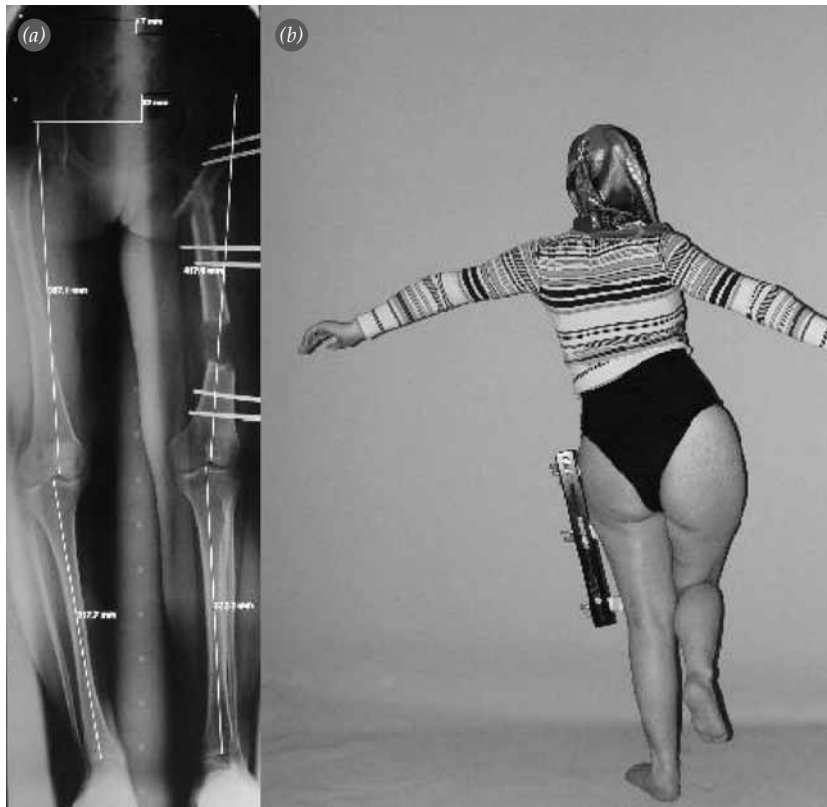
Mean external fixation period for all 19 patients who received external fixators was 362.2 (range: 147 to 623) days. It was a mean of 415.4 (range: 270 to 623) days for patients with monolateral external



**Fig 2.** Final orthoroentgenogram of the patient with no limb length discrepancy. Lengthening was not made and the osteotomy sites were fixed using locking plates.



**Fig 3.** Pelvic support osteotomy using monolateral external fixator in a patient with hip instability due to congenital dysplasia of the hip.



**Fig 4.** (a) Orthoroentgenogram and (b) photo of a patient whose Trendelenburg sign was lost after lengthening.

fixators and 278.5 (range: 147 to 429) days for patients with circular external fixators.

The mean preoperative knee range of motion of the knee decreased from 127.7 (range: 100 to 150) degrees to 121.6 (range: 90 to 150) degrees postoperatively. Range of hip flexion decreased to 95 (range: 80 to 130) degrees in the last follow-up from a mean preoperative value of 104.4 (range: 80 to 130) degrees. The decreases in both the range of hip and knee flexion were significant ( $p < 0.05$ ). Mean flexion contracture, which was 10 (range: 0-20) degrees preoperatively, decreased to a mean of 4 (range: 0-10) degrees postoperatively. The 2 patients who were unable to walk without crutches before surgical intervention were able to walk without support following the pelvic support osteotomy.

Though all patients, with the exception of the patient with bilateral CDH, had limping with varying severity preoperatively, only 3 experienced mild limping post-treatment. Two of these three patients had a fracture at the proximal osteotomy site and one had insufficient lengthening upon the patient's will.

Sixteen patients (17 hips) expressed satisfaction with their treatment results when questioned and would recommend this procedure to similar patients.

Four patients (4 hips) thought the operation was not sufficient enough to improve their situation.

Lengthening with external fixators was done in 19 patients. Prior to lengthening the mean limb length discrepancy was 53.3 (range: 13 to 110) mm and mean proximal migration was 42.9 mm. Mean lengthening was 63.3 (range: 34 to 110) mm. In the last follow-up mean limb length discrepancy was 16 mm. In one of the 2 patients with the greatest limb length discrepancy, lengthening was terminated early upon the patient's request. The length discrepancy in the second patient, who was 12 years old, was not present upon removal of the fixator and developed during growing. In the latter, the proximal valgus angulation was measured at 20 degrees in the early postoperative radiographs but decreased to 14 degrees at the end of 3 years.

The femoral head had previously been resected in one patient. In another patient, it had to be resected on the 26th postoperative week due to persisting pain. In 7 patients, the femoral head was totally destroyed as a result of previous septic arthritis.

Osteomyelitis was not seen but pin tract infection with varying severity was present in all patients with external fixators (Table 2). Paley Grade 1 pin tract

**Table 1.** Demographics and results of patients.

	Age	F/M	Side	Imp	HBS	HAS	Et	PxV	DsV
1	24	M	R	MLF	41	77	CDH	50	24
2	20	F	L	MLF	79	93	CDH	30	13
3	22	F	R	MLF	51	86	CDH	52	27
4	21	F	R	MLF	45	80	CDH	43	28
5	18	F	L	MLF	44	87	CDH	40	15
6	16	M	L	ILI	73	92	SA	25	10
7	23	M	R	ILI	53	81	SA	50	16
8	34	M	R	ILI	49	76	IA	38	32
9	20	F	R	MLF	35	62	CDH	43	21
10	18	F	L	ILI	48	82	CDH	24	22
11	31	F	L	ILI	43	83	CDH	38	12
12	20	F	R-L	LP/LP	45	76	CDH	42/29	22/8
13	34	F	L	MLF	51	79	CDH	55	34
14	23	F	L	MLF	29	89	CDH	39	22
15	20	F	R	MLF	48	81	CDH	42	17
16	24	F	L	ILI	41	89	SA	38	12
17	21	M	R	MLF	28	60	SA	34	20
18	26	M	R	MLF	51	82	SA	37	32
19	25	F	R	ILI	56	74	SA	35	17
20	12	M	L	ILI	54	73	SA	20	0

F: Female, M: Male, Imp: Implant used, HBS: Harris score before surgery, HAS: Harris score after surgery, Et: Etiology, PxV: Proximal valgus angulation, DsV: Distal varus angulation, CDH: Congenital dysplasia of the hip, SA: Septic arthritis, IA: Infected arthroplasty, MLF: Monolateral fixator, ILI: Ilizarov fixator, LP: Locked plate

infection was seen in 7 patients and Paley Grade 2 in 8 patients. All patients were successfully treated with antibiotics and a decrease in the speed of lengthening.

Fracture at the proximal osteotomy site was seen in 2 patients after a mean of 6.5 (range: 1 to 12) months following external fixator removal (Fig. 6). In both patients, successful union was achieved using low contact, dynamic compression plates. In another 2 patients, a delay was seen in union of the proximal osteotomy site and union was achieved after grafting with autogenous bone.

In the patient who received the longest amount of lengthening (110 mm) the body of the fixator had to be replaced with a longer one in the 4th postoperative month, preserving the existing Schanz screws. In one patient the fixator was replaced due to fixator loosening. The fixator was replaced with plating in the 16th month.

Limitation of knee range of motion was seen in 6 patients with LRS fixators. In 5 adequate motion was achieved with appropriate physical rehabilitation and a Judet quadricepsplasty was required for the remaining patient. In one patient, limitation of hip

range of motion was seen and responded to physical rehabilitation.

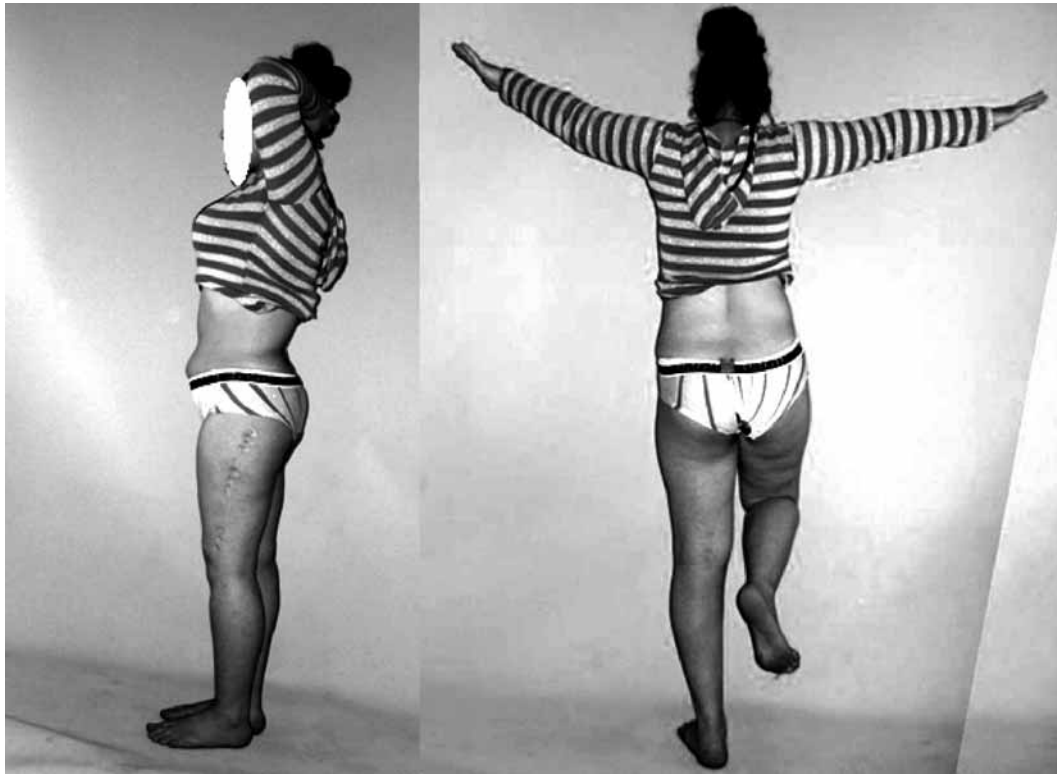
One of the patients with external fixators developed somatic signs during the treatment period and was treated medically with a diagnosis of depression.

In the youngest 2 patients (12 and 16 years old) the achieved valgus was lost in time. One patient did not have any problems while the instability recurred in the other one, necessitating a support osteotomy 35 months after the first operation.

## Discussion

The aim in the treatment of patients with hip instability is overcoming hip pain, equalizing limb length deficiency, preventing limping, improving range of motion of the hip and thus restoring hip stability whilst preserving the biomechanical alignment of the extremity (Table 3).

Due to improvements in surgical techniques and orthopedic implants, arthroplasty has become the main treatment choice for hip instabilities. A stable, mobile and painless hip can be obtained through hip arthroplasty.<sup>[1,2,15-17]</sup> It should be kept in mind that com-



**Fig 5.** Scars of a patient after pelvic support osteotomy using monolateral external fixator and improvement of Trendelenburg sign.

plications requiring revision surgery can be seen following hip arthroplasty.<sup>[17]</sup> Kim et al. reported a 17% rate of revision surgery for hip arthroplasty after a mean follow-up time of 10 years for patients with coxarthrosis due to neglected congenital dysplasia of the hip.<sup>[18]</sup> In another study by Hartofilakidis Karachalios, this rate was found to be 14 to 21% for the acetabular component and 14 to 16% for the femoral component after an average of 7 years.<sup>[19]</sup> MacKenzie et al. reported that 32% of their patients were in need of revision surgery for the acetabular component.<sup>[20]</sup>

More complications are present for patients with hip instability due to septic reasons. Chen et al. found a 14% rate of infection after hip arthroplasty in patients with coxarthrosis due to previous septic arthritis, and a 36% rate of total complications.<sup>[21]</sup> Choi et al. reported that pelvic support osteotomy was a more effective treatment, especially in patients with a destructed femoral head and neck.<sup>[22]</sup>

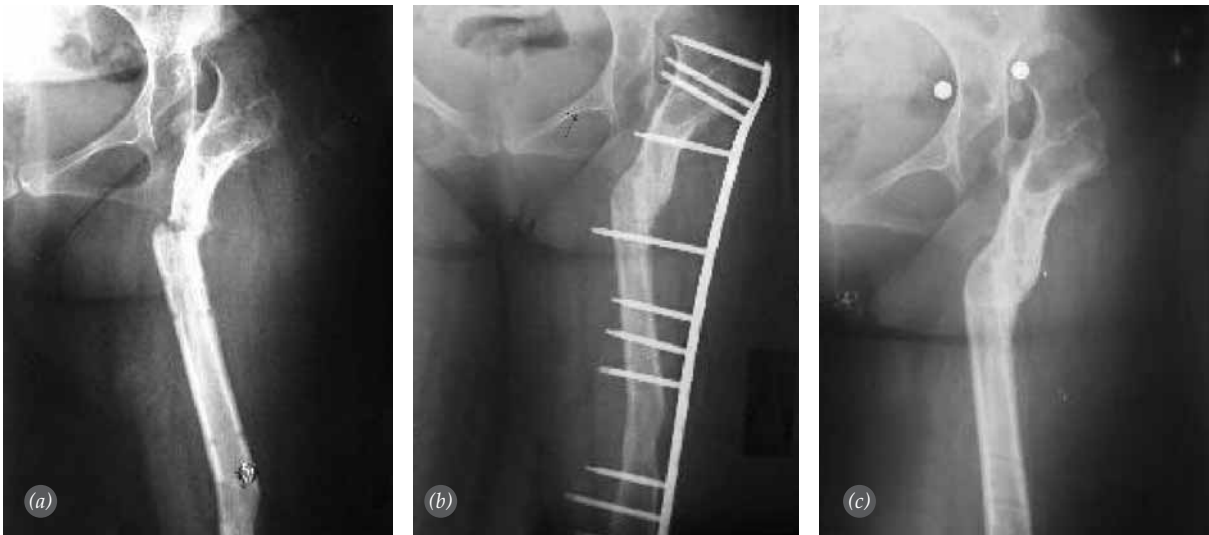One of the main objectives of pelvic support osteotomy is to correct the Trendelenburg gait. Kocaoğlu et al. reported a correction of the

Trendelenburg gait in 11 of their 14 patients.<sup>[23]</sup> Manzotti et al. reported correction in 9 of their 15 patients,<sup>[6]</sup> El-Mowafi in 20 of 25 patients<sup>[24]</sup> and Inan and Bowen in 12 of 16 patients.<sup>[25]</sup> In our study, the Trendelenburg gait persisted in 8 patients, although improvement was recorded. Inan et al. emphasized that correction of Trendelenburg sign depended on the age at the time of operation and the volume of the gluteus medius muscle.<sup>[26]</sup>

**Table 2.** Complications observed during the treatment.

Complication/Sequela	Number of patients	
	Paley Type 1	Paley Type 2
Trendelenburg*	8	
Decrease in the angulation of the osteotomy site <sup>†</sup>	2	
Pain	6	
Infection	7	8
Fracture at the osteotomy site <sup>‡</sup>	2	
Somatic problems	1	

\*At the last follow-ups, significant improvement in the Trendelenburg sign was recorded for patients with positive Trendelenburg sign. <sup>†</sup>Decrease in the angulation at the osteotomy site was seen in the youngest 2 patients. <sup>‡</sup>Fracture at the osteotomy site was seen in 2 patients after trauma.



**Fig 6.** (a-c) Fracture at the proximal osteotomy site after removal of external fixator. The fracture was fixed by locking plates and union was achieved.

Femoral head resection is an improvement of pelvic support osteotomy described by Milch.<sup>[25,27]</sup> Inan et al. performed femoral head resection for all of their patients<sup>[25,26,28]</sup> whilst Kocaoğlu et al. performed resection for three patients with pain in their neocotyles.<sup>[23]</sup> Schiltenwolf et al. reported satisfactory results in patients with congenital dysplasia of the hip for whom they performed subtrochanteric valgus osteotomy and no resection of the femoral head.<sup>[29]</sup> In our study, femoral head resection was only initially performed in one patient in the 26th postoperative month who experienced persisting pain.

There is no consensus on the ideal fixation method after pelvic support osteotomy. The external fixation technique was initially described by Ilizarov, who recommended circular external fixators. However, the large mass of the circular fixator may limit the functional capacity of the patient, decreases range of motion,<sup>[14]</sup> makes it difficult to maintain patient hygiene, and causes pain especially when the number of wires used increases. Monolateral external fixators have several advantages: the risk of pin track infection and pain is less.<sup>[28]</sup> Additionally, they are much more comfortable and patients prefer these devices.<sup>[30]</sup> Mangaleshkar et al. demonstrated that using monolateral external fixators for pelvic support osteotomy decreased the duration of surgical procedure.<sup>[31]</sup> Despite their advantages, monolateral external fixators are biomechanically less resistant to shearing

forces.<sup>[32]</sup> Manzotti et al. therefore introduced the use of hybrid external fixators for pelvic support osteotomy.<sup>[6]</sup> In our series of 20 patients, we used monolateral external fixators in 11 patients and circular external fixators in 8 patients. For one of the patients with bilateral neglected congenital dysplasia of the hip, angled LC-DCP plates were used at the osteotomy sites on both sides. Patients with circular external fixators complained of general discomfort. The duration of time the fixators were in place was significantly longer in patients with monolateral external fixators.

Milch reported that while valgus overcorrection at the proximal osteotomy site provides better hip stability, it is not recommended as it causes a decrease in the range of adduction.<sup>[33]</sup> According to

**Table 3.** Advantages and disadvantages of the technique.

Advantages of the technique	Disadvantages of the technique
<ul style="list-style-type: none"> <li>• Correction of hip flexion contracture</li> <li>• Restoration of hip stability</li> <li>• Pain relief</li> <li>• Improvement or correction of Trendelenburg sign</li> <li>• Elimination of limping</li> <li>• Better hygiene</li> <li>• Elimination of limb length discrepancy</li> </ul>	<ul style="list-style-type: none"> <li>• Decrease in the range of motion of the hip and the knee</li> <li>• Loss of correction and need of re-operation in adolescent patients</li> <li>• Possible need for femoral head resection</li> <li>• Psychiatric problems</li> <li>• Problems due to use of external fixators</li> </ul>

the literature, correction should be the degree of passive adduction plus an overcorrection of 15 to 25 degrees. Pafilas and Nayagam reported that the amount of overcorrection should be around 25 degrees,<sup>[8]</sup> whilst Jödicke recommended an angulation over 20 degrees and below 65 degrees.<sup>[34]</sup> Tönnis promoted a correction of 30 to 40 degrees.<sup>[35]</sup> In our 20 patients, the mean proximal valgus angulation was 38.45 degrees.

According to the series of Rozbruch et al., hip and knee range of motion of patients with sequela of septic arthritis was lower when compared to the ranges before pelvic support osteotomy. The authors stated that the decrease in the knee range of motion was due to stiffness of the quadriceps tendon after lengthening and the decrease in the hip range of motion was due to the direction of the proximal osteotomy.<sup>[36]</sup> In studies by Kocaoğlu et al.<sup>[23]</sup> and Emará,<sup>[37]</sup> mean range of motion of the hip was improved. In our series, we saw decreases in both knee and hip range of motions.

Age at the time of pelvic support osteotomy can affect successful results. Tönnis emphasizes that pelvic support osteotomy is contraindicated in growing children.<sup>[35]</sup> According to the literature, pelvic support osteotomy is usually recommended in patients above 15 years of age.<sup>[23,38,39]</sup> However, the optimal age limits for classical Schanz osteotomy is between 9 and 40 years.<sup>[23]</sup> Ilizarov states that the mean loss of correction at the osteotomy site was 3 to 13 degrees for patients between 9 and 17 years of age.<sup>[12]</sup> In their study, Kocaoğlu et al. experienced a 5 degrees loss of correction in a 12 years old patient who had pelvic support osteotomy.<sup>[38]</sup> El-Mowafi did not report any loss of correction in patients ageing between 19 and 35.<sup>[24]</sup> In our series, we observed correction losses of 6 and 5 degrees in the youngest two patients aged 12 and 16 years, respectively. In conclusion, we think pelvic support osteotomy is more appropriate for patients between 16 and 40 years old.

Pelvic support osteotomy is usually preferred in young adulthood where active life expectancy is longer. Pelvic support osteotomy is not a contraindication for future hip arthroplasty, although distal varus osteotomy would make it more difficult to perform.<sup>[40-42]</sup>

The small incisions created by the osteotomy and fixator pins leave minimal scar tissue. As the soft tissue mass is thick around the femur the deformity

will not be obvious on inspection. The increased range of abduction will provide better hygiene and sexual relation.<sup>[6]</sup>

A possible limitation of our study is the use of different implants for fixation. However, Inan et al. could not find a significant functional difference between patients receiving either monolateral or circular external fixators. Other than the rate of pin tract infections and patient comfort, it is possible to say that fixator type has little impact on the results.<sup>[28]</sup> We also think that implants have limited impact on the results if the technique applied is the same.

In conclusion, pelvic support osteotomy seems to be an effective treatment option in young active patients with instability of the hip, as it is successful in restoring hip stability, eliminating pain, equalizing limb length deficiency and correcting the alignment of the extremity. However, long term pelvic support osteotomy studies using standard implants are needed in order to better understand the efficacy of the technique.

**Conflicts of Interest:** No conflicts declared.

## References

1. Garvin KL, Bowen MK, Salvati EA, Ranawat CS. Long-term results of total hip arthroplasty in congenital dislocation and dysplasia of the hip. A follow-up note. *J Bone Joint Surg Am* 1991;73:1348-54.
2. Hartofilakidis K, Stamos K, Karachalios T. Treatment of high dislocation of the hip in adults with total hip arthroplasty. Operative technique and long-term clinical results. *J Bone Joint Surg Am* 1998;80:510-7.
3. Moyad TF, Thornhill T, Estok D. Evaluation and management of the infected total hip and knee. *Orthopedics* 2008; 31:581-8.
4. Beaulé PE, Matta JM, Mast JW. Hip arthrodesis: current indications and techniques. *J Am Acad Orthop Surg* 2002; 10:249-58.
5. Gaenslen FJ. The Schanz subtrochanteric osteotomy for irreducible dislocation of the hip. *J Bone Joint Surg Am* 1935;17:76-87.
6. Manzotti A, Rovetta L, Pullen C, Catagni MA. Treatment of late sequelae of septic arthritis of the hip. *Clin Orthop Relat Res* 2003;(410):203-12.
7. Aksoy MC, Musdal Y. Subtrochanteric valgus-extension osteotomy for neglected congenital dislocation of the hip in young adults. *Acta Orthop Belg* 2000;66:2:181-6.
8. Pafilas D, Nayagam S. The pelvic support osteotomy: indications and preoperative planning. *Strat Traum Limb Recon* 2008;3:83-92.
9. Schanz A. Zur Behandlung der veralteten angeborenen Hüftverrenkung. *Munch Med Wschr* 1922;99:930.



10. Hass J. A Subtrochanteric osteotomy for pelvic support. *J Bone Joint Surg Am* 1943;25:281-91.
11. Milch H. The pelvic support osteotomy. *Clin Orthop Relat Res* 1989;(249):4-11.
12. Ilizarov GA. *Transosseous osteosynthesis*. Berlin: Springer; 1992.
13. Harris WH. Traumatic arthritis of the hip after dislocation and acetabular fractures: treatment by mold arthroplasty. An end-result study using a new method of result evaluation. *J Bone Joint Surg Am* 1969;51:737-55.
14. Paley D. Problems, obstacles, and complications of limb lengthening by the Ilizarov technique. *Clin Orthop Relat Res* 1990;(250):81-104.
15. Eskelinen A, Helenius I, Remes V, Ylinen P, Tallroth K, Paavilainen T. Cementless total hip arthroplasty in patients with high congenital hip dislocation. *J Bone Joint Surg Am* 2006;88:80-91.
16. Davlin LB, Amstutz HC, Tooke SM, Dorey FJ, Nasser S. Treatment of osteoarthritis secondary to congenital dislocation of the hip. Primary cemented surface replacement compared with conventional total hip replacement. *J Bone Joint Surg Am* 1990;72:1035-42.
17. Wangen H, Lereim P, Holm I, Gunderson R, Reikerås O. Hip arthroplasty in patients younger than 30 years: excellent ten to 16-year follow-up results with a HA-coated stem. *Int Orthop* 2008;32:203-8.
18. Kim YH, Kim JS. Total hip arthroplasty in adult patients who had developmental dysplasia of the hip. *J Arthroplasty* 2005;20:1029-36.
19. Hartofilakidis G, Karachalios T. Total hip arthroplasty for congenital hip disease. *J Bone Joint Surg Am* 2004;86:242-50.
20. MacKenzie JR, Kelley SS, Johnston RC. Total hip replacement for coxarthrosis secondary to congenital dysplasia and dislocation of the hip. Long-term results. *J Bone Joint Surg Am* 1996;78:55-61.
21. Chen CE, Wang JW, Juhn RJ. Total hip arthroplasty for primary septic arthritis of the hip in adults. *Int Orthop* 2008;32:573-80.
22. Choi IH, Shin YW, Chung CY, Cho TJ, Yoo WJ, Lee DY. Surgical treatment of severe sequelae of infantile septic arthritis of the hip. *Clin Orthop Relat Res* 2005;(434):102-9.
23. Kocaoğlu M, Eralp L, Şen C, Dinçyürek H. The Ilizarov hip reconstruction osteotomy for hip dislocation: outcome after 4-7 years in 14 young patients. *Acta Orthop Scand* 2002;73:432-8.
24. El-Mowafi H. Outcome of pelvic support osteotomy with the Ilizarov method in the treatment of the unstable hip joint. *Acta Orthop Belg* 2005;71:686-91.
25. Inan M, Bowen RJ. A pelvic support osteotomy and femoral lengthening with monolateral fixator. *Clin Orthop Relat Res* 2005;(440):192-8.
26. Inan M, Alkan A, Harma A, Ertem K. Evaluation of the gluteus medius muscle after a pelvic support osteotomy to treat congenital dislocation of the hip. *J Bone Joint Surg Am* 2005;87:2246-52.
27. Milch H. The resection-angulation operation for hip-joint disabilities. *J Bone Joint Surg Am* 1955;37:699-717.
28. Inan M, Bomar JD, Küçükkaya M, Harma A. A comparison between the use of a monolateral external fixator and the Ilizarov technique for pelvic support osteotomies. [Article in Turkish] *Acta Orthop Traumatol Turc* 2004;38:252-60.
29. Schiltenswolf M, Carstens C, Bernd L, Lukoschek M. Late results after subtrochanteric angulation osteotomy in young patients. *J Pediatr Orthop B* 1996;5:259-67.
30. Glorion C, Pouliquen JC, Langlais J, Ceolin JL, Kassis B. Femoral lengthening using the callotasis method: study of the complications in a series of 70 cases in children and adolescents. *J Pediatr Orthop* 1996;16:161-7.
31. Mangaleshkar S, Paley D, Herzenberg JE. Ilizarov hip reconstruction using monolateral fixator. 15th Annual Limb Deformity Course, Baltimore, USA, 2004.
32. Paley D, Fleming B, Catagni M, Kristiansen T, Pope M. Mechanical evaluation of external fixators used in limb lengthening. *Clin Orthop* 1990;(250):50-7.
33. Milch H. The postosteotomy angle. *J Bone Joint Surg Am* 1944;26:394-400.
34. Jödicke G. Indications for subtrochanteric osteotomy by Schanz. *Z Orthop Ihre Grenzgeb* 1955;85:534-52.
35. Tönnis D. *Congenital dysplasia and dislocation of the hip in children and adults*. Berlin: Springer; 1987.
36. Rozbruch SR, Paley D, Bhave A, Herzenberg JE. Ilizarov hip reconstruction for the late sequelae of infantile hip infection. *J Bone Joint Surg Am* 2005;87:1007-18.
37. Emara KM. Pelvic support osteotomy in the treatment of patients with excision arthroplasty. *Clin Orthop Relat Res* 2008;466:708-13.
38. Kocaoğlu M, Eralp L, Şen C, Bilen FE, Küçükkaya M. Early results of Ilizarov hip reconstruction osteotomy in the treatment of high dislocation of the hip. [Article in Turkish] *Acta Orthop Traumatol Tur* 2000;34:359-67.
39. Samchukov ML, Birch JG. pelvic support femoral reconstruction using the method of Ilizarov: a case report. *Bull Hosp Jt Dis* 1992;52:7-11.
40. Berry DJ. Total hip arthroplasty in patients with proximal femoral deformity. *Clin Orthop Relat Res* 1999;(369):262-72.
41. Merchan EC, Galindo E. Iatrogenic Z-deformity of the proximal femur in an osteoarthritic hip. Subtrochanteric osteotomy with intramedullary fixation for arthroplasty of the hip. A case report. *Acta Orthop Belg* 1993;59:197-201.
42. Papagelopoulos PJ, Trousdale RT, Lewallen DG. Total hip arthroplasty with femoral osteotomy for proximal femoral deformity. *Clin Orthop Relat Res* 1996;(332):151-62.