



# Avoiding iatrogenic radial nerve injury during humeral fracture surgery: a modified approach to the distal humerus

Ahmet Özgür YILDIRIM<sup>1</sup>, Özdamar Fuad ÖKEN<sup>1</sup>, Vuslat Sema ÜNAL<sup>2</sup>, Ali Fırat ESMER<sup>3</sup>,  
Murat GÜLÇEK<sup>1</sup>, Ahmet UÇANER<sup>1</sup>

<sup>1</sup>Department of Orthopaedics and Traumatology, Ankara Numune Training and Research Hospital, Ankara, Turkey;

<sup>2</sup>Department of Orthopaedics and Traumatology, Acıbadem Maslak Hospital, İstanbul, Turkey;

<sup>3</sup>Department of Anatomy, Faculty of Medicine, Ankara University, Ankara, Turkey

**Objective:** Our aim was to assess the results of posterior retraction technique to prevent iatrogenic radial nerve injury during humeral fracture surgery.

**Methods:** Seventy-two patients who underwent surgery for a distal humerus fracture between 1996 and 2002 were reviewed. These 72 patients comprised Group 1. Following a cadaveric study on the vascularization of the radial nerve, a modified surgical approach was undertaken starting in 2002. Sixty-one patients who underwent this new surgical approach were included in Group 2. The rates of radial nerve deficit of the groups were compared using the Pearson chi-square test.

**Results:** In Group 1, 19 iatrogenic nerve deficits occurred. After defining the blood circulation of the nerve, the lateral approach was modified. The anterolateral side of the nerve was released and the nerve was left attached to the triceps muscle. In Group 2, one patient developed postoperative transient nerve deficit.

**Conclusion:** The radial nerve is supplied by the branches of the deep brachial artery in close relation with the triceps muscle. Anterior dissection and posterior retraction of the radial nerve during lateral approach may preserve its blood supply and reduces the risk of iatrogenic injury.

**Key words:** Blood supply of the radial nerve; distal humeral fracture; humeral fracture surgery; iatrogenic radial nerve injury; radial nerve.

Transient and/or permanent radial nerve injury following distal humerus fractures is not rare (2% to 5%)<sup>[1]</sup> and may iatrogenically occur at surgery.<sup>[2-4]</sup> The pathophysiology of iatrogenic radial nerve injury remains unclear. Blood supply disruption of the nerve is hypothesized to play an important role in this morbid condition.<sup>[5,6]</sup> However, landmarks of the radial

nerve and its blood supply in accordance to the intermuscular septum of the distal humerus have not previously been anatomically studied.<sup>[7]</sup>

The aim of this multi-stage study was to anatomically describe the vasculature of the radial nerve at the distal third of the humerus and assess the outcomes of retracting the radial nerve to the posterior of the

**Correspondence:** Fuad Özdamar Öken, MD. Ankara Numune Eğitim ve Araştırma Hastanesi, 1. Ortopedi ve Travmatoloji Kliniği, Sıhhiye 06100 Ankara, Turkey.

Tel: +90 312 508 51 01 e-mail: fuadoken@yahoo.com

**Submitted:** October 25, 2010 **Accepted:** February 2, 2011

©2012 Turkish Association of Orthopaedics and Traumatology

Available online at  
www.aott.org.tr  
doi:10.3944/AOTT.2012.2564  
QR (Quick Response) Code:



humerus during plate fixation in comparison with tape suspension.

## Materials and methods

In the first stage of the study, we retrospectively evaluated seventy-seven patients with a distal humerus fracture who underwent open reduction and internal plate-screw fixation between 1996 and 2002. Seventy-two patients (43 male, 29 female) without preoperative radial nerve deficiency were included in Group 1. Open fractures were excluded. Average age was  $34.1 \pm 12.6$  (range: 17 to 63) years. Fractures were classified according to the AO/OTA system (Table 1). Preoperative radial nerve functions were normal. A lateral approach was used in all cases. Before reduction and internal fixation, the radial nerve was located, dissected and suspended with a tape. After reduction and internal fixation, the radial nerve was replaced into its anatomical location. Radial nerve transposition was not performed in any of the patients. Patients were followed-up for an average of  $8.2 \pm 1.5$  (range: 5.9 to 11.8) years with clinical and radiographic examinations every 2 weeks until bone union.

During the second stage of study, a cadaveric study on 10 arms of 5 cadavers was carried out to define radial nerve blood flow. The radial nerve was visualized using the same surgical incision as in the clinical approach. The vessels were colored with an injection of red silicone into the axillary artery before dissection.<sup>5</sup> The two arterioles arising from the deep branch of the brachial artery supplying the distal part of the radial nerve were identified before bifurcation. These ran from posterior to anterior within the triceps muscle at the level of the distal third of the humerus. The vessels passed along the nerve sheath from the posterior to the anterior. The distances between the proximal nutrient arteriole to the lateral epicondyle, the proximal to the distal nutrient arteriole, and the distal to the lateral epicondyle were measured.

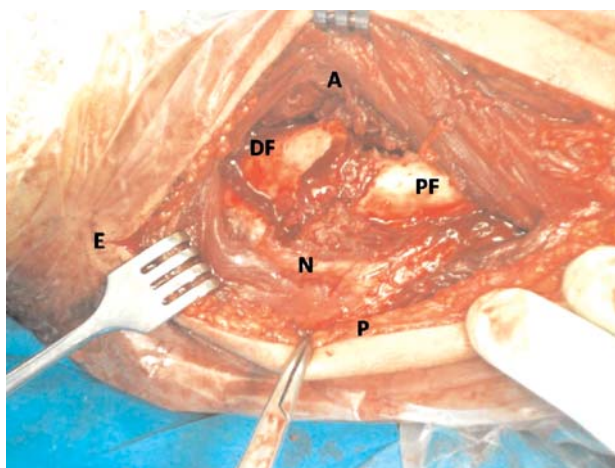
In the third stage, the lateral surgical approach was modified by releasing the anterolateral of the radial nerve and retracting it to the posterior. Sixty-one patients (32 male, 29 female) operated on using this modified approach between 2002 and 2006 were prospectively followed-up and included in Group 2. Average age was  $39.8 \pm 13.9$  (range: 18 to 65) years. The groups were homogenous for the distribution of the age, sex and fracture type. The same surgeons (AOY, FOO, VSU) performed the open reduction and internal plate-screw fixation in both groups using the same

**Table 1.** Distribution of fractures according to AO/OTA classification.

Fracture type (AO/OTA classification)	Group 1 (n=72)	Group 2 (n=61)	Total (n=133)
12 A 12	13 (18.1%)	18 (29.6%)	31 (23.4%)
12 A 22	10 (13.9%)	6 (9.8%)	16 (12.0%)
12 A 32	11 (15.3%)	5 (8.2%)	16 (12.0%)
12 B 12	3 (4.2%)	12 (19.6%)	15 (11.2%)
12 B 22	20 (27.6%)	6 (9.8%)	26 (19.6%)
12 B 32	4 (5.6%)	2 (3.3%)	6 (4.5%)
12 C 12	0	3 (4.9%)	3 (2.3%)
12 C 22	11 (15.3%)	9 (14.8%)	20 (15.0%)
12 C 32	0	0	0

lateral approach (Fig. 1). The radial nerve was visualized after passing the fascia of the triceps muscle. The muscular and intermuscular septum connections of the radial nerve were protected. The anterolateral side was released and the radial nerve was left attached to the triceps muscle. A Hohmann retractor was used to retract the radial nerve and the triceps muscle to the posterior, thus preserving blood supply to the radial nerve. Radial nerve transposition was not performed in any of the patients.

Data were analyzed using the Pearson chi-square test. Data analysis was performed using the SPSS for Windows (version 11.5) software. A p value of less than 0.05 was considered statistically significant.



**Fig. 1.** Perioperative view of the radial nerve being retracted posteriorly together with the triceps, through a modified lateral approach. A: anterior of the left arm, P: posterior of the left arm, DF: distal fragment of the fracture, PF: proximal fragment of the fracture, N: radial nerve, E: lateral epicondyle. [Color figure can be viewed in the online issue, which is available at [www.aott.org.tr](http://www.aott.org.tr)]

## Results

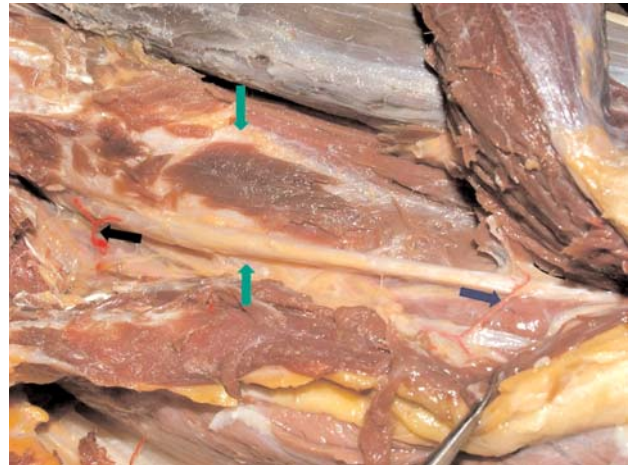
Group 1 included 15 transient and 4 permanent iatrogenic radial nerve injuries. Patients had hypoesthesia on the dorsum of their hands and forearms. Motor examination revealed typical wrist drop. There was an inability to extend the fingers at the metacarpophalangeal joints and the inability to extend and abduct the thumb. Patients with postoperative radial nerve deficits were followed up with clinical examinations and electromyography. A dynamic radial splint was postoperatively applied and radial nerve functions recovered between 9 to 16 weeks in 15 patients (average:  $13 \pm 2.4$  weeks). The remaining 4 patients had permanent iatrogenic radial nerve palsy and needed additional tendon transfer to recover wrist and finger functions. Three non-unions required further surgical intervention. Malunion did not occur in any of the patients.

The cadaveric study showed that the two deep brachial artery branches which run from the radial groove to the supraepicondylar process supply blood to the radial nerve (Fig. 2). These branches passed from the triceps muscle from the posterior towards the anterior. The distance between the proximal nutrient arteriole and the lateral epicondyle was  $10.1 \pm 0.2$  (range: 9.8 to 10.4) cm, distance between the proximal and distal nutrient arteriole was  $6.3 \pm 0.2$  (range: 6.1 to 6.5) cm and the distance between the distal nutrient arteriole and the lateral epicondyle was  $3.8 \pm 0.1$  (range: 3.4 to 4.0) cm. It was thought that preservation of the relationship of the radial nerve to the triceps muscle would protect these short and delicate vessels. We postulated that the more blood supply preserved, the less hypoxia of the nerve would occur, thus decreasing its vulnerability to injury.

After our anatomical findings and modification of the radial nerve treatment during surgery, only one patient in Group 2 had symptoms of radial nerve injury which recovered three months postoperatively. After a mean follow-up period of  $36 \pm 11.1$  (range: 15 to 62) months, bone union was achieved in 59 patients. Two patients required bone grafting due to delayed healing. The rate of iatrogenic radial nerve deficit was 26.4% in Group 1, whereas it was significantly lower in Group 2 (1.6%) ( $p < 0.001$ ) (Table 2).

## Discussion

Radial nerve tape suspension is a current approach in clinical practice. However, our results showed that the incidence of iatrogenic injury during open reduction and internal plate-screw fixation for the treatment of distal humeral fractures decreased from 26.4% to 1.6% when release and tape suspension of the radial nerve is



**Fig. 2.** Photograph of a dissection. The radial nerve passing anteriorly from the radial groove to the supraepicondylar process was found to be supplied by branches coming from the deep brachial artery. Black (left) arrow: proximal nutrient vessel, blue (right) arrow: distal nutrient vessel, between green (above and below) arrows: the humerus. [Color figure can be viewed in the online issue, which is available at [www.aott.org.tr](http://www.aott.org.tr)]

avoided. Radial nerve blood supply has previously been investigated. El-Barrany et al. investigated the blood supply of peripheral nerves for vascularized nerve grafts, although the study only focused on the superficial branch of the radial nerve and its blood supply.<sup>[5]</sup> This study's findings failed to explain surgical outcomes. One cadaveric study proposed the anterior transposition of the radial nerve following wide dissection to prevent traction injuries.<sup>[4]</sup> Yakkanti et al. investigated radial nerve transposition on cadaver dissec-

**Table 2.** Demographic and clinical data of Group 1 and 2 patients.

Variable	Group 1 (n=72)	Group 2 (n=61)	Total (n=133)
Age (year)	34.1 (17-63)	39.8 (18-65)	
Sex			
Male	43 (59.7%)	32 (52.4%)	75 (56.3%)
Female	29 (40.3%)	29 (47.6%)	58 (43.7%)
Side			
Right	32 (44.4%)	44 (27.9%)	76 (57.1%)
Left	40 (55.6%)	17 (27.1%)	57 (42.9%)
Trauma mechanism			
Fall	41 (56.9%)	16 (26.2%)	57 (42.9%)
Traffic accident	31 (43.1%)	45 (73.8%)	76 (57.1%)
Time to surgery (day)	5.2 (1-9)	4.9 (1-7)	
Complication			
Radial deficit	19 (26.3%)	1 (1.6%)	20 (15.03%)
Non-union	3 (4.1%)	0	3 (2.2%)
Infection	5 (6.9%)	3 (4.9%)	8 (6.1%)

tions for the posterior approach.<sup>[4]</sup> Our study differed in that we used the lateral approach for dissections and Yakkanti et al. used the posterior approach. Two nutrient arteries of the radial nerve that take root from the deep brachial artery were visualized in our study. These branches were located inside the triceps muscle, extending to the radial nerve at the distal part. The mean length of the proximal to the lateral epicondyle, the mean distance between the proximal and the distal arteriole and the distance between the distal to lateral epicondyle of these arteries were found to be too short to allow tape suspension of the radial nerve. These landmarks were prone to damage the radial nerve during the elevation from the adjacent soft tissues and engendered the change in surgery technique from our classical lateral approach.

The radial nerve is in direct contact with the distal humeral bone. Since it is fed posteriorly through the triceps muscle, it is more logical to release it anteriorly at the intermuscular septum and retract it posteriorly with the muscle. These branches were preserved during exposure, and tape suspension was prevented. Instead, the nerve was dissected from the anterior structures and retracted posteriorly together with the triceps, thus preserving muscle nerve connection. The subsequent steps of the operation were not modified. Since the implementation of this modified approach in 2002, the incidences of radial nerve injury in our clinic decreased from 26.4% to 1.6%. The lower incidence of radial nerve palsy in Group 2 may be explained by the protection of the branches of the arteries. We believe that intraneural vascularity of the radial nerve may thus be preserved.

The lateral approach is an alternative to the anteromedial and posterior approach in the management of fractures of the middle and distal thirds of the shaft of the humeral bone.<sup>[8-11]</sup> In the classical technique, the radial nerve is released and suspended before fracture management.<sup>[6,10,12,13]</sup> In some articles, it is suggested that it should be transposed during fracture management.<sup>[4,11]</sup> The radial nerve is extremely vulnerable to injuries which then produce additional problems during postoperative rehabilitation.<sup>[14,15]</sup> Stretching and compression of the nerve may be the common causes of this peripheral neuropathy. The delicate blood supply was the focus of our interest. There are a number of studies in the literature on iatrogenic nerve palsy.<sup>[1,4]</sup> Although iatrogenic radial nerve injuries usually recover spontaneously, they may remain permanent and constitute a challenge for both the patient and the physician.<sup>[1,14,16]</sup> The reported incidence of radial nerve

injury following surgical intervention is between 2% and 5%.<sup>[4,11]</sup> In a study using the anterolateral and anterior brachial splitting surgical approach, Wang et al. reported the incidence of radial nerve palsy as 4.2%.<sup>[1]</sup>

To our knowledge our study was the first to combine an anatomic cadaveric study with clinical series on radial nerve injury following the surgical treatment of humeral fractures. Our study indicated the benefits of preserving the arterioles that originate from the deep brachial artery in the triceps muscle and supply blood to the distal part of the radial nerve.

In conclusion, a posterior retraction of the radial nerve with the triceps muscle after anterior dissection without suspension preserves blood flow of the nerve and thus reduces the risk of iatrogenic injury during lateral approach to the distal humerus.

## Acknowledgement

The authors would like to thank Prof. Dr. Feza Korkusuz (Middle East Technical University, Ankara) for his extensive support and Salih Ergöçen for his statistical analyses in preparation of this study.

**Conflicts of Interest:** No conflicts declared.

## References

1. Wang JP, Shen WJ, Chen WM, Huang CK, Shen YS, Chen TH. Iatrogenic radial nerve palsy after operative management of humeral shaft fractures. *J Trauma* 2009;66:800-3.
2. DeFranco MJ, Lawton JN. Radial nerve injuries associated with humeral fractures. *J Hand Surg Am* 2006;31:655-63.
3. Ekholm R, Adami J, Tidermark J, Hansson K, Törnkvist H, Ponzer S. Fractures of the shaft of the humerus. An epidemiological study of 401 fractures. *J Bone Joint Surg B* 2006;88:1469-73.
4. Yakkanti MR, Roberts CS, Murphy J, Acland RD. Anterior transposition of the radial nerve – a cadaveric study. *J Orthop Trauma* 2008;22:705-8.
5. El-Barrany WG, Marei AG, Vallée B. Anatomic basis of vascularised nerve grafts: the blood supply of peripheral nerves. *Surg Radiol Anat* 1999;21:95-102.
6. Fleming P, Lenehan B, Sankar R, Folan-Curran J, Curtin W. One-third, two-thirds: relationship of the radial nerve to the lateral intermuscular septum in the arm. *Clin Anat* 2004;17:26-9.
7. Carlan D, Pratt J, Patterson JM, Weiland AJ, Boyer MI, Gelberman RH. The radial nerve in the brachium: an anatomic study in human cadavers. *J Hand Surg Am* 2007;32:1172-82.
8. King A, Johnston GH. A modification of Henry's anterior approach to the humerus. *J Shoulder Elbow Surg* 1998;7:210-2.
9. Mekhail AO, Checroun AJ, Ebraheim NA, Jackson WT, Yeasting RA. Extensile approach to the anterolateral surface

- of the humerus and the radial nerve. *J Shoulder Elbow Surg* 1999;8:112-8.
10. Mills WJ, Hanel DP, Smith DG. Lateral approach to the humeral shaft: an alternative approach for the fracture treatment. *J Orthop Trauma* 1996;10:81-6.
  11. Zlotolow DA, Catalano LW 3rd, Barron OA, Glickel SZ. Surgical exposures of the humerus. *J Am Acad Orthop Surg* 2006;14:754-65.
  12. Bono CM, Grossman MG, Hochwald N, Tornetta P 3rd. Radial and axillary nerves. Anatomic considerations for humeral fixation. *Clin Orthop Relat Res* 2000;(373):259-64.
  13. Gerwin M, Hotchkiss RN, Weiland AJ. Alternative operative exposures of the posterior aspect of the humeral diaphysis with reference to the radial nerve. *J Bone Joint Surg Am* 1996;78:1690-5.
  14. O'Driscoll. Optimizing stability in distal humeral fracture fixation. *J Shoulder Elbow Surg* 2005;14(1 Suppl S):186S-194S.
  15. Uhl RL, Larosa JM, Sibeni T, Martino LJ. Posterior approaches of the humerus: when should you worry about the radial nerve? *J Orthop Trauma* 1996;10:338-40.
  16. Ring D, Chin K, Jupiter JB. Radial nerve palsy associated with high-energy humeral shaft fractures. *J Hand Surg Am* 2004;29:144-7.