



## Cystic transphyseal bone tuberculosis: a report of two cases

Turgut AKGÜL, Harzem ÖZGER, Bora Süleyman GÖKSAN, İlker EREN

*Department of Orthopedics and Traumatology, Faculty of Medicine, İstanbul University, İstanbul, Turkey*

We present two cases of tuberculosis osteomyelitis mimicking subacute osteomyelitis and treated without extensive debridement. Tuberculous osteomyelitis should be considered in the differential diagnosis of proximal tibial infections in children and early diagnosis and treatment is possible without extensive debridement.

**Key words:** Cystic lesion; skeletal tuberculosis; subacute osteomyelitis.

Tuberculosis of the bones and joints is a rare granulomatous infection caused by *Mycobacterium tuberculosis*. It remains a common health problem in many countries despite effective medical treatment. The spine is the most frequent site of skeletal involvement of tuberculosis. Infection around the hip and the knee is also a common skeletal presentation.<sup>[1]</sup> Diagnosis is often delayed because of differential diagnosis from other diseases, such as subacute osteomyelitis, due to other microorganisms and bone tumors.<sup>[2-5]</sup>

We present two cases of transphyseal tuberculous osteomyelitis mimicking subacute osteomyelitis.

### Case reports

#### Case 1

A four-year-old child presented with pain in the left cruris and limping. He had a previous diagnosis of reactive arthritis and was treated with anti-inflammatory drugs. The patient was referred to an orthopaedic surgeon as the symptoms were not resolving.

Blood studies revealed a normal leukocyte count ( $8 \times 10^3$ ), a C-reactive protein level of 0.4 mg/L and an

erythrocyte sedimentation rate of 4 mm/h. Radiographs of the left knee showed radiolucent zones in both the epiphysis and the metaphysis of the proximal part of the tibia and disruption of the growth plate (Fig. 1). Initial diagnosis was subacute bacterial infection of the proximal part of the tibia. The tibia was immobilized and no weight-bearing was permitted. Empirical wide spectrum antibiotherapy was administered for subacute osteomyelitis without biopsy.

The patient's symptoms persisted despite antibiotherapy. Computerized tomography examination showed osteolytic lesions disrupting the growth plate at both the metaphyseal and the epiphyseal regions (Fig. 2). Because of persisting symptoms, a tru-cut biopsy of the lytic lesions was performed. Tuberculosis infection was verified through histopathologic examination. A combined therapy of isoniazid (10 mg/kg per day), rifampicin (10 mg/kg per day), pyrazinamide (35 mg/kg per day) and streptomycin (15 mg/kg per day) was administered for the first 3 months. After the 4th month, isoniazid and rifampicin were continued at the same doses for an additional 12 months. All symptoms

**Correspondence:** Turgut Akgül, MD. İstanbul Üniversitesi Tıp Fakültesi, Ortopedi ve Travmatoloji Anabilim Dalı, Millet Cad., Fatih, İstanbul, Turkey.

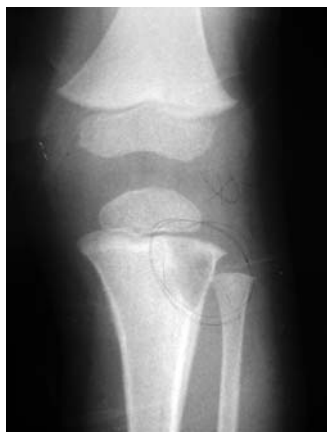Tel: +90 212 - 414 20 00 e-mail: doktorturgut@yahoo.com

**Submitted:** April 23, 2011 **Accepted:** August 25, 2011

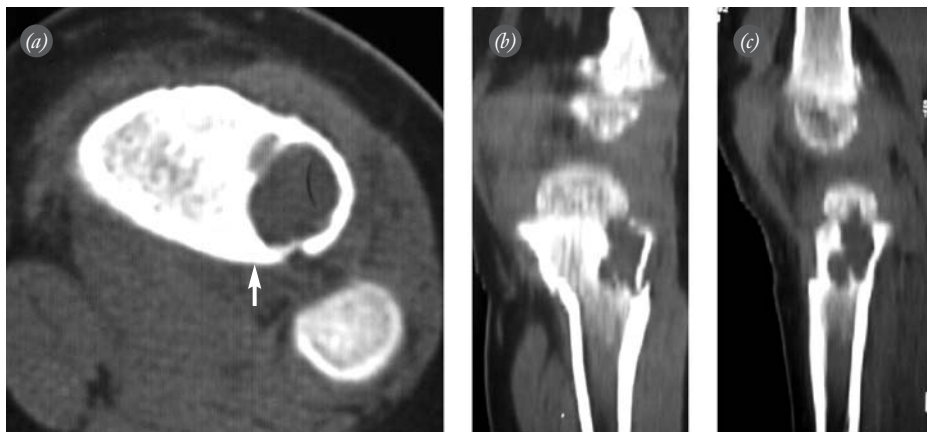
©2012 Turkish Association of Orthopaedics and Traumatology

Available online at  
www.aott.org.tr  
doi:10.3944/AOTT.2012.2698  
QR (Quick Response) Code:





**Fig. 1.** Lytic lesion located at the metaphyseal region of the proximal tibia.



**Fig. 2.** CT scan of the tibia reveal new bone formation at the posterolateral part of the lesion, (a) indicating a possible low grade infection (arrow) with (b, c) growth plate disruption.

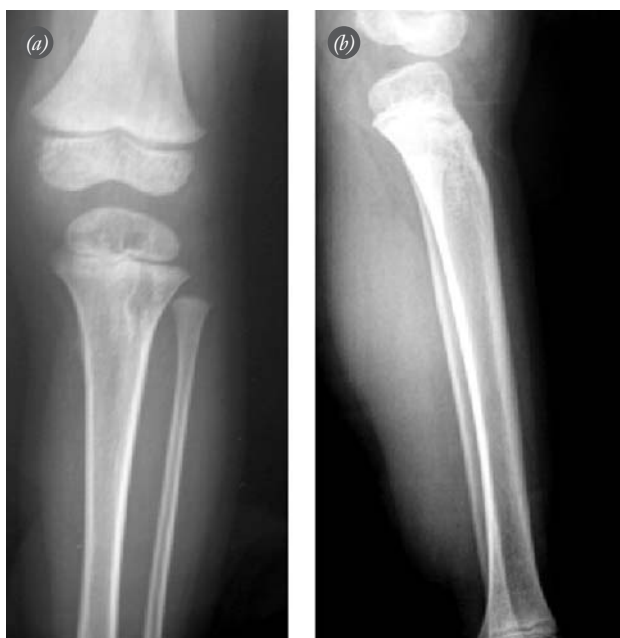were resolved at the final follow-up. Follow-up radiographs showed reduction of the lytic area of the bone lesion in the proximal tibial metaphysis and the epiphysis (Fig. 3).

**Case 2**

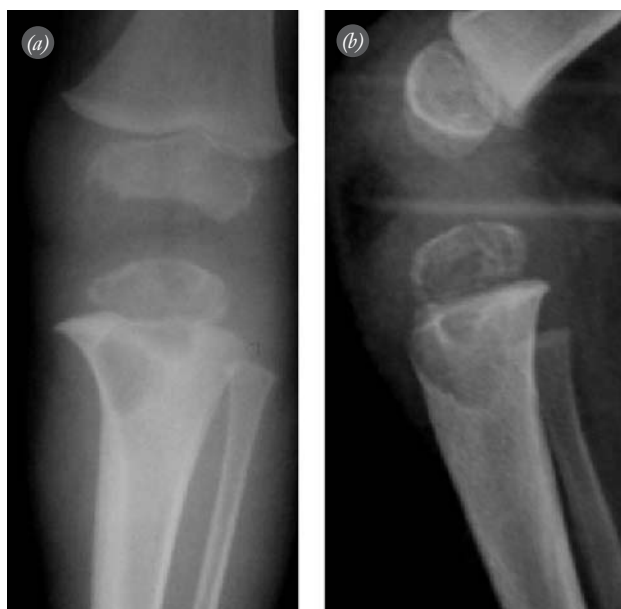An eighteen-month-old child presented with complaints of pain in the left cruris and limping. Blood studies revealed a normal leukocyte count ( $5 \times 10^3$ ), a slightly elevated C-reactive protein level (6.1 mg/L) and an erythrocyte sedimentation rate of 12 mm/h. The patient

was initially diagnosed with a subacute bacterial infection of the proximal part of the tibia and antibiotherapy was recommended by an orthopaedic surgeon (Fig. 4).

Before the antibiotherapy commenced, the patient applied to our clinic. Computerized tomography (CT) scan and magnetic resonance imaging was performed. Radiological evaluations revealed osteolytic lesions disrupting the growth plate containing calcified foci located at both the metaphyseal and the epiphyseal region (Figs. 5 and 6). We performed a tru-cut biopsy of the osteolytic lesions and tuberculosis infection was verified



**Fig. 3.** (a, b) Size of the lytic lesions decreased in the 13th month follow-up view of Patient 1.



**Fig. 4.** (a, b) Lytic lesion located at the metaphyseal and epiphyseal region of the proximal tibia, disrupting the growth plate in Patient 2.

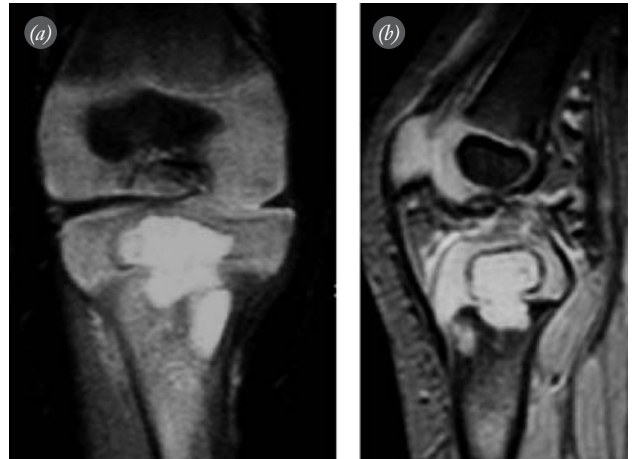
through histopathologic examination. CT of the thorax revealed subpleural granulomas compatible with pulmonary tuberculosis. ELISPOT and PPD tests were negative. The patient received a combined therapy of isoniazid (10 mg/kg per day), rifampicin (10 mg/kg per day), pyrazinamide (30 mg/kg per day) and streptomycin (15 mg/kg per day) for the first 6 weeks. Streptomycin was discontinued after the 40th day of treatment and pyrazinamide after the 2nd month. Clinical and radiological findings of the patient improved significantly over the course of a follow-up period of more than 3 months. The patient continues to be followed-up with isoniazid and rifampicin therapy.

## Discussion

Long bone tuberculous osteomyelitis is less common than spinal involvement or tuberculous arthritis and has been reported to occur in only 11% of children with skeletal infection.<sup>[6]</sup> Patients' complaints, symptoms, laboratory results and radiological evaluation had a strong resemblance with subacute osteomyelitis and our cases initially received a diagnosis of subacute osteomyelitis prior to biopsy. The presence of these lytic lesions was explained by the bacterial foci. Bacterial infections inducing an inflammatory reaction create local bone destruction with or without periosteal reaction through a combination of pressure atrophy and inflammatory granulation tissue.<sup>[6]</sup> Antibiotherapy has been widely accepted for the treatment of subacute osteomyelitis. In the literature, biopsy is controversial. The ability to identify the causative organism by culture is limited and positive results are obtained in only 29 to 61 percent of cases.<sup>[7-9]</sup>

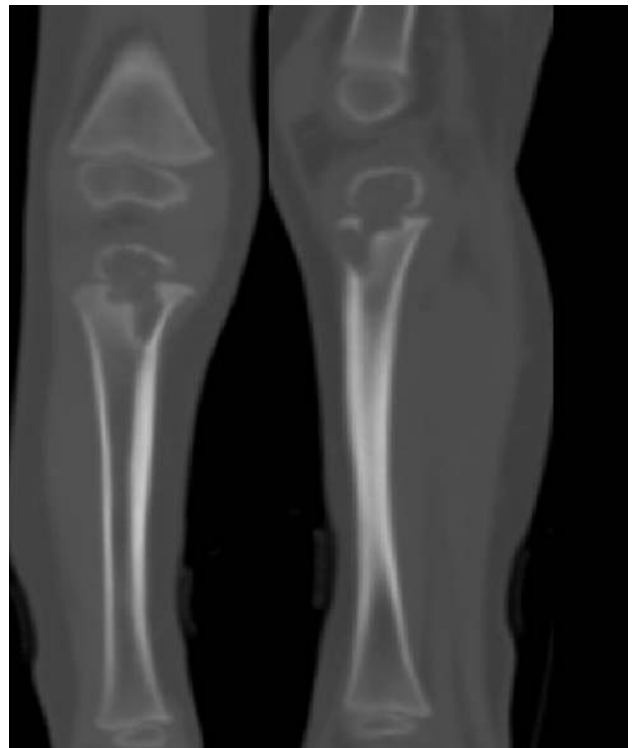Very few cases with proximal tibial tuberculous osteomyelitis involving the epiphysis have been presented in the literature. Hayes described proximal tibial involvement of tuberculosis in two infants with cystic lesions.<sup>[10]</sup> Vangorder reported no or little inflammatory reaction to the bone abscess by either the periosteum or the adjacent bone lamellae when the metaphyseal portion of the long bones was involved.<sup>[11]</sup> Radiographs of our cases were similar with those reported before. Osteolytic lesions were located at both the metaphyseal and the epiphyseal regions. Metaphyseal osteolytic lesions were located in areas of major involvement and are therefore hypothesized to be the origin. Transphyseal expansion is a characteristic sign of tuberculosis but is not pathognomonic.<sup>(10)</sup> Osteolytic lesions of this region are similar in both tuberculosis and subacute osteomyelitis.<sup>[12]</sup>

The diagnosis of osteoarticular tuberculosis is confirmed by isolation of *Mycobacterium tuberculosis* from



**Fig. 5.** (a, b) Fat-suppressed T2-weighted sequence scan of the proximal tibia revealing metaphyseal and epiphyseal lesions.

the bone.<sup>[1-3,11-14]</sup> Identification of *Mycobacterium tuberculosis* with culture is a lengthy process, causing delay in the accurate diagnosis. Chen et al. reported an average delay in the diagnosis of tuberculous osteomyelitis of 6.6 months.<sup>[14]</sup> Due to clinical presentation, these cases should be evaluated and diagnosed on an emergency basis. Tru-cut biopsy and histopathological evaluation are more useful for early diagnosis.<sup>[3,4]</sup> Histologically, the existence of a necrotizing granulomatous inflam-



**Fig. 6.** Lesions disrupting the growth plate at CT scan.

mation is pathognomonic for tuberculosis infection.<sup>[12]</sup> Therefore, tru-cut biopsy was our first choice for diagnosis.

The tuberculosis osteomyelitis cases presented above were treated with debridement and antibiotherapy.<sup>[4,10,12,14]</sup> Successful clinical results were reported, although the surgical procedure of abscess drainage was the most destructive for the epiphysis. No retrospective randomized series supporting antibiotherapy without drainage for the treatment of tuberculous osteomyelitis exist.<sup>[4]</sup> Our cases were diagnosed before debridement and treated with antibiotherapy without drainage or debridement. Antibiotherapy was continued for at least one year. Symptoms and radiological pathology were resolved successfully in both patients.

In conclusion, although accepted to be nearly eradicated in most countries, such cases should remind orthopaedic surgeons to consider tuberculous osteomyelitis in the differential diagnosis of proximal tibial infections in children.

**Conflicts of Interest:** No conflicts declared.

## References

1. Teo HE, Peh WC. Skeletal tuberculosis in children. *Pediatr Radiol* 2004;34:853-60.
2. Rasool MN, Govender S, Naidoo KS. Cystic tuberculosis of bone in children. *J Bone Joint Surg Br* 1994;76:113-7.
3. Watts HG, Lifeso RM. Tuberculosis of bones and joints. *J Bone Joint Surg Am* 1996;78:288-98.
4. Eren A, Atay EF, Omeroğlu H, Altıntaş F. Solitary cystic tuberculosis of long tubular bones in children. *J Pediatr Orthop B* 2003;12:72-5.
5. Martini M, Adjrad A, Boudjemaa A. Tuberculous osteomyelitis. A review of 125 cases. *Int Orthop* 1986;10:201-7.
6. Kahn DS, Pritzker KP. The pathophysiology of bone infection. *Clin Orthop Relat Res* 1973;(96):12-9.
7. Rasool MN. Primary subacute haematogenous osteomyelitis in children. *J Bone Joint Surg Br* 2001;83:93-8.
8. Roberts JM, Drummond DS, Breed AL. Subacute hematogenous osteomyelitis in children: a retrospective study. *J Pediatr Orthop* 1982;2:249-54.
9. Ross ER, Cole WG. Treatment of subacute osteomyelitis in childhood. *J Bone Joint Surg Br* 1985;67:443-8.
10. Hayes JT. Cystic tuberculosis of the proximal tibial metaphysis with associated involvement of the epiphysis and epiphyseal plate: a report of two cases. *J Bone Joint Surg Am* 1961;43:560-7.
11. Vangorder GW. Tuberculosis of the shaft of long bones. A report of six cases. *J Bone Joint Surg Am* 1934;16:269-83.
12. Vohra, R, Kang HS, Dogra S, Saggar RR, Sharma R. Tuberculous osteomyelitis. *J Bone Joint Surg Br* 1997;79:562-6.
13. Rigaud M, Borkowsky W. Tuberculosis in children. In: Rom WN, Garay SM, Bloom BR, eds. *Tuberculosis*. 2nd ed. Philadelphia, PA: Lippincott Williams & Wilkins; 2004. p. 609-24.
14. Chen SC, Huang SC, Wu CT. Nonspinal tuberculous osteomyelitis in children. *J Formos Med Assoc* 1998;97:26-31.