



## Efficacy of sonographically guided intra-flexoral sheath corticosteroid injection in the treatment of trigger thumb

Mohsen MARDANI-KIVI<sup>1</sup>, Farivar Abdullahzadeh LAHIJI<sup>2</sup>, Ali Babaei JANDAGHI<sup>3</sup>,  
Khashayar SAHEB-EKHTIARI<sup>4</sup>, Keyvan HASHEMI-MOTLAGH<sup>4</sup>

<sup>1</sup>Department of Orthopedics, Guilan University of Medical Sciences, Rasht, Iran;

<sup>2</sup>Department of Orthopedics, Shabid Beheshti University of Medical Sciences, Tebran, Iran;

<sup>3</sup>Department of Radiology, Guilan University of Medical Sciences, Rasht, Iran;

<sup>4</sup>Orthopedics Research Center, Guilan University of Medical Sciences, Rasht, Iran

**Objective:** The aim of this study was to determine the efficacy of sonographically guided intra-flexoral sheath corticosteroid injection in the treatment of trigger thumb.

**Methods:** This study included 112 trigger thumbs of 104 patients (7 males, 97 females; mean age: 52.11 years) studied prospectively from 2009 to 2011. All patients experienced pain, tenderness, discomfort and/or triggering with flexion/extension of the thumb and palpable nodules at the level of the A1 pulley. Ultrasonographically guided corticosteroid injection was performed on all affected thumbs. Thumb improvement was evaluated using the Quinnell grading system and patients were followed up for one year.

**Results:** All 112 thumbs received one ultrasonographically guided corticosteroid injection. Fifteen thumbs (13.4%) needed re-injection and/or surgery during their one year follow-up. Eight (53.3%) of these 15 cases, had a pre-treatment Quinnell Grade of 4, six (40%) thumbs were Grade 3 and one (6.7%) was Grade 2. Twelve were re-injected, two underwent surgery without re-injection and one underwent surgery after showing no improvement following re-injection. There was a significant reduction in the post-injection Quinnell grade ( $p < 0.0001$ ). One year after the initial injection, 108 thumbs (96.4%) were completely symptom-free.

**Conclusion:** Sonographically guided intra-flexoral sheath corticosteroid injection is an effective method in the treatment of trigger thumb and reduces the need for surgery.

**Key words:** Corticosteroid injection; tenosynovitis; therapeutic; trigger thumb; ultrasound.

Trigger finger/thumb is one of the most prevalent causes of hand disability and is a common cause of referral to orthopedic clinics.<sup>[1-3]</sup> It is more common among women,<sup>[1,3-6]</sup> with the thumb having the highest involvement.<sup>[1,6,7]</sup> Symptoms include snapping, locking,

rigidity, a click, difficulty in opening the flexed finger and pain caused by inflammation and progressive hypertrophy of the finger or thumb flexor tendon sheath at the level of the A1 pulley.<sup>[8-13]</sup> The first line of treatment are conservative methods, such as finger

**Correspondence:** Mohsen Mardani-Kivi, MD. Guilan University of Medical Sciences, Namjoo Avenue, Rasht, Iran, PO Box: 4193713191.

Tel: +98-131 - 323 98 42 e-mail: dr\_mohsen\_mardani@yahoo.com

**Submitted:** December 3, 2011 **Accepted:** April 4, 2012

©2012 Turkish Association of Orthopaedics and Traumatology

Available online at  
www.aott.org.tr  
doi:10.3944/AOTT.2012.2787  
QR (Quick Response) Code:



rests with or without the use of a splint and a local corticosteroid injection.<sup>[1,14-16]</sup> Surgical treatments are invasive and have potential complications. Although good results with surgical treatment are possible in children over one year of age,<sup>[17]</sup> surgery is only indicated if non-surgical treatments fails in adults.<sup>[7,14,18]</sup>

Intra-flexoral corticosteroid injection is the most common non-surgical treatment with a reported success rate between 38 and 93% for the treatment of trigger thumb.<sup>[1,6,19,20]</sup> Recently, studies have questioned the accuracy and precision of intra-sheath blind corticosteroid injection and its effect on the treatment success rate.<sup>[1]</sup> A recent study explored the intra-sheath delivery of corticosteroids using a blind injection of methylene blue and corticosteroid into the sheath before open surgery in the treatment of trigger thumb. They observed that the contrast medium was successfully injected into the flexoral sheath in only half of the blind injections and was clinically manifested as an increase in the duration of symptoms in this sub-group of patients.<sup>[21]</sup> In addition, reports have been issued about hazardous consequences of blind injection of corticosteroids.<sup>[22,23]</sup> Lee et al. performed a study comparing 20 ultrasound-guided injections and 20 blind injections and reported successful intra-sheath injection in 70% of the group with ultrasound-guided injections and only in 15% in the group receiving blind injections.<sup>[24]</sup> Therefore, the aim of this study was to study the therapeutic outcomes and complications of ultrasound-guided intra-flexoral sheath injection.

## Patients and methods

This descriptive, prospective study reviewed all patients referred to our orthopedic clinic for trigger thumb between March 2009 and March 2011. Inclusion criteria were pain and tenderness at the position of A1 pulley, pain and discomfort when flexing and extending the finger, nodule palpation, presence of a clicking sound at the time of flexion or extension of the thumb, snapping or locking of finger, and the existence of a trigger state. Patients with any kind of concomitant local tenosynovitis such as De Quervain's dis-

ease, carpal tunnel syndrome and Dupuytren's contracture, involvement of other fingers, clinical doubt as to the true nature of the symptoms or any history of local corticosteroid injection were excluded. Additionally, patients undergoing ultrasound-guided intra-flexoral sheath injection treatment in the first three months were excluded. One hundred and twelve thumbs of 104 patients (7 men, 97 women; mean age: 52.11±7.63 years; range: 26 to 69 years) were included in the study (Fig. 1).

The affected side was right in 64 patients, left in 32 and bilateral in 8. Trigger thumb was seen in the dominant hand in 89 of 112 thumbs (79.5%) and in the non-dominant hand in 23 (20.5%). Patients were graded according to Quinnell's grading classification (Table 1). Of the 104 patients, 28 (26.9%) had concomitant medical conditions (Table 2). Symptoms were present for less than six months (<6 months group) in 107 thumbs (95.5%) and more than 6 months (>6 month group) in 5 thumbs (4.5%).

**Table 1.** Quinnell's grading system.

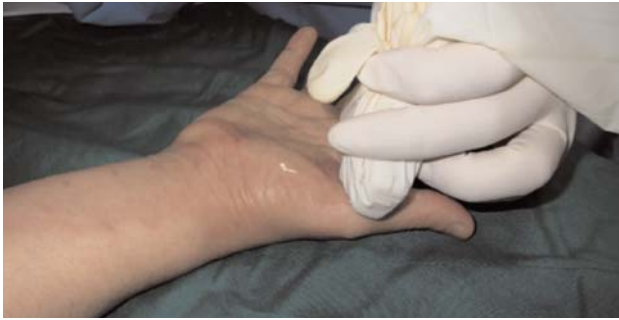Grade	Explanation
1	Without trigger state, uneven finger movement or slight crepitation
2	Trigger state, finger snapping that is corrected actively
3	Trigger state, finger snapping that is corrected passively
4	Finger locking, uncorrectable

Previous studies have showed increased success rates with the insertion of a 25-gauge needle in a proximal to distal direction at an angle of 30-45° angle from the volar side into the anatomic position of the A1 pulley.<sup>[4,21,25]</sup> We performed the same procedure using 1 ml of 40 mg/ml methyl prednisolone acetate and 0.5 ml of 2% lidocaine hydrochloride in all patients. All examinations, diagnosis, injections, investigation of therapeutic outcomes and re-injections or operations, if needed, were performed by the corresponding author. Ultrasound guidance was

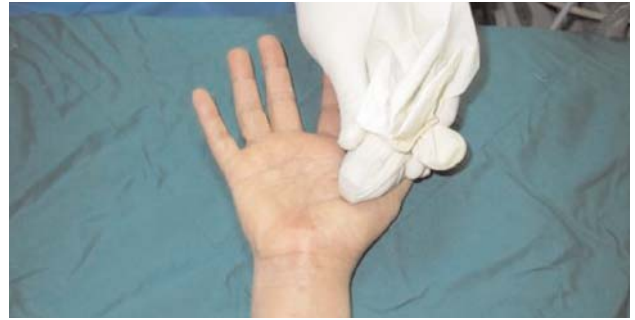**Table 2.** The frequency of concomitant medical conditions in the population of the patients of this study.

Type of synchronous disease	Number of patients*	Frequency in persons having concomitant medical conditions	Frequency in all patients
Diabetes mellitus	20	71.4%	19.2%
Hypothyroidism	7	25%	6.7%
Rheumatoid arthritis	3	10.7%	2.9%

\*One patient was simultaneously afflicted with diabetes mellitus and rheumatoid arthritis and one patient had diabetes mellitus and hypothyroid simultaneously.



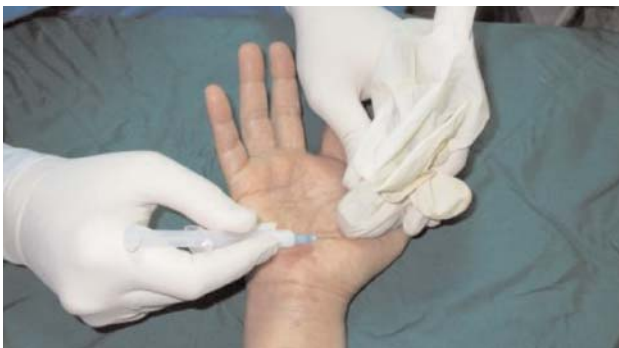**Fig. 1.** Setting the probe to find the tendon in axial view. [Color figure can be viewed in the online issue, which is available at [www.aott.org.tr](http://www.aott.org.tr)]



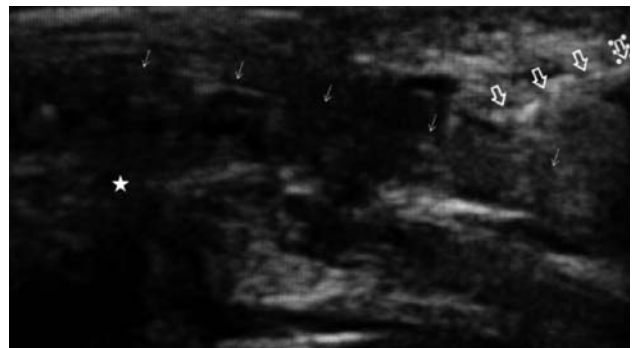
**Fig. 2.** Rotating the probe to find the tendon in longitudinal view. [Color figure can be viewed in the online issue, which is available at [www.aott.org.tr](http://www.aott.org.tr)]

performed using a 14 MHz linear probe (Ultrasonix, Touch model, ver. 5.5.4). First, the tendon was detected through an axial scan of the proximal phalanx (Fig. 2) and the probe was rotated until a fibrillary echo pattern was visualized and adjusted in the screen center. Next, the probe was moved proximally to the first MCP joint and the first annular pulley appeared (Fig. 3). The

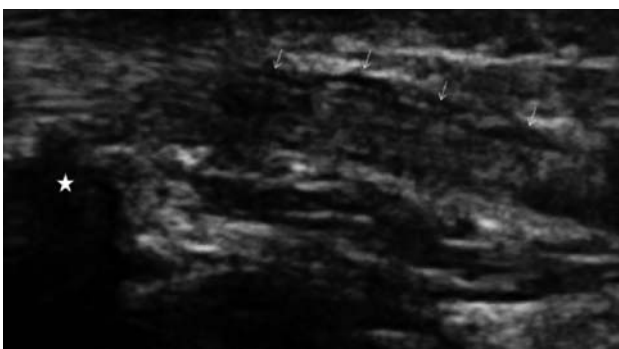
needle was inserted into the space between the A1 pulley and flexor pollicis longus at a 30 to 45° angle oriented proximal to distal and the solution injected (Fig. 4). Distension of the tendon sheath and the resultant fluid wave inside from the finger tip to the injection site were confirmed during the injection process (Figs. 5-7).



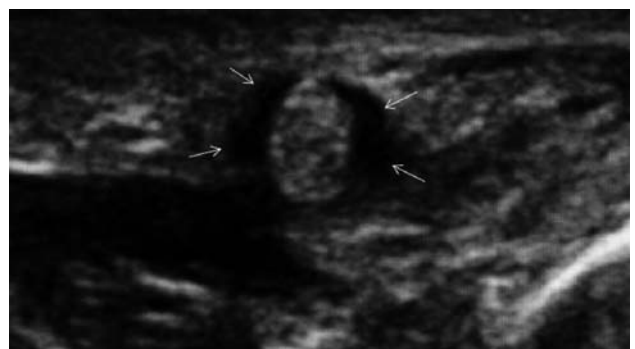
**Fig. 3.** Inserting the needle at 30-45° angle. [Color figure can be viewed in the online issue, which is available at [www.aott.org.tr](http://www.aott.org.tr)]



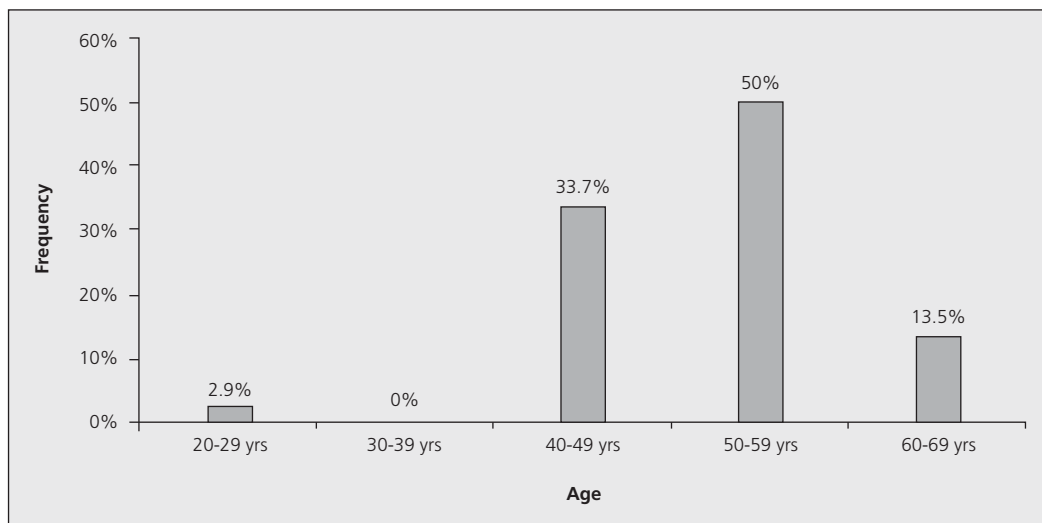
**Fig. 4.** Longitudinal view of needle's entrance (Hollow arrows: needle, solid arrows: tendon, star: the first metacarpophalangeal joint).



**Fig. 5.** Longitudinal view of tendon after corticosteroid injection (Arrows: confluence of liquid inside sheath around tendon, star: the first metacarpophalangeal joint).



**Fig. 6.** Axial view of the tendon after corticosteroid injection (Arrows: fluid collection inside sheath around tendon).



**Fig. 7.** Age distribution of the patients.

Patients were followed-up at 3 and 6 weeks, 3 and 6 months and 1 year after the first injection. Of the original 117 patients, 13 were excluded from the study because of failed follow-up. The Quinnell's criterion was applied to evaluate improvements during follow-up. Patients were observed for 6 weeks and further treatment (re-injection or surgery) was suggested to patients and performed depending on patient preference. In addition, patients who were still symptomatic after 2 injections became candidates for open surgery.

Collected data was saved separately into two therapeutic groups and was statistically analyzed using SPSS software package for Windows v.19.0 (SPSS Inc., Chicago, IL, USA). After summarizing the characteristics of both groups with descriptive statistics, response variables were evaluated according to the Kolmogorov-Smirnov test and it was shown that none had a normal distribution. The Mann-Whitney U test was used in order to compare these variables of both groups and the chi-squared test to compare the differ-

ences of qualitative parameters between groups. To analyze the trend of Quinnell's grade changes, repeated measure analysis test through Mauchly's test of sphericity was employed, and to evaluate the value of these changes, analysis of variance (ANOVA) was performed. In all statistical tests, the p value was set at 0.05.

## Results

Symptoms were completely ameliorated after one injection in 86.6% of thumbs. These patients had no relapse. At the one year follow-up, 15 thumbs (13.4%) needed reinjection and/or surgery. Of these 15 thumbs, 12 (80%) were re-injected, 2 (13.3%) underwent surgery without re-injection, and one (6.7%) was re-injected and underwent subsequent surgery. No thumb was injected more than two times. Of the 13 reinjection cases, only one case (7.7%) needed surgery. After one year (6th visit), 109 thumbs (97.3%) were symptom-free and only one thumb was at Quinnell's

**Table 3.** Frequency distribution and the mean of Quinnell's grade of fingers in performed visits.

Turn of visit	Without symptom	Grade 1	Grade 2	Grade 3	Grade 4	Mean±SD of grade
	Number (%)	Number (%)	Number (%)	Number (%)	Number (%)	
First	0 (0)	3 (2.7)	56 (50)	33 (29.5)	20 (17.9)	2.61±0.81
Second	105 (93.8)	5 (5.4)	1 (0.9)	0 (0)	1 (0.9)	0.10±0.46
Third	102 (91.1)	7 (6.3)	1 (0.9)	1 (0.9)	1 (0.9)	0.14±0.55
Fourth	103 (92)	7 (6.3)	1 (0.9)	1 (0.9)	0 (0)	0.11±0.41
Fifth	106 (94.6)	3 (2.7)	3 (2.7)	0 (0)	0 (0)	0.08±0.36
Sixth	111 (99.1)	1 (0.9)	0 (0)	0 (0)	0 (0)	0.01±0.09

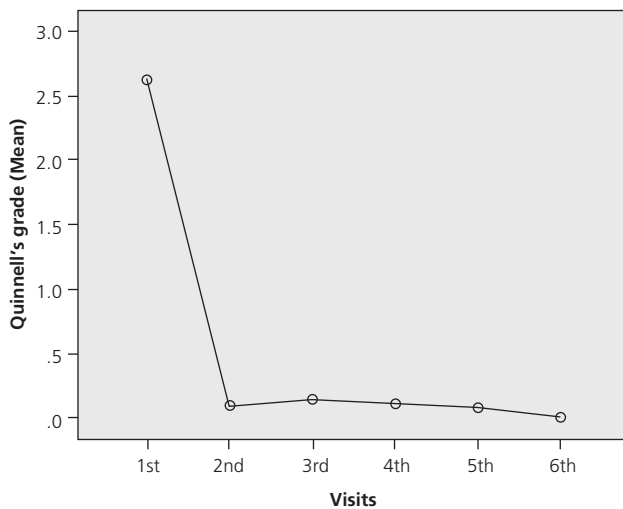


Fig. 8. Overall Quinnell's grade in visits.

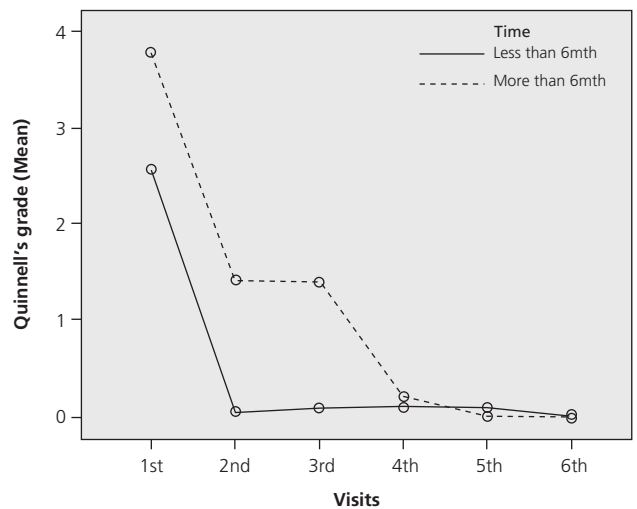


Fig. 9. Quinnell's grade in two groups of less and more than 6 months.

Grade 1. Due to this patient's unwillingness, reinjection or surgery was not performed.

Quinnell's grading for thumbs from the first to sixth visits is shown in Table 3. Statistical analysis revealed that the trend and value of variations of Quinnell's grade are statistically significant for all thumbs ( $p < 0.0001$ ) (Fig. 8). In addition, trend and value of variations of Quinnell's grade was statistically significant between the over and under 6 month symptom groups ( $p < 0.0001$ ) (Fig. 9). There was no significant difference in trend and value of variations of the Quinnell's grade between diabetic and non-diabetic patients ( $p = 0.85$  and  $p = 0.63$ , respectively). Quinnell's grades of these two groups are given in Fig. 10. Complications were not seen in any patient.

### Discussion

The effect of corticosteroid injections in the treatment of stenosing tenosynovitis is a contentious issue in orthopedics. Despite studies for more than a quarter century, the role of corticosteroid injections into the flexor tendon's sheath and the importance of intra-sheath delivery in the treatment of trigger finger and thumb has been questioned.<sup>[1,19,21,26]</sup> In the present study, 109 of 112 thumbs (97.3%) were completely symptom-free one year post-injection. This rate is higher than the reported success rates of 38 to 93% in previous studies.<sup>[1,16,19,20]</sup> Those studies with a varying range of success rates relied on blind injection for the corticosteroid delivery, while those with higher success rates, including the present study, were attained with the aid

of sonographic guidance. The inaccuracy associated with blind injection appears to be responsible for the decrease in success rates seen in intra-sheath delivery of corticosteroids.<sup>[21,24]</sup>

The relationship between the existence of one or more concomitant medical conditions and the efficacy of corticosteroid injection has also been scrutinized.<sup>[6,14,19,27-29]</sup> Many authors, including Blythe and Ross, regarded trigger thumb as a part of what they called "diabetic hand syndrome".<sup>[28]</sup> Since there were a limited number of patients with both hypothyroidism (6.7%) and rheumatoid arthritis (2.9%) in this study, we chose

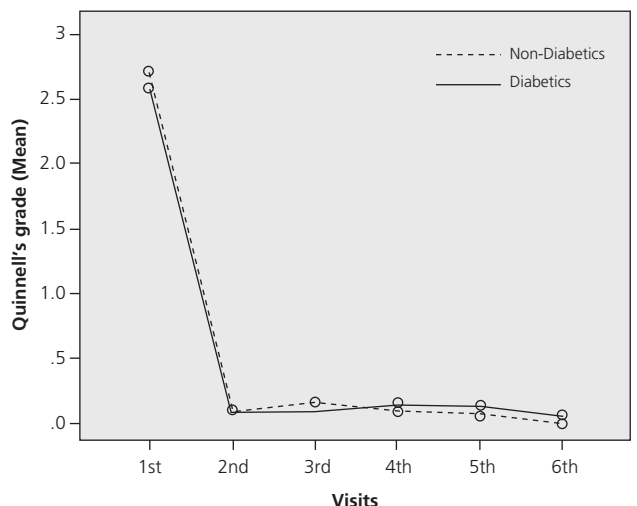


Fig. 10. Quinnell's grade in two groups of diabetic and non-diabetic patients.



to discuss diabetic patients, as it is very common in our patient population. In several previous studies,<sup>[2,19,29]</sup> diabetic patients showed less therapeutic response than non-diabetic individuals and required surgical treatment more often. In a study of 54 diabetic patients with 121 trigger thumbs over a 3 year follow-up, Griggs et al.<sup>[27]</sup> reported that symptoms were completely ameliorated in 34 fingers (28%) after the first injection, and this number increased by an additional 27 fingers (22%) after the second and third injections. Sixty fingers (50%) improved slightly and required surgery to release the A1 pulley. In the present study, although a higher percentage of diabetic thumbs opposed to non-diabetic thumbs (30.8% and 18.2%, respectively) required reinjection, this difference was not statistically significant ( $p=0.28$ ). This indicates that diabetic patients benefit from ultrasound-guided intra-flexoral injection as much as non-diabetic patients.

Limitations of sonographically guided intra-flexoral injection are the limited availability of sonography and the need for skillful radiologists for ultrasound guidance, which cause significantly more costs compared to the blind method. However, the reduction in the need for surgery and the remarkable increase in the speed and rate of symptom amelioration results in a reduction in health care costs and the financial burden arising from patients' disability.

This study was conducted on the thumb only. With the exception of a limited number of case studies,<sup>[2]</sup> most studies have been conducted on trigger fingers (thumbs and fingers) and the fact that this study is limited to the thumb makes it difficult to compare and generalize its results to other fingers. On the other hand, the present study included a large sample volume of thumbs that is rare. Further studies that consider the efficacy of the same method in other fingers with a larger volume of samples are recommended.

In conclusion, sonographically guided corticosteroid injection into the sheath of the flexor tendon of the thumb appears to be a highly useful in the treatment of trigger thumb and decreases the need for surgery, especially in patients who with a symptom duration of less than six months.

**Conflicts of Interest:** No conflicts declared.

## References

- Akhtar S, Bradley MJ, Quinton DN, Burke FD. Management and referral for trigger finger/thumb. *BMJ* 2005;331:30-3.
- Howitt S, Wong J, Zabukovec S. The conservative treatment of Trigger Thumb using Graston Techniques and Active Release Techniques. *J Can Chiropr Assoc* 2006;50:249-54.
- Flatt AE. Notta's nodules and trigger digits. *Proc (Bayl Univ Med Cent)* 2007;20:143-5.
- Creighton JJ Jr, Idler RS, Strickland JW. Trigger finger and thumb. *Indiana Med* 1990;83:260-2.
- Ger E, Kupcha P, Ger D. The management of trigger thumb in children. *J Hand Surg Am* 1991;16:944-7.
- Moore JS. Flexor tendon entrapment of the digits (trigger finger and trigger thumb). *J Occup Environ Med* 2000;42:526-45.
- Lange-Riess D, Schuh R, Hönle W, Schuh A. Long-term results of surgical release of trigger finger and trigger thumb in adults. *Arch Orthop Trauma Surg* 2009;129:1617-9.
- Newport ML, Lane LB, Stuchin SA. Treatment of trigger finger by steroid injection. *J Hand Surg Am* 1990;15:748-50.
- Sampson SP, Badalamente MA, Hurst LC, Seidman J. Pathobiology of the human A1 pulley in trigger finger. *J Hand Surg Am* 1991;16:714-21.
- Doyle JR. Anatomy of the finger flexor tendon sheath and pulley system: a current review. *J Hand Surg Am* 1989;14:349-51.
- Hume EL, Hutchinson DT, Jaeger SA, Hunter JM. Biomechanics of pulley reconstruction. *J Hand Surg Am* 1991;16:722-30.
- Moutet F. Flexor tendon pulley system: anatomy, pathology, treatment. [Article in French] *Chir Main* 2003;22:1-12.
- Bayat A, Shaaban H, Giakas G, Lees VC. The pulley system of the thumb: anatomic and biomechanical study. *J Hand Surg Am* 2002;27:628-35.
- Makkouk AH, Oetgen ME, Swigart CR, Dodds SD. Trigger finger: etiology, evaluation, and treatment. *Curr Rev Musculoskelet Med* 2008;1:92-6.
- Colbourn J, Heath N, Manary S, Pacifico D. Effectiveness of splinting for the treatment of trigger finger. *J Hand Ther* 2008;21:336-43.
- Maneerit J, Sriworakun C, Budhrajana N, Nagavajara PN. Trigger thumb: results of a prospective randomised study of percutaneous release with steroid injection versus steroid injection alone. *J Hand Surg Br* 2003;28:586-9.
- Sevencan A, Inan U, Köse N, Omeroglu H, Seber S. Percutaneous release for trigger thumb in children: improvements of the technique and results of 31 thumbs. *J Pediatr Orthop* 2010;30:705-9.
- Cebesoy O, Kose KC, Baltaci ET, Isik M. Percutaneous release of the trigger thumb: is it safe, cheap and effective? *Int Orthop* 2007;31:345-9.
- Nimigan AS, Ross DC, Gan BS. Steroid injections in the management of trigger fingers. *Am J Phys Med Rehabil* 2006;85:36-43.
- Lambert M, Morton RJ, Sloan JP. Controlled study of the use of local steroid injection in the treatment of trigger finger and thumb. *J Hand Surg Br* 1992;17:69-70.
- Kamhin M, Engel J, Heim M. The fate of injected trigger fingers. *Hand* 1983;15:218-20.
- Fitzgerald BT, Hofmeister EP, Fan RA, Thompson MA. Delayed flexor digitorum superficialis and profundus ruptures in a trigger finger after a steroid injection: a case report. *J Hand Surg Am* 2005;30:479-82.

23. Park J, Dumanian GA. Shower emboli and digital necrosis after a single corticosteroid injection for trigger thumb: case report. *J Hand Surg Am* 2009;34:313-6.
24. Lee DH, Han SB, Park JW, Lee SH, Kim KW, Jeong WK. Sonographically guided tendon sheath injections are more accurate than blind injections: implications for trigger finger treatment. *J Ultrasound Med* 2011;30:197-203.
25. Zare-zadeh A, Samavarchi Tehrani M, Noorian V, Padidar B. Efficacy of local corticosteroid injection in trigger finger treatment. [Article in Persian] *Journal of Arak University of Medical Sciences* 2007;9:1-6.
26. Taras JS, Raphael JS, Pan WT, Movagharnia F, Sotereanos DG. Corticosteroid injections for trigger digits: is intrasheath injection necessary? *J Hand Surg Am* 1998;23:717-22.
27. Griggs SM, Weiss AP, Lane LB, Schwenker C, Akelman E, Sachar K. Treatment of trigger finger in patients with diabetes mellitus. *J Hand Surg Am* 1995;20:787-9.
28. Blythe MJ, Ross DJ. Diabetes and trigger finger. *J Hand Surg Br* 1996;21:244-5.
29. Arkkila PE, Gautier JF. Musculoskeletal disorders in diabetes mellitus: an update. *Best Pract Res Clin Rheumatol* 2003;17:945-70.