



Sonographic assessment of transverse carpal ligament after open surgical release of the carpal tunnel

Nuri KARABAY¹, Murat KAYALAR², Sait ADA²

¹Department of Radiology, Hand Microsurgery Orthopaedics and Traumatology (EMOT) Hospital, İzmir, Turkey;

²Department of Orthopedics and Traumatology, Hand Microsurgery Orthopaedics and Traumatology (EMOT) Hospital, İzmir, Turkey

Objective: The aim of this study was to sonographically evaluate the anatomy of the transverse carpal ligament (TCL) after open surgical release in the treatment of carpal tunnel syndrome (CTS) and to establish new ultrasonographic criteria for the completeness of TCL release.

Methods: Thirty-six patients who underwent open surgical release for CTS were recruited prospectively. Patients were evaluated with physical examination and ultrasonography before and after the operation.

Results: All patients' symptoms resolved after surgery. TCL was found to be diffusely thickened and to have lost its smooth form after surgery. Postoperative TCL thickness showed a statistically significant increase when compared with preoperative values ($p<0.05$).

Conclusion: Sonography is a capable imaging method for assessment of the TCL after open release surgery. In addition, ultrasound may be considered as a complementary tool to exclude diagnosis of incomplete transection of TCL in patients with persistent symptoms.

Key words: Carpal tunnel syndrome; sonography; transverse carpal ligament; ultrasound.

Carpal tunnel syndrome (CTS) is the most frequent compressive neuropathy of the upper limb, affecting 1% of the population.^[1,2] It's characterized by pain and paresthesia affecting the median nerve (MN) territory. While imaging methods play a limited role in the diagnosis of CTS, electrodiagnostic testing in combination with a thorough physical examination is the gold standard of CTS diagnosis.^[1,3]

Conservative treatments for CTS include wrist brace or splint, resting the affected hand, work environment modification and anti-inflammatory medication and local steroid injection.^[1,4] Surgery is recom-

mended when conservative treatment fails. Multiple surgical techniques have been defined for carpal tunnel release surgery, including traditional open release, limited incision open release, limited incision device-assisted release and endoscopic release.^[5-7] Approximately 70 to 90% of patients have good to excellent long-term outcome with open carpal tunnel release.^[2] The use of less invasive techniques, such as endoscopic and limited incision release that avoid hypertrophic scar formation and scar hypersensitivity have gradually increased. However, these less invasive techniques may result in an incomplete release of the transverse carpal ligament (TCL) because of the limit-

Correspondence: Nuri Karabay, MD. El Mikrocerrahi Ortopedi ve Travmatoloji Hastanesi (EMOT) 1418 Sok. No: 14, 35230 Kahramanlar, Izmir, Turkey.

Tel: +90-532 - 771 0554 e-mail: nurikarabay@gmail.com

Submitted: April 17, 2012 **Accepted:** December 11, 2012

©2013 Turkish Association of Orthopaedics and Traumatology

Available online at
www.aott.org.tr
doi:10.3944/AOTT.2013.2890
QR (Quick Response) Code:



ed exposure of the TCL. Incomplete transection can lead to persistent CTS symptoms.^[5]

Sonography has been shown to be effective in the diagnosis of CTS and in the detection of the change in the cross-sectional area of the MN after surgical release.^[8-13] However, postoperative changes in the TCL after open surgical release have not been established. Additionally, it has not been investigated whether ultrasound (US) is a helpful tool in determining the incomplete sectioning of the TCL and can be used to exclude the diagnosis of incomplete sectioning of the TCL in patients with persistent symptoms after CTS surgery.

The aim of this study was to sonographically evaluate the anatomy of the TCL after open surgical release and to establish new sonographic criteria for the completeness of the TCL release.

Materials and methods

This prospective study included 36 consecutive patients (29 women, 7 men; mean age: 55.6 years; range: 30 to 75 years) with moderate to severe idiopathic CTS.

Institutional Review Board approval was obtained for this study. Informed consent was provided by all participants prior to examinations.

Moderate to severe sensory and motor impairment of the MN was confirmed with electrodiagnostic testing in all patients. Patients with polyneuropathy or cervical neuropathy, previous hand surgery, wrist fracture, space-occupying lesions within the carpal tunnel or anatomical wrist variants, such as bifid MN and persistent median artery, were eliminated from the study.

All patients underwent open surgical release of the carpal tunnel with a conventional long skin incision was made at the intersection of Kaplan's cardinal line and the third web space line to visualize the entire length of the TCL.^[1]

Sonographic evaluations were performed preoperatively and at the 2nd, 4th and 6th weeks after surgery, between January and December 2010. Siemens Antares scanner (Siemens AG, Erlangen, Germany) and a 9 to 12 MHz linear array transducer were used by the same radiologist with seven years of experience. All wrists were examined in the neutral position with the palm up and the fingers semi-extended.

Sonographic examination included both longitudinal and transverse axis sonograms of the carpal tunnel and began with a longitudinal sonogram which was used to identify the MN. Transverse sonograms of the

MN were performed at the proximal carpal tunnel inlet. Two bony landmarks were used; the pisiform bone on ulnar side and scaphoid bone on radial side, which were described by Klauser et al. previously.^[10] These hypoechoic bony structures, which can easily be recognized using US, served as landmarks for the measurements.

Transverse sonograms were used to measure the cross-sectional area of the MN and TCL thickness at its thickest, most regular and uniform site. Pre- and postoperative measurements were performed at the same location using bony markers (scaphoid-pisiform level). Cross-sectional area of the MN, related with CTS was also measured at the scaphoid-pisiform level.^[10] We used the direct technique, tracing a continuous line around the inner hyperechoic rim of the MN with an electronic cursor. Measurements were taken two times and the mean values used.

In the first postoperative examination (2nd week follow-up), TLC division was evaluated via direct visualization of the gap in the TCL and the distance measured. The gap is defined as a focal anechoic discontinuity in the ligament. TCL thickness and cross-sectional area of the MN were also measured. At the 4th and 6th week follow-up, only TCL thickness and cross-sectional area of the MN were measured.

Repeated measures analysis of variance (ANOVA) was applied to compare reproducibility across various measurements, i.e. before and 2, 4 and 6 weeks after surgery. Level of significance was defined as $p < 0.05$.

Results

All patients reported a postoperative decrease in their complaints.

Preoperative TCL was seen as a thin (mean thickness was 0.73 mm), uniform/smooth hypoechogenic ligamentous structure on US images (Fig. 1a). There was no wavy contour or nodular appearances in the ligament. In the first postoperative US exam (2nd week follow-up) the sectioned TCL was easily recognized in all cases as a hypoechoic defect due to fluid accumulation (Fig. 1b). The mean length of the gap in the TCL was 3.45 (range: 2.00 to 5.52) mm. This hypoechoic defect was not clearly visible during the next follow-ups. The TCL lost its smooth form after surgery and became diffusely thickened with a wavy contour. Mean TCL thickness was 1.32, 1.48 and 1.54 mm at the 2nd, 4th and 6th weeks, respectively (Fig. 1c).

Pre- and postoperative US findings for cross-sectional areas of the MN and TCL thickness are listed in

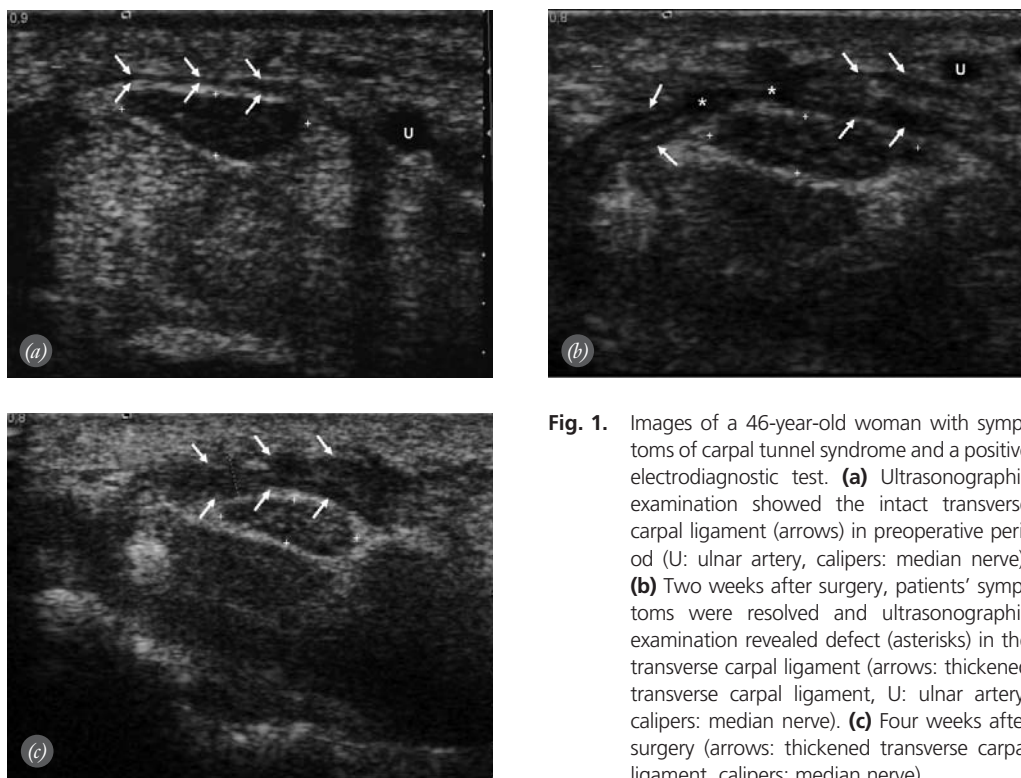


Fig. 1. Images of a 46-year-old woman with symptoms of carpal tunnel syndrome and a positive electrodiagnostic test. **(a)** Ultrasonographic examination showed the intact transverse carpal ligament (arrows) in preoperative period (U: ulnar artery, calipers: median nerve). **(b)** Two weeks after surgery, patients' symptoms were resolved and ultrasonographic examination revealed defect (asterisks) in the transverse carpal ligament (arrows: thickened transverse carpal ligament, U: ulnar artery, calipers: median nerve). **(c)** Four weeks after surgery (arrows: thickened transverse carpal ligament, calipers: median nerve).

Table 1. There was a statistically significant difference between measurements of pre- and 2, 4, and 6 weeks of postintervention ($p < 0.05$). Cross-sectional areas of the MN significantly decreased in 4 to 6 weeks ($p < 0.05$). Postoperative TCL thickness showed a statistically significant increase when compared with the preoperative period ($p < 0.05$). There was a statistically significant difference between the preoperative and postoperative 2nd week ($p < 0.001$) and between the 2nd and 4th postoperative week findings for the thickness of TCL ($p < 0.005$).

Discussion

Relief of pain and paresthesia and improved sensation are useful in evaluating the outcome of carpal tunnel surgery.^[2,5,14,15] The rate of persistent symptoms following carpal tunnel surgery is between 1 to 25%,^[16,17] with

incomplete transection of the TCL (incidence 1 to 11%) being the most common cause.^[13,16,18] However, there is no reliable and feasible imaging method to demonstrate the sufficient release of carpal tunnel, especially in the early postoperative period. Even after successful carpal tunnel release, electrophysiological tests may remain abnormal for at least 24 months postoperatively. For this reason, electrophysiological testing without clinical knowledge cannot give sufficient information in cases with persistent symptoms.^[5,16,19,20] Ultrasound is painless and can therefore be considered for patients who refuse the electrophysiological test. Additionally, US is an easy access, simple, rapid, and noninvasive imaging technique.

Our sonographic findings suggest that the TCL lost its smooth form and became diffusely thickened with a wavy contour after surgery. Taking into consid-

Table 1. Preoperative and postoperative ultrasonographic findings.

| | Preoperative | Postoperative | | |
|--|--------------|-----------------|-----------------|-----------------|
| | Mean±SD | 2 weeks Mean±SD | 4 weeks Mean±SD | 6 weeks Mean±SD |
| Mean cross-sectional area of MN (mm ²) | 16.54±4.50 | 15.85±2.68 | 13.95±4.78 | 13.15±4.08 |
| TCL thickness (mm) | 0.73±0.16 | 1.32±0.86 | 1.48±0.58 | 1.54±0.68 |

eration the patient's satisfaction, the surgery could be considered successful when the TCL's thickness was equal or more than 1.32 mm and lost its smooth form. Nevertheless, thickening of the TCL may not always reflect surgery success. Botte et al. defined regrowth of the flexor retinaculum as continuity with thickening of the retinaculum in the region deep to the subcutaneous scar in the postoperative period.^[18] In an MRI study, Wu et al. found that regrowth of the flexor retinaculum was seen with a similar frequency in both symptomatic and asymptomatic patients, suggesting that this sign has limited clinical utility.^[17]

TCL thickness shows little difference in non-operative CTS patients. Sernik et al. reported a statistically significant difference in flexor retinaculum thickness between symptomatic and asymptomatic wrists via US (CTS: 0.88 ± 0.23 mm, control: 0.75 ± 0.1 mm; $p=0.018$).^[21] Similarly, in our study, mean TCL thickness was 0.73 mm in symptomatic wrists. This small difference may be derived from TCL measurement location and technique. However, there was a statistically significant increase in TCL thickness in the postoperative period (≥ 1.32 mm).

Few papers on US imaging of the sectioned TCL have been published. Aydin et al. reported US to be sufficient in the intraoperative evaluation of TCL sectioning.^[22] Similarly, Philippe released five fresh cadavers' carpal tunnel under sonographic control and concluded that US is an effective method to define the line of division of the TCL.^[23] However, these studies did not reveal postsurgical TCL appearances.

Previous studies have shown US to be a reliable and feasible imaging method for the diagnosis of CTS through demonstration of an increase in the cross-sectional area of the MN.^[8,9,12,13] Postoperative US studies have also shown a decrease in the cross-sectional area of the MN.^[8,12] However, these studies demonstrated that the increased cross-sectional area of the MN remains abnormal for a long period of time after surgery. According to Lee et al., the anatomical change of the carpal tunnel could not be seen before six months after surgery and then the changes could only be seen in the anatomy of the carpal tunnel in cases where the MN impairment remained unchanged.^[11] We measured the cross-sectional area of the MN and found the decreased area of the MN was barely seen before 4 to 6 weeks; however, this finding is not a subject of this study.

The persistence of CTS symptoms despite surgical release has been reported in 1 to 25% of patients. Although the possible reasons vary, continued symptoms classically suggest the possibility of an incomplete surgical release of the TCL. The second release of the carpal tunnel has been reported in 12% of all cases with CTS after primary release surgery.^[5,17,18] Others causes of persistent symptoms are fibrous proliferation or scarring, inflammatory flexor tenosynovitis, reformation of the flexor retinaculum and entrapment of the palmar cutaneous branch of the MN, pillar pain, surgery site infection and postoperative skin or palmar fascia necrosis.^[16-18] Infection and soft tissue necrosis are easily recognizable with clinical examination. Pillar pain is one of the most common clinical symptoms and should be considered in patients with persistent symptoms. Although there is a significant group of patients who have postoperative complaints, the etiology of pillar pain remains controversial. Pillar pain is characterized as discomfort at the base of the palm in the thenar or hypothenar area, even if the release surgery is per-

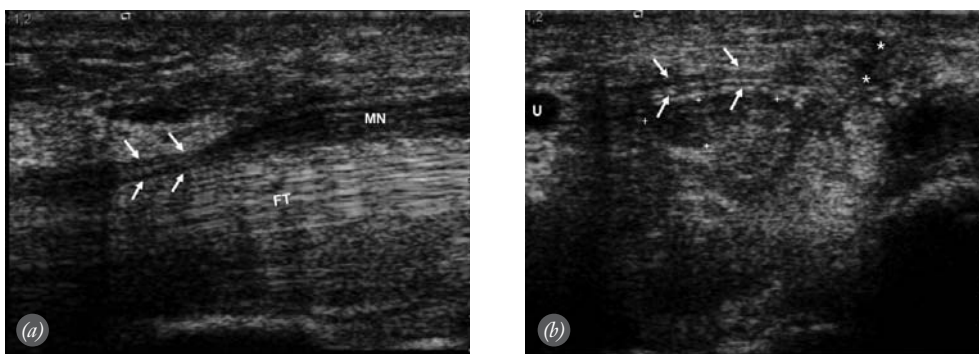


Fig. 2. Images of a 52-year-old woman with symptoms of CTS after surgery. **(a)** Longitudinal axis image showing the compression (arrows) by TCL on the MN (MN: median nerve, FT: flexor tendons). **(b)** Transverse axis image showing the intact TCL (arrows) overlying the MN. Asterisks indicate scar tissue related with previous surgery (calipers: median nerve).

formed technically perfectly. Unfortunately, there are no imaging method and ultrasonographic finding for diagnosis of pillar pain. Similarly, the entrapment of the palmar cutaneous branch of the MN cannot be diagnosed via US.

The US exams were tolerated easily by patients. We used an abundant amount of US transmission gel for good contact and near-field resolution.

Ultrasound can be used to evaluate the TCL in the postoperative period and incomplete release may be considered in cases in which the TCL preserves its smooth and tight appearance with no hypoechoic defect in the ligament on postoperative US examination. In Fig. 2, we present the sonographic image of a case with incomplete release who was not included in our study.

There are some limitations to our study. First, the number of our study cases was smaller than previous studies. Second, the follow-up period was limited to 6 weeks. However, this period was enough to diagnose persistent symptoms, especially in cases where pain and paresthesia continued or remained the same. Another limitation was the lack of inter- and intraobserver correlation for measurements due to the presence of only one attending radiologist in our clinic. Furthermore, a lack of correlation between the US assessment and electrodiagnostic test of postintervention is another limitation of the study. We did not perform postoperative electrophysiological tests as results can remain abnormal for at least 24 months in the postoperative period, even after successful surgery. For this reason, sonographic findings are correlated with the patient's satisfaction. Finally, due to the small study group, TCL thickness data in patients with poor postoperative outcome could not be collected. More US studies are needed in the patients with poor outcome after surgery to determine a clear thickness criterion to verify surgery success. In addition, US is an operator-dependent test that requires sufficient experience to ensure reliability and reproducibility.

In conclusion, ultrasonography can be considered a complementary imaging method for TCL assessment after release surgery and to exclude the diagnosis of incomplete transection of the TCL in patients with persistent symptoms.

Conflicts of Interest: No conflicts declared.

References

1. Canale ST. Carpal tunnel syndrome. In: Daugherty K, Jones L, Terry S, Campbell WC, Canale ST, editors. *Campbell's operative orthopaedics*. St. Louis: Mosby-Year Book; 1998. p. 3685-94.
2. Turner A, Kimble F, Gulyás K, Ball J. Can the outcome of open carpal tunnel release be predicted? A review of the literature. *ANZ J Surg* 2010;80:50-4.
3. Alfonso C, Jann S, Massa R, Torreggiani A. Diagnosis, treatment and follow-up of the carpal tunnel syndrome: a review. *Neurol Sci* 2010;31:243-52.
4. Huisstede BM, Hoogvliet P, Randsdorp MS, Glerum S, van Middelkoop M, Koes BW. Carpal tunnel syndrome. Part I: effectiveness of nonsurgical treatments - a systematic review. *Arch Phys Med Rehabil* 2010;91:981-1004.
5. Dahlin LB, Salö M, Thomsen N, Stütz N. Carpal tunnel syndrome and treatment of recurrent symptoms. *Scand J Plast Reconstr Surg Hand Surg* 2010;44: 4-11.
6. Huisstede BM, Randsdorp MS, Coert JH, Glerum S, van Middelkoop M, Koes BW. Carpal tunnel syndrome. Part II: effectiveness of surgical treatments - a systematic review. *Arch Phys Med Rehabil* 2010;91:1005-24.
7. Shores JT, Lee WP. An evidence-based approach to carpal tunnel syndrome. *Plast Reconstr Surg* 2010;126:2196-204.
8. Abicalaf CA, de Barros N, Sernik RA, Pimentel BF, Braga-Baiak A, Braga L, et al. Ultrasound evaluation of patients with carpal tunnel syndrome before and after endoscopic release of the transverse carpal ligament. *Clin Radiol* 2007; 62:891-6.
9. Beekman R, Visser LH. Sonography in the diagnosis of carpal tunnel syndrome: a critical review of the literature. *Muscle Nerve* 2003;27:26-33.
10. Klausner AS, Halpern EJ, De Zordo T, Feuchtner GM, Arora R, Gruber J, et al. Carpal tunnel syndrome assessment with US: value of additional cross-sectional area measurements of the median nerve in patients versus healthy volunteers. *Radiology* 2009;250:171-7.
11. Lee CH, Kim TK, Yoon ES, Dhong ES. Postoperative morphologic analysis of carpal tunnel syndrome using high-resolution ultrasonography. *Ann Plast Surg* 2005;54:143-6.
12. Smidt MH, Visser LH. Carpal tunnel syndrome: clinical and sonographic follow-up after surgery. *Muscle Nerve* 2008;38:987-91.
13. Wong SM, Griffith JF, Hui AC, Lo SK, Fu M, Wong KS. Carpal tunnel syndrome: diagnostic usefulness of sonography. *Radiology* 2004;232:93-9.
14. Düger T, Yakut E, Öksüz Ç, Yörükhan S, Bilgütay BS, Ayhan Ç, et al. Reliability and validity of the Turkish version of the Disabilities of the Arm, Shoulder and Hand (DASH) Questionnaire. [Article in Turkish] *Fizyoterapi ve Rehabilitasyon* 2006;17:99-107.
15. Nathan PA, Meadows KD, Keniston RC. Rehabilitation of carpal tunnel surgery patients using a short surgical incision and an early program of physical therapy. *J Hand Surg Am* 1993;18:1044-50.
16. Steyers CM. Recurrent carpal tunnel syndrome. *Hand Clin* 2002;18:339-45.
17. Wu HT, Schweitzer ME, Culp RW. Potential MR signs of recurrent carpal tunnel syndrome: initial experience. *J Comput Assist Tomogr* 2004;28:860-4.
18. Botte MJ, von Schroeder HP, Abrams RA, Gellman H. Recurrent carpal tunnel syndrome. *Hand Clin* 1996;12:731-43.
19. Shurr DG, Blair WF, Bassett G. Electromyographic changes after carpal tunnel release. *J Hand Surg Am* 1986;11:876-80.

20. Van de Kar HJ, Jaquet JB, Meulstee J, Molenaar CB, Schimsheimer RJ, Hovius SE. Clinical value of electrodiagnostic testing following repair of peripheral nerve lesions: a prospective study. *J Hand Surg Br* 2002;27:345-9.
21. Sernik RA, Abicalaf CA, Pimentel BF, Braga-Baiak A, Braga L, Cerri GG. Ultrasound features of carpal tunnel syndrome: a prospective case-control study. *Skeletal Radiol* 2008;37:49-53.
22. Aydin K, Cokluk C, Piskin A, Kocabiçak E. Ultrasonographically checking the sectioning of the transverse carpal ligament during carpal tunnel surgery with limited uni skin incisions. *Turk Neurosurg* 2007;17:219-23.
23. Philippe L. Carpal tunnel release under high-frequency ultrasonography. A-0060. FESSH XV Congress Abstracts. *J Hand Surg Eur Vol* 2010;35E(Supplement 1):A-0060. [Abstract]